

FOLIA MEDICA CRACOVIENSIA

Vol. LVI, 3, 2016: 21–29

PL ISSN 0015-5616

# New telemedicine techniques in dermatology — evaluation with reflectance confocal microscopy via cloud-based platform

JOANNA ŁUDZIK<sup>1,2</sup>, ALEXANDER MICHAEL WITKOWSKI<sup>2</sup>,  
IRENA ROTERMAN-KONIECZNA<sup>1</sup>

<sup>1</sup>Department of Biostatistics and Telemedicine, Jagiellonian University Medical College  
ul. św. Łazarza 16, 31-530 Kraków, Poland

<sup>2</sup>Department of Dermatology, University of Modena and Reggio Emilia Modena, Italy  
via del Pozzo 71, 41100 Modena, Italy

**Corresponding author:** Joanna Łudzik MD, Department of Biostatistics and Telemedicine  
Jagiellonian University Medical College  
ul. św. Łazarza 16, 31-530 Kraków, Poland  
E-mail: joanne.ludzik@gmail.com

**Abstract:** Dermoscopically equivocal skin lesions may present a diagnostic challenge in daily clinical practice and are regularly sent for second expert opinion. We present a new approach to handling these cases in a consultation referral system that enables communication between the initial doctor at the image upload site and dermatology experts at a distance via cloud-based telemedicine. In our study we retrospectively evaluated 100 equivocal cases with complete digital dermoscopy-reflectance confocal microscopy image sets and compared suggested management of the initial doctor to a second expert confocal reader. We evaluated the effect of reader concordance on final management of these lesions resulting in a single reader overall sensitivity of 89% and specificity of 66% and double reader concordance method sensitivity of 98% and specificity of 54%. In conclusion, we found that application of double reader evaluation of these image sets with automatic referral of lesions for removal in the case of discordant diagnosis between two doctors improved the sensitivity of diagnosis in this subset of lesions and may increase the safety threshold of management choice reducing potential misdiagnosis in telemedicine settings. This paper concerns the application of telemedicine in practical medicine.

**Key words:** cloud platform, healthcare, teleconfocal, telemedicine, confocal microscopy, skin cancer, melanoma.

## Introduction

Skin cancer is the most common human malignancy with a steady rise in annual incidence. Dermoscopy is used as a first-line screening tool to evaluate skin lesions in differential diagnosis with skin cancer [1–3]. In the case of equivocal lesions the traditional method of cellular assessment is invasive biopsy of the lesion and histopathologic evaluation, treated as the gold standard [4]. Recently, several advanced non-invasive tools have appeared in the skin cancer screening armory with reflectance confocal microscopy (RCM) being the only one with clinical application to both melanocytic and non-melanocytic lesions [5–8]. RCM produces an *in-vivo* optical biopsy at histologic resolution down to a depth of 200  $\mu\text{m}$  of skin tissue by creating mosaic-maps at the pertinent levels of the skin: epidermis, dermal-epidermal junction and dermis enabling bedside cellular view and therefore more visual information to improve early diagnosis [9]. Moreover, RCM has an added value of helping to reduce the number of unnecessary excisions in different settings by up to 80% [10–15]. With growing interest in RCM and limitation of available experts in the field the requirement for communication between novice doctors recently acquiring RCM systems and expert confocal readers at a distance is growing. Thanks to telemedicine technique application to all medical disciplines and in particular dermatology, the digitization of dermoscopy images of skin lesions permits their analysis by store-and-forward telemedicine platforms by combining medicine with computer science.

The principle of telemedicine applied to skin cancer and RCM is the use of telecommunication technology to send complete digital dermoscopy-RCM image sets of equivocal skin lesions over long-distance for the purpose of administration, research, disease prevention, patient management and education. Tele-confocal can provide access to particular dermatological specialist knowledge that would be otherwise unavailable at the imaging location by transferring the information via store-and-forward (SAF) technique. SAF teledermatology allows the initial referring doctor or third party such as a nurse or technical assistant to acquire digital still images with accompanying patient data [16–22]. In the case of tele-confocal the collection of data includes patient information and a full set of images including: digital dermoscopy, three to four mosaic maps at the epidermis, dermal-epidermal junction (DEJ) and dermis as well as a minimum of four vertical sequential imaging stacks (Vivastack<sup>®</sup>; MAVIG GmbH, Munich, Germany), two in the center and two at the periphery of the lesion. This data is then sent to a cloud server to be assessed by the reader, or reviewer, at a later time. As storage, retrieval and privacy of information is crucial the available confocal server needs to be DICOM compliant (Digital Imaging and Communications in Medicine), preventing intrusion and ensuring consistency in the presentation and sharing of information between doctors [23–24].

Previously virtual private network (VPN) was used which allowed a secure two-way interface between information being accessed and the user serving as a safety gate through which select information was used as a primitive connection between only the upload site and fixed download site. The limitation of this system relied on the large data size transfer (up to 1 Gb) and high upfront expense of utilizing a dedicated hardware desktop system to perform off-site telemedicine reads in a fixed restricted location [25].

Recently, thanks to cloud-based server programs it is possible to upload the full set of images from the microscope to a distant cloud server through high speed internet connection (100 mbps recommended). Once the patient imaging data is located on the cloud confocal reading experts can access the data via any computer, tablet or mobile phone that is connected to high speed internet cable or WIFI [26–27]. Thanks to incorporation of similar software used in services such as Google Maps the large imaging files can be streamed in real-time permitting fast scanning of images. Tele-confocal evaluation is best made on a high resolution computer monitor but in instances where a desktop is not available similar effectiveness can be completed with a high resolution laptop or large tablet. The cloud-based system user interface is accessed securely through a website URL where the user is asked to input their dedicated username and password. Once the user accesses the home screen there is a patient list that shows completed and uncompleted evaluations. After a patient case is selected the user has access to the full imaging set via thumbnails (digital dermoscopy and RCM images) that can be clicked and expanded for more in-depth evaluation. Finally, after completely viewing each image the user is prompted to perform an evaluation and treatment recommendation. The final report is then stored on the cloud server and accessible by the upload site.

Our goal in this study was to determine potential improvement of diagnostic accuracy and chosen management of dermoscopically equivocal lesions in a consultation setting by utilizing cloud-based tele-confocal connecting the initial doctor at the imaging location to a second expert confocal reader at a distance. We then applied double reader concordance evaluation to evaluate its potential effect on equivocal cutaneous lesion management in a telemedicine setting.

## **Materials and methods**

This was an observational retrospective analysis based on 100 dermoscopically equivocal skin lesions that were evaluated with dermoscopy and RCM imaging for diagnostic decision in order to rule out the diagnosis of melanoma during the period of January to May 2015 at the Dermatology Department at the University of Modena and Reggio Emilia (UNIMORE). All research was approved by Jagiellonian University Collegium Medicum IRB: Komisja Bioetyczna Uniwersytetu Jagiellońskiego;

nr. 122.6120.204.2015) and was conducted according to the principles expressed in the Declaration of Helsinki. All lesions were evaluated and imaged with digital dermoscopy and RCM, followed by excision for histopathological analysis. The inclusion criteria for lesions in this study were: (i) equivocal dermoscopic lesions at initial presentation; (ii) lesions excised with matching histopathology report; (iv) availability of digital dermoscopy images; (v) availability of a complete standard set of RCM images.

We tested the accuracy of a novice confocal reader (Reader 1) who evaluated digital dermoscopy-RCM image sets at the imaging site and an expert confocal reader (Reader 2) who evaluated the same image sets via the cloud-based telemedicine server, both readers were blind to histopathology diagnosis. Department patient code and private information (name, age, sex, and history) was not provided to the readers and the image sets were placed into separate computer folders and numbered (01 to 100) differently than the department patient code to ensure that the evaluations were made in blind.

### Imaging Protocol and Evaluation

Digital dermoscopy images were obtained with DermLite FOTO System (DermLite Photo 3Gen-San Juan Capistrano, CA, USA). RCM images were obtained with a reflectance confocal microscope (Vivascope<sup>®</sup> 1500; MAVIG GmbH, Munich, Germany) using a 830 nm laser at a maximum power of 20 mW. RCM images of 0.5 mm × 0.5 mm were acquired with a lateral resolution of 1 μm and an axial resolution of 3–5 μm and stitched into composite images that covered between 4 to 8 square mm mosaics (VivaCube<sup>®</sup>; MAVIG GmbH, Munich, Germany). A minimum of three mosaics were obtained at different depths, corresponding to the stratum granulosum/spinosum, the dermal-epidermal junction and the papillary dermis. The cases in this study included the following malignancies: melanomas (MMs) basal cell carcinomas (BCCs), squamous cell carcinomas (SCCs) and benign lesions (including naevi, solar lentigos (SLs), seborrheic keratosis (SKs)), or other benign lesions.

Reader 1 evaluated images on-site and Reader 2 via DICOM compliant secure cloud based server where access to data was only possible with individual login and password. Each confocal reader was asked to provide their management decision and suspected diagnosis based only on the provided image sets into a dedicated Microsoft excel file. Management was grouped into two categories: (i) excision or (ii) no-excision. Management decision confidence level was graded: (i) low or (ii) high. In order to test concordance of double reading, data from the excel files (Reader 1 and Reader 2) were matched and chosen for automatic management with excision when (a) management decision was concordant for excision or (b) management decision was discordant amongst the two readers (Fig. 1).

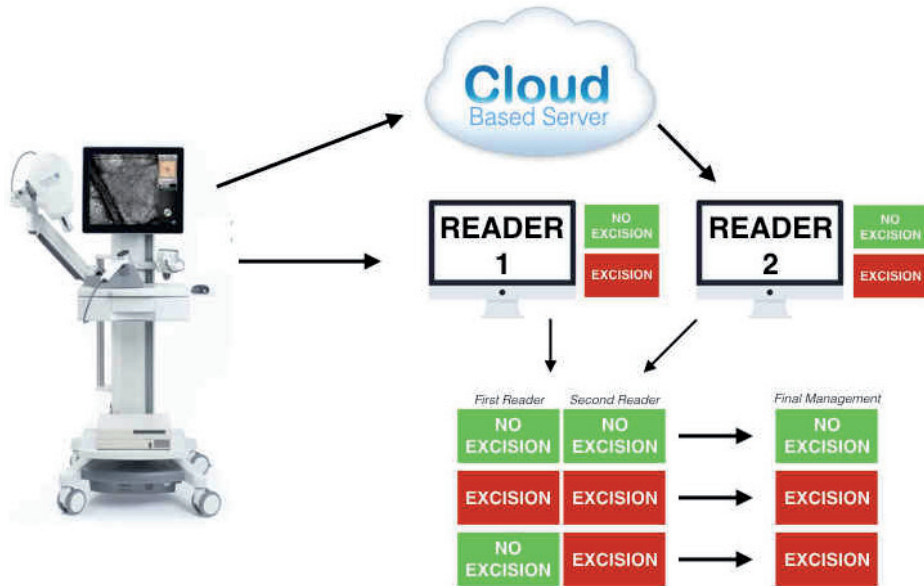


Fig. 1. Diagram of the reading protocol.

### Statistical Analysis

Statistical evaluation was carried out with SPSS statistical package (IBM, Armonk, NY, U.S.A.). Diagnostic values of sensitivity and specificity of individual readers were calculated for malignant versus benign lesions. Absolute and relative frequencies of confidence in benign and malignant lesion management were calculated.  $\chi^2$  test was used to compare confidence level of management with actual histopathologic diagnosis. Cohen's kappa coefficient was calculated in order to find association between double reader management and histologic diagnosis, a P-value <0.05 was considered significant.

### Results

The study population consisted of 100 histopathology proven cases including MM (13 cases), BCC (36 cases), (SCC (3 cases). The remaining 48 cases included naevi (31 total cases; of which 3 were spitz naevi), SK/SL/LPLK/AK (12 cases), and other benign lesions including dermatofibromas, angiokeratomas and angiomas classified as other (5 cases). The evaluations were performed by Reader 1 and Reader 2 for a total of 200 digital dermoscopy-RCM image set evaluations. Reader 1 evaluations resulted in an overall sensitivity of 82.7% and specificity of 58.3% and Reader 2 sensitivity of 96.2% and specificity of 72.9%.

Sensitivity of MM diagnosis was 84.6% for Reader 1 and 100% for Reader 2 respectively, with 2 out of 13 MMs (15.4%) mismanaged by Reader 1. Sensitivity of BCC diagnosis was 83.3% for Reader 1 and 94.4 for Reader 2 and sensitivity of SCC diagnosis was 66.7% for Reader 1 and 100% for Reader 2. Specificity of naevi diagnosis was 60.7% for Reader 1 and 78.6% for Reader 2, with both reporting a specificity of 0% for spitz naevi. Specificity for SK/SL/LPLK/AK cases was 66.7% for Reader 1 and 75.0% for Reader 2.

Digital dermoscopy-RCM double reader concordance evaluation utilizing the method of computer automated referral of lesions for removal when two readers had discordant management decisions resulted in an overall sensitivity improvement to 98.1% and specificity of 56.3%; lesions with concordant management decisions for no excision were considered benign and those with concordant management decisions for excision were considered malignant. Combined MM diagnostic sensitivity for both readers was 100%, with no mismanagement of MM. Overall diagnostic sensitivity for BCC was 97.2% and 100% for SCC. Overall specificity of naevi diagnosis was 53.6%, 0% for Spitz naevi, 58.3% for SK/SL/LPLK/AK, and 100% for all other benign lesions (Tables 1 and 2).

**Table 1.** Overall diagnostic performance of individual readers.

	RCM Reader 1	RCM Reader 2	Combined RCM (Reader 1 and 2)
Overall Sensitivity	82.7%	96.2%	98.1%
Overall Specificity	58.3%	72.9%	56.3%
MM Sensitivity	84.6%	100.0%	100.0%
BCC Sensitivity	83.3%	94.4%	97.2%
Benign Nevi (no Spitz) Specificity	60.7%	78.6%	53.5%

MM — malignant melanoma, BCC — basal cell carcinoma, RCM — reflectance confocal microscopy.

**Table 2.** Double reader management.

Management	MM	BCC	SCC	Naevi	Spitz	SK/SL/LPLK/AK	Other	Total
NO-Excision	0	1	0	15	0	7	5	28
Excision	13	35	3	13	3	5	0	72
Total	13	36	3	28	3	12	5	100

MM — malignant melanoma, BCC — basal cell carcinoma, SCC — squamous cell carcinoma, SK — seborrheic keratosis, SL — solar lentigo, LPLK — lichen planus-like keratosis, AK — actinic keratosis, DF — dermatofibroma.

## Discussion

The purpose of our study was to determine the management safety of equivocal skin lesions referred for telemedicine second expert opinion based on digital dermoscopy-RCM image sets. Since equivocal lesions present fewer discernable features than their counterparts these lesions are more often referred to colleagues for second opinion or excised at once due to uncertainty. Our goal in this study was to test a variety of methods of store-and-forward retrospective evaluation of patient cases and if the addition of a second blind expert confocal reader has the capability to produce safer management results of equivocal lesions, particularly in telemedicine settings where the balance between patient safety and healthcare expenditures should be considered.

Our results delineate the limitation of single novice reader image evaluation from the image acquisition site in the case of equivocal cutaneous lesions where the diagnostic sensitivity may be insufficient to keep the percentage of missed melanomas at a safe level due to the absence of typical criteria in this group of lesions and lower diagnostic confidence level of novice confocal readers.

RCM has been shown to improve diagnostic accuracy of equivocal lesions in various settings thanks to the refractive index of melanocytic structures that produce visible reflection in RCM images [14, 15]. A recent study showed that sensitivity is higher for experienced RCM users versus those who are new to the field (91.0% vs. 84.8%), but that specificity is quite similar (80.0% vs. 77.9%) [13]. RCM permits visualization of morphologic features providing more cellular information for the reader and therefore the potential to improve both diagnostic accuracy and confidence in this group of equivocal lesions.

In our study usage of the cloud-based telemedicine server enabled quick and safe communication between the novice confocal reader and the expert confocal reader at a distance. Moreover, double confocal reader concordance evaluation enhanced the overall diagnostic sensitivity (98.1%) and minimized the likelihood to mismanage an invasive melanoma that was otherwise mismanaged by a single novice confocal reader. Twenty percent of cases (20 of 100) were selected for removal due to reader discordance (one reader suggesting excision and the other excision) resulting in improvement of sensitivity resulting by the addition of a second expert evaluator.

In conclusion, we showed that the application of a newly available cloud-based telemedicine second expert check system in telemedicine settings with an automatic management decision to excise any lesions with discordant management between two readers considerably improved the sensitivity threshold of diagnosis and safety for the patient. Additionally, the use of RCM that permits near histologic non-invasive biopsy enabled the maintenance of an acceptable specificity of lesion diagnosis. With the broadened popularity of RCM and its diffusion into clinical practice the use of telemedicine evaluation will inevitably increase in order to connect patients with experts

around the globe particularly in equivocal case presentations. The addition of a second exper reader and usage of concordance evaluation in this group of lesions may be considered as a safety net for continued spread of the technology and safe management skin lesions in differential diagnosis with skin cancer. The utilization of telemedicine techniques in the diagnosis of dermatological diseases may encounter barriers in regards to ethical and medical procedures as well as legal issues concerning evaluation of patients “at a distance.” These barriers do not completely limit implementation of telemedicine but on the contraire the proper implementation will result in improved patient care. This paper has been written to demonstrate the efficacy of telemedicine technology in the field of non-invasive skin cancer screening and evaluation.

### Conflict of interest

None declared.

### References

1. Woltsche N., Schwab C., Deinlein T., Hofmann-Wellenhof R., Zalaudek I.: Dermoscopy in the era of dermato-oncology: from bed to bench side and retour. *Expert Rev Anticancer Ther.* 2016 May; 16 (5): 531–541.
2. Chappuis P., Duru G., Marchal O., Girier P., Dalle S., Thomas L.: Dermoscopy, a useful tool for general practitioners in melanoma screening: a nationwide survey. *Br J Dermatol.* 2016 Feb 23. doi: 10.1111/bjd.14495.
3. Argenziano G., Cerroni L., Zalaudek I., et al.: Accuracy in melanoma detection: a 10-year multicenter survey. *J Am Acad Dermatol.* 2012 Jul; 67 (1): 54–59.
4. Oude Ophuis C.M., Verhoef C., Rutkowski P., et al.: The interval between primary melanoma excision and sentinel node biopsy is not associated with survival in sentinel node positive patients — An EORTC Melanoma Group study. *Eur J Surg Oncol.* 2016 May 27. pii: S0748-7983(16)30163-9. doi: 10.1016/j.ejso.2016.05.012.
5. Zhao J., Lui H., Kalia S., Zeng H.: Real-time Raman spectroscopy for automatic in vivo skin cancer detection: an independent validation. *Anal Bioanal Chem.* 2015 Nov; 407 (27): 8373–8379. doi: 10.1007/s00216-015-8914-9.
6. Wells R., Gutkowitz-Krusin D., Veledar E., Toledano A., Chen S.C.: Comparison of diagnostic and management sensitivity to melanoma between dermatologists and MelaFind: a pilot study. *Arch Dermatol.* 2012 Sep; 148 (9): 1083–1084.
7. Ulrich M., Themstrup L., de Carvalho N., et al.: Dynamic Optical Coherence Tomography in Dermatology. *Dermatology.* 2016; 232 (3): 298–311.
8. Menge T.D., Pellacani G.: Advances in noninvasive imaging of melanoma. *Semin Cutan Med Surg.* 2016 Mar; 35 (1): 18–24.
9. Rajadhyaksha M., Grossman M., Esterowitz D., Webb R.H., Anderson R.R.: In vivo confocal scanning laser microscopy of human skin: melanin provides strong contrast. *J Invest Dermatol.* 1995 Jun; 104 (6): 946–952.
10. Pellacani G., Cesinaro A.M., Seidenari S.: Reflectance-mode confocal microscopy of pigmented skin lesions—improvement in melanoma diagnostic specificity. *J Am Acad Dermatol.* 2005 Dec; 53 (6): 979–985.



11. Witkowski A.M., Łudzik J., DeCarvalho N., et al.: Non-invasive diagnosis of pink basal cell carcinoma: how much can we rely on dermoscopy and reflectance confocal microscopy? *Skin Res Technol.* 2015 Sep 4. doi: 10.1111/srt.12254.
12. Pellacani G., Pepe P., Casari A., Longo C.: Reflectance confocal microscopy as a second-level examination in skin oncology improves diagnostic accuracy and saves unnecessary excisions: a longitudinal prospective study. *Br J Dermatol.* 2014 Nov; 171 (5): 1044–1051.
13. Pellacani G., Witkowski A., Cesinaro A.M., et al.: Cost-benefit of reflectance confocal microscopy in the diagnostic performance of melanoma. *J Eur Acad Dermatol Venereol.* 2016 Mar; 30 (3): 413–419.
14. Guiter P., Pellacani G., Crotty K.A., et al.: The impact of in vivo reflectance confocal microscopy on the diagnostic accuracy of lentigo maligna and equivocal pigmented and non-pigmented macules of the face. *J Invest Dermatol.* 2010; 130: 2080–2091.
15. Farnetani F., Scope A., Braun R.P., et al.: Skin Cancer Diagnosis With Reflectance Confocal Microscopy: Reproducibility of Feature Recognition and Accuracy of Diagnosis. *JAMA Dermatol.* 2015 Oct; 151 (10): 1075–1080.
16. Arzberger E., Curiel-Lewandrowski C., Blum A., et al.: Teledermoscopy in High-risk Melanoma Patients: A Comparative Study of Face-to-face and Teledermatology Visits. *Acta Derm Venereol.* 2016 Aug 23; 96 (6): 779–783. doi: 10.2340/00015555-2344.
17. Coates S.J., Kvedar J., Granstein R.D.: Teledermatology: from historical perspective to emerging techniques of the modern era: part II: Emerging technologies in teledermatology, limitations and future directions. *J Am Acad Dermatol.* 2015 Apr; 72 (4): 577–586.
18. Ferrara G., Argenziano G., Cerroni L., et al.: A pilot study of a combined dermoscopic-pathological approach to the teliagnosis of melanocytic skin neoplasms. *J Telemed Telecare.* 2004; 10 (1): 34–38.
19. Piccolo D., Smolle J., Argenziano G., et al.: Teledermoscopy--results of a multicentre study on 43 pigmented skin lesions. *J Telemed Telecare.* 2000; 6 (3): 132–137.
20. Fabbrocini G., Balato A., Rescigno O., et al.: Teliagnosis and face-to-face diagnosis reliability for melanocytic and non-melanocytic 'pink' lesions. *J Eur Acad Dermatol Venereol.* 2008 Feb; 22 (2): 229–234.
21. Bashshur R.L., Shannon G.W., Tejasvi T., Kvedar J.C., Gates M.: The Empirical Foundations of Teledermatology: A Review of the Research Evidence. *Telemed J E Health.* 2015 Dec; 21 (12): 953–979.
22. Landow S.M., Mateus A., Korgavkar K., Nightingale D., Weinstock M.A.: Teledermatology: key factors associated with reducing face-to-face dermatology visits. *J Am Acad Dermatol.* 2014 Sep; 71 (3): 570–576.
23. Quigley E.A., Tokay B.A., Jewell S.T., Marchetti M.A., Halpern A.C.: Technology and Technique Standards for Camera-Acquired Digital Dermatologic Images: A Systematic Review. *JAMA Dermatol.* 2015 Aug; 151 (8): 883–890.
24. Singh R., Chubb L., Pantanowitz L., Parwani A.: Standardization in digital pathology: Supplement 145 of the DICOM standards. *J Pathol Inform.* 2011; 2: 23. doi: 10.4103/2153-3539.80719. Epub 2011 May 11.
25. Wang X.J., Hu J., Wang K., et al.: Setting-up and preliminary performance of the interactive teleradiological conference system based on virtual private network. *Chin Med J (Engl).* 2004 Nov; 117 (11): 1735–1738.
26. Melício Monteiro E.J., Costa C., Oliveira J.L.: A Cloud Architecture for Teleradiology-as-a-Service. *Methods Inf Med.* 2016 May 17; 55 (3): 203–214.
27. Liu W.L., Zhang K., Locatis C., Ackerman M.: Cloud and traditional videoconferencing technology for telemedicine and distance learning. *Telemed J E Health.* 2015 May; 21 (5): 422–426. doi: 10.1089/tmj.2014.0121.