

FOLIA MEDICA CRACOVIENSIA

Vol. LVII, 4, 2017: 83–96

PL ISSN 0015-5616

## The quantitative evaluation of the immunohistochemical expression of the pituitary adenomas

BORYS M. KWINTA<sup>1</sup>, EWELINA GRZYWNA<sup>1</sup>, ROGER M. KRZYŻEWSKI<sup>1</sup>, DARIUSZ ADAMEK<sup>2</sup><sup>1</sup>Department of Neurosurgery and Neurotraumatology, Jagiellonian University Medical College, Kraków, Poland<sup>2</sup>Department of Neuropathology, Jagiellonian University Medical College, Kraków, Poland**Corresponding author:** Borys M. Kwinta, MD, PhD

Department of Neurosurgery and Neurotraumatology, Jagiellonian University Medical College

ul. Botaniczna 3, 31-503 Kraków, Poland

Phone: +48 12 424 86 62; Fax: +48 12 424 86 90; E-mail: bmkwinta@gmail.com

**Abstract:** **Background:** The aim of this study was to evaluate morphometrically the pituitary adenomas immunoexpression.

**Methods:** The cases of 72 patients were analyzed, who underwent transsphenoidal surgery for pituitary adenomas. Subsequently, the immunohistochemical pituitary hormone panel was applied including alpha-subunit of the glycoprotein hormones. Immunohistochemical sections were analyzed quantitatively with the help of morphometric grid. The percentage rate of the immunoexpression was calculated separately for every single hormone.

**Results:** As a result, 22 monohormonal adenomas (30.56%), 21 plurihormonal adenomas (29.17%), 21 immunonegative adenomas (29.17%) and 8 unreliable cases (11.11%) were recognized. The immunopositivity for particular hormones was found as follows: PRL and GH (25% each),  $\alpha$ -SU (22.22%), ACTH (13.89%), LH and FSH (12.5% each), and TSH (5.56%). An average percentage of immunoexpression in each positive staining groups occurred as follows: for PRL — 59.98%, for GH — 53.97%, for ACTH — 39.21%, for TSH — 25.05%, for LH — 37.3%, for FSH — 54.66%, for  $\alpha$ -SU — 45.71.

**Conclusion:** The morphometrical method utilizing the immunoexpression index introduced in this study provided a very precise recognition of pituitary adenomas pathology. This method may limit the subjectivity of a single researcher and enable better comparison of the studies. The plurihormonality is a common phenomenon, and immunohistochemical staining for all adenohypophyseal hormones is obligatory in order to classify pituitary adenomas correctly. The awareness of an operating neurosurgeon of the importance of meticulous collecting histopathological material, especially in microadenoma cases, has essential impact on further neuropathological evaluation and possibility of immunohistochemical staining.

**Key words:** morphometrical method, immunohistochemical techniques, adenohypophyseal hormones.

## Introduction

Basic neuropathological evaluation of pituitary adenomas involves the assessment of hematoxylin and eosin (H&E) stained preparations. Historically pituitary adenomas were classed as either chromophobic and acido- or basophilic due to its affinity for stains hematoxylin and eosin, as in the case of normal pituitary cells [1]. The immunohistochemical studies have completed the neuropathological diagnostics of pituitary adenomas [2–4]. The reliable marker of the presence of pituitary adenoma is at least focally positive staining for the trophic hormones [5]. The immunohistochemical techniques based on the use of antibodies against the pituitary hormones: PRL, GH, ACTH, TSH, FSH, LH,  $\alpha$ -SU [5–8] are now widely applied. However there is a paucity of knowledge on the methods of immunohistochemical results assessment and its clinical utility [9]. Most often, in practice, descriptive approach is applied, based on the interpretation of examining neuropathologist. Therefore this method is highly subjective, dependent on the experience of the investigator. Some authors introduce the rating scales grading the strength of immunohistochemical staining, for example: 0, 1+, 2+, 3+, etc. [10–12]. Both, qualitative and semiquantitative assessment, does not show the strength of the adenoma's hormonal expression. Further the preparations with weak or dispersed expression result in the additional major problem [13]. The recognition of such reactions as positive seems controversial. Some authors define additionally the minimum expression at which the reaction is considered to be positive [4, 7, 12, 14, 15]. Hence the proper selection of method to morphometric evaluation of immunohistochemical scans remains essential.

In this study we present quantitative evaluation of the expression of pituitary adenomas hormones.

## Material and Methods

Patients treated in the Department of Neurosurgery and Neurotraumatology of Jagiellonian University Medical College in Krakow between 2007 and 2016 and diagnosed in the Department of Neuropathology were enrolled into the study. Final study group consisted of 44 women and 28 men aged between 10 and 84 years (mean age 47 years) with complete clinical, histopathological and radiological medical records. This study was conducted in accordance with the ethical standards laid down in the Declaration of Helsinki (1964) and its design was approved by the local University Ethical Committee (protocol number KBET/157/B/2012).

Medical history, neurological examination findings and trophic hormones serum levels led to the diagnosis of endocrine impairments (Fig. 1).

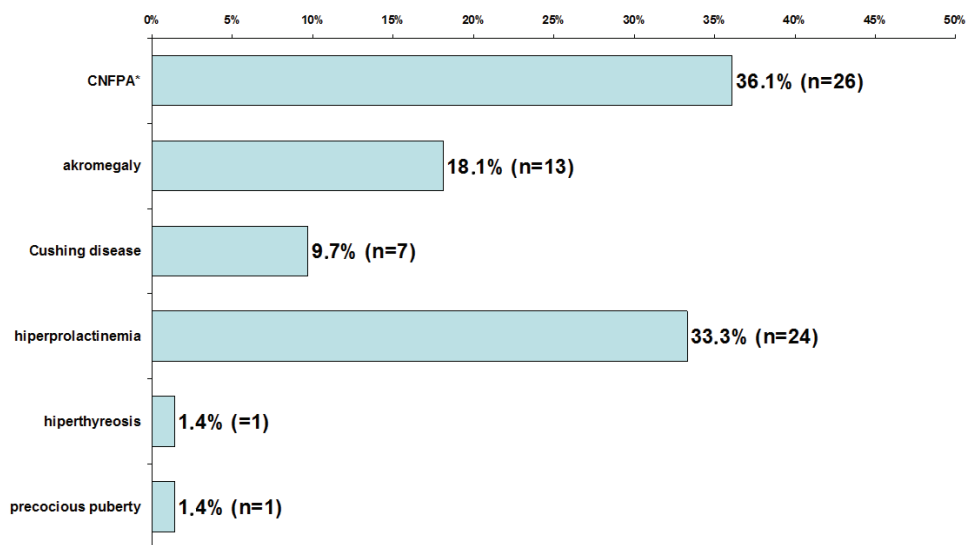


Fig. 1. Endocrinological diagnoses.

\* CNFPAs — Clinically non-functioning pituitary adenomas.

According to MRI data: macroadenomas were diagnosed in 51 (70.84%) cases, while microadenomas were found in 21 (29.16%) cases.

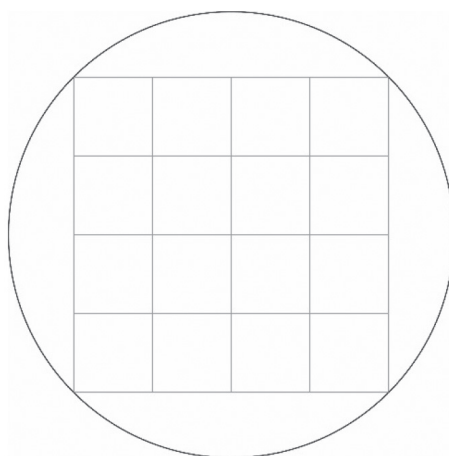
All patients were operated on microsurgically using a transsphenoidal approach.

The entire panel of immunohistochemical tests for adenohypophyseal hormones (PRL, GH, ACTH, TSH, LH, FSH,  $\alpha$ -SU) was conducted in all patients. The proper execution of staining was confirmed by performing control staining on preparations of the pituitary gland of the section material. Table 1 summarizes the characteristics of each hormone staining.

The diagnosable tissue areas on the H&E preparations were calculated. All sections were examined using light microscope Nikon Optishot-2 under magnification of 200 $\times$  and 400 $\times$ . Nondiagnostic areas, meaning those where there was no adenoma tissue and the presence of regular pituitary tissue, fibrosis, hemorrhagic stroke, etc. were identified, were excluded from the analysis. The morphometric evaluation was undertaken if at least one field of view under 200 $\times$  magnification included adenoma tissue without evidence of electrothermal or mechanical damage and no massive necrotic lesions and/or bleeding was detected in this area. If the preparation wasn't suitable for the assessment the next section was cut and the staining was repeated. To assess the expression of the hormones the cell index was used. Under the light microscope 400 $\times$  magnification the percentage of cells presenting the positive immunohistochemical reaction was calculated. Morphometric analysis was performed

**Table 1.** Immunohistochemical staining.

Antibody	Manufacturer	Dilution	Incubation	Reaction visualization	Comments
anti-PRL	Dako, Denmark	ready to use	15 min., room temp.	EnVISION TM + System Labelled Polymer HRP- ant rabbit	-
anti-GH	Dako, Denmark	ready to use	15 min., room temp.	EnVISION TM+ System Labelled Polymer HRP- ant rabbit	-
anti- ACTH	Dako, Denmark	ready to use	15 min., room temp.	EnVISION TM+ System Labelled Polymer HRP- ant rabbit	-
anti-TSH	Novocastra, UK	01:25	24 hours, 4°C	ABC KIT Vectastain Universal	unmasking antigen by 2 × 5 min. in buffer pH = 6.0
anti-LH anti-FSH	Dako, Denmark	01:25	30 min., room temp.	EnVISION TM+ System Labelled Polymer HRP- ant mouse	unmasking antigen by 2 × 5 min. in buffer pH = 6.0
anti- $\alpha$ -SU	Novocastra, UK	0.100	24 hours, 4°C	ABC KIT Vectastain Universal	unmasking antigen by 2 × 5min. in buffer pH = 6.0

**Fig. 2.** Morphometric grid.

manually using morphometric adapter to an optical microscope and morphometric grid (Fig. 2). Morphometric grid used in the study consisted of 16 fields of equal area (covering the entire field of view in the microscope under 400× magnification). Staining cells and all cells number were counted in every field. The analyses was performed systematically in 5 reliable (free from artifacts) parts of preparation. This way the precise quantitative immunohistochemical analysis of pituitary adenomas were carried out.

A small number of dispersed positive cells situated on the perimeter of adenoma presenting a positive IHCH reaction was not counted because it was considered as impurity of “trapped” normal cells adenohypophysis.

All calculations and statistical analyzes were performed using the statistical package STATISTICA 9 PL licensed for the Jagiellonian University.

## Results

In the study group of 72 patients 43 had positive immunohistochemical reactions. 22 monohormonal adenomas (30.56%), 21 plurihormonal adenomas (29.17%), 21 immunonegative adenomas (29.17%) were diagnosed. In 8 cases (11.11%) investigators haven't been able to interpret immunohistochemical reactions, these results were considered unreliable. The interpretative difficulties was caused mainly by presence of hemorrhage, necrosis, thermal artifacts, adeno- or neurohypophysis.

The smallest field of the tissue in the preparation was 0.55 mm<sup>2</sup> and the biggest — 156.15 mm<sup>2</sup>; the average field analyzed was 41.79 mm<sup>2</sup> (standard deviation of 37.79). There were no threshold admitted for labeling index. The smallest positive reaction observed was 4.3% for TSH in plurihormonal adenoma.

Positive reaction towards the prolactin and growth hormone were detected in 18 cases (25%), alpha subunit 16 (22.22%), adrenocorticotrophic hormone in 10 (13.89%), LH in 9 (12.5%), FSH in 9 (12.5%) and thyroid-stimulating hormone in 4 cases (5.56%), respectively.

84 out of 504 evaluated immunohistochemical preparations among 72 cases have been found positive for the various hormones presence.

Among these 84 positive immunohistochemical preparations a total of 113 512 cells were counted of which 61 008 were considered as positive. The immunoexpression percentage of all positive reactions was calculated (Table 2 and 3). The average number of all cells in a single field of view under 400× magnification was 14.47, the average number of positive cells per field of view of 400× was 7.8. Therefore, for the entire group the average immunoexpression index reached 53.76.

**Table 2.** The immunoexpression in monohormonal adenomas<sup>1</sup>.

PRL (8) <sup>1</sup>	GH (7)	ACTH (2)	TSH (0)	LH (1)	FSH (1)	α-SU (3)
84.8%	61.0%	45.0%		34.6%	19.1%	14.6%
58.7%	14.7%	41.3%				27.1%
85.1%	73.8%					70.0%
72.7%	74.6%					
59.2%	69.1%					
25.1%	75.1%					
82.3%	85.5%					
86.8%						

<sup>1</sup> in parentheses, the number of cases of specified type of monohormonal adenomas were notified

**Table 3.** The immunoexpression in plurihormonal adenomas.

No	PRL	GH	ACTH	TSH	LH	FSH	α-SU	Total
1			16.9			69.7		86.6
2			55.2			87.4		142.6
3	66.3	88.3						154.6
4	75						11.6	86.6
5		61.9			37		71.2	170.1
6	26.6	80.8						107.4
7		17	8			53	24.1	102.1
8			85.8				9.7	95.5
9	50.3	57.2			46.8		77.9	232.2
10	27	83.1					10.2	120.3
11	47		34.6			47.5	85.7	214.8
12	60.5	70.7	24		28	53.9	77.9	315
13					44.9	52.3	41.1	138.3
14	53.1	58.6	45.5					157.2
15					71.2	34.7	60.2	166.1
16	78	32.5	35.8		43.3	74.3		263.9
17				7.1			87.5	94.6
18				12			17.9	29.9
19	41.1	63.5			15.4	76.8		196.8
20					15.4		44.6	60
21		84.1		4.3				88.4

## Discussion

Immunohistochemical staining in the diagnostics of pituitary adenomas enables their proper classification, verification of the presence of the pituitary adenoma, and in some cases the differential diagnosis of other lesions located in the sella turcica region [16]. In view of the increased aggressiveness of certain adenomas immunophenotypes immunochemical staining is important for the determination of prognosis [2, 17, 18]. In the discussion on the results of immunohistochemical staining arise two major problems of samples validity and evaluation methods of preparation. The morphometric method applied in this study allows for qualitative and quantitative assessment. The accuracy of immunohistochemical testing brings us closer to the knowledge about the true nature of adenoma. In this study, special attention was paid to the methodology. In the first place H&E preparations were evaluated and the reliable regions were selected. In the second place the immunohistochemical results were analyzed excluding normal cells of adenohypophysis. Then, finally, hormone expression was evaluated by counting all positive reacting cells in relation to all cells in the adenoma in five consecutive preparation fragments. Thus, the percentage of immunoexpression was calculated. Comparing results of other authors a special attention was drawn to the manner of immunohistochemical analysis. Literature data suggest that the selected method of immunohistochemical preparations assessment might be crucial. Few studies discuss the methods applied to assess immunohistochemical results and reliability of the biological material, while those available vary considerably. Thus, comparing the results of immunohistochemical studies of pituitary adenomas is not easy due to the very diverse methodology of the research. In routine practice, the result of immunohistochemical testing determines, usually, only whether the reaction is positive or negative [19]. This result is usually accompanied by an optional comment (which may be regarded as a descriptive analysis), what is highly subjective. In the literature, various quantitative [7, 20–22] and semiquantitative [10–12, 23] (in arbitrarily adopted degrees) methods of immunohistochemical evaluation exist trying to objectivize this issue. The question is how to define the various degrees of immunoexpression. In practice, the specific categorizations have depended on the individual preferences of the investigator. Accordingly, the results have differed from each other because they haven't been standardized [24]. Table 4 demonstrates how inconsistent is the presentation of the results by different authors [7, 9–12, 14, 19–21, 23–29]. Moreover, not all researchers included detailed description of method used for immunohistochemical evaluation. The problem is certainly the lack of clear standards [9]. In the literature, there is no definition of what exactly is a positive immunohistochemical reaction [9] and the comparison of results is difficult due to various cut-off points. Discrepancies due to different percentage of positive cells indicating positive reaction may lead to large

**Table 4.** The methods for immunohistochemical evaluation in the literature.

Author	Year	t <sup>1</sup>	Antibodies	Method	Comments
Knosp <i>et al.</i> [25]	1988	nd <sup>2</sup>	polyclonal	qualitative and semiquantitative	0, +, ++, +++, scale depending on the number of positive cells and intensity of staining, one investigator
Herzog <i>et al.</i> [20]	1993	4 µm	polyclonal	percentage of immunoexpression	morphometric grid 100 × 100 µm
Matsuo <i>et al.</i> [24]	1995	3 µm	polyclonal	quantitative – manual counting vs computer analysis	50 fields in preparation, the amount of positive reacting cells in the field, evaluation of staining intensity in pictures analyzer
Gsponder <i>et al.</i> [7]	1999	nd	nd	semiquantitative	weak reaction if 10–50%, strong reaction if >50%
Zhao <i>et al.</i> [26]	2000	nd	polyclonal	quantitative – percentage of immunoexpression	1000 cells were tested in preparation, cut-off point = 5%
Ho <i>et al.</i> [23]	2001	nd	monoclonal	semiquantitative	<5%+, 5–20%+, 20–50%, >50%+
Münscher <i>et al.</i> [12]	2001	nd	nd	semiquantitative	1+, 2+, 3+, the level of reaction reliability >20%
Kojima <i>et al.</i> [11]	2002	4–6 µm	polyclonal	semiquantitative	1–24%+, 25–74%+, >75%
Gołkowski <i>et al.</i> [19]	2003	5 µm	polyclonal	qualitative	+/-
Mahta <i>et al.</i> [7]	2007	nd	polyclonal	quantitative – percentage of immunoexpression	cell counts of three fields with the largest immunoexpression (hot spots), cut-off point >5%
Yamada <i>et al.</i> [21]	2007	nd	polyclonal/monoclonal	quantitative – percentage of immunoexpression	manual counting by technician
Hamid <i>et al.</i> [9]	2009	nd	monoclonal	semiquantitative, with analysis of reaction intensity	1+: <1% strong+ or <10 weak+, 2+: 1–10% strong + or 10–50% weak+, 3+: 10–50% strong + or 50–75% weak+, 4+: 50–75% strong + or >75% weak+, 5+: >75% strong + evaluation of all preparations by one investigator not knowing the clinical data of patients



Table 4. Cont.

Author	Year	t <sup>1</sup>	Antibodies	Method	Comments
Pawlikowski <i>et al.</i> [14]	2010	nd	polyclonal/ monoclonal	nd	the level of reliability of reaction >1%
Balinisteanu <i>et al.</i> [27]	2011	nd	monoclonal	qualitative and quantitative	immunoreactivity to different hormones estimated as positive or negative; the Ki-67 labeled index (LI) was assessed by counting the percentage of number of positive
Oriz-Plata <i>et al.</i> [28]	2012	nd	monoclonal	semiquantitative	0 (negative), 1+ (10–30% of cells), 2+ (30–50% of cells) or 3+ (over 50% of cells).
Cimpean <i>et al.</i> [29]	2015	3 μm	polyclonal/ monoclonal	qualitative	three investigators

<sup>1</sup>t — the thickness of the scrap

<sup>2</sup>nd — no data

differences in the results [16]. In this study, no criteria were applied for the smallest percentage of immunoexpression to recognize the authentically positive reaction. However it was verified if the sparse, diffuse expression hasn't resulted from the presence of trapped normal pituicytes. The smallest value of immunoexpression in this study was 4.3% for the reaction indicating TSH. Some authors provide manual analysis of immunoexpression [21, 25] some relayed on the automatic analysis with use of pictures analyzer [24]. Matsuo *et al.* studied a pituitary adenomas in rats [24]. They compared the concentrations of prolactin and growth hormone in the adenomas tissue with the results of immunohistochemical analysis obtained manually and with use of pictures analyzer. The results indicated a strong correlation between hormone concentration and the immunohistochemical image with much greater strength of relation using computer image analysis. The authors of this study explain this by the greater capability of equipment to assess immunointensity of the image [24]. The accuracy of computer equipment is unquestionable and outperforms human capacity [30]. However, in case of immunohistochemical image analysis, in particular for a surgical material, which for obvious reasons can't be technically perfect, collected and prepared in a strictly reproducible and homogenous manner (as it is the case of the experimental study) caution is essential in terms of the so-called background reaction, which may be considered as the weak positive reaction. In addition, the selection the fragment of the preparation suitable for the analysis can be done only by a person trained in the assessment of immunohistochemical preparations. Pictures analyzer is not able to distinguish trapped *adenohypophysis* cells, is not critical to the

artifacts, and it is not able to narrow the area of analysis to the reliable regions of the preparation [31]. On the other hand, some authors limited the analyzed fragments of the preparation only to the places with the highest expression (hot spots), that leads to the overestimation the result of quantitative evaluation. In this study, we haven't limited the analysis to the fields with the highest expression evaluating the available, reliable material in a systematic way. In the literature it is emphasized the importance of antibodies used in the experiment [16]. The use of monoclonal antibodies, in contrast to polyclonal, leads to lower frequency of positive reactions identification for greater number of hormones and increases the percentage of immunoexpression specific for a particular adenoma type [9, 16]. In this study, the polyclonal antibodies available in the local Laboratory of Neuropathology were used. The choice of a particular type of antibody also depends on the quoted market prices and the quality of the reactions. Matsuo *et al.* also point out the validity of staining of all preparations in the same session under constant conditions [24]. The thickness of the scrap, not considered by all the authors, may also affect the obtained results [30]. Theoretically, the thicker the preparation the more cells may be found in the section [31].

In the study group 59.73% of pituitary adenomas presented positive immunohistochemical reaction for one or more hormones. 29.17% hormonally inactive pituitary adenomas were diagnosed. Presented distribution of adenomas is characteristic for the surgical series, where a large group are patients with advanced neurological symptoms caused by the expansion of hormonally inactive macroadenoma [32]. 11.11% of preparations were of the quality that was too poor for interpretation. They were found to be unreliable at the stage of neuropathological examination, what means at least the H&E preparation that enabled the pituitary adenoma recognition. After adjusting for cases where the material was completely damaged or extremely poor and did not allow for the preparation of a sufficient number of scraps for testing, then the actual number of unreliable cases is even greater. Analyzed literature reports don't present any data on the number of unreliable tests. This surprisingly high percentage of non-representative preparations affects the relationship between immunohistochemical results and clinical picture.

Positive reactions for prolactin and growth hormone were diagnosed the most often, stating in 25% of patients each. Most studies on immunohistochemistry in pituitary adenomas also provide the greatest incidence of these same reactions [1, 5, 33]. The third most frequently observed positive immunohistochemical reaction was for the alpha-subunit (22.22% of patients). The common presence of this reaction can be explained by the fact that pituitary glycoprotein hormones include  $\alpha$ -SU and it may be identified independently of these hormones [34, 35]. The study of Knosp *et al.* positive reactions to the alpha subunit was present in 10% of cases [25], in Maksymowicz study — in 6.49% of cases [36]. Positive reaction for

ACTH were found in 13,89% of cases. Maksymowicz showed a 24.2% incidence of ACTH reaction in the larger study group of 154 patients [36]. Both, LH and FSH, were immunohistochemically detected in 12.5% of cases. These reactions were found among clinically inactive pituitary adenomas and as admixture in some of plurihormonal adenomas. By comparison in Maksymowicz study LH positive reaction was found in the 6.49% of cases and FSH in 5.19%. In the Knosp study among gonadotropins only reaction for LH was determined and its incidence was 1.21% [25]. In our study the least often found reaction was for TSH (5.56%). This corresponds to the least often diagnosed according to WHO data thyrotrophic adenoma [37, 38]. Gołkowski *et al.* in the study on the similar subject conducted immunohistochemical staining but only for the four hormones — PRL, GH, ACTH, TSH [19]. The incidence of expression of particular hormones in the study group is different from the values obtained in this study and was 42.5% for PRL, 35% for GH, 40% for ACTH 40% and 17.5% for TSH [19]. Differences result probably of small numbers of investigated series [25].

Detection of positive reaction does not authorize yet to identify a particular adenoma type. This is related to the possibility of expression of more than one hormone that occurs in case of plurihormonal adenomas. In this study, only one of the hormone overproduction resulted in the clinical manifestation. This is confirmed by studies on plurihormonal adenomas [3, 14, 17 23]. On the other hand, some of hormonally inactive adenomas presented the positive immunoexpression. A similar phenomenon has been reported by the other authors of studies on hormonally inactive adenomas [7, 33, 35, 39].

Morphometric immunohistochemical evaluation with use of the immunoreactivity index enables very precise recognition of the pituitary adenoma pathology, reduces errors due to the subjectivity of investigator assessment and enables the objective comparison of results. This method should become a standard in the histopathological diagnostics of pituitary adenomas.

Plurihormonal adenomas are the common phenomenon among the pituitary adenomas. Immunohistochemical staining for all the pituitary trophic hormones are necessary for appropriate classification of pituitary adenomas.

The special attention of neurosurgeon to secure biological material, especially in case of microadenoma, is crucial and causes significant impact on further neuropathological diagnosis and the ability to perform immunohistochemical staining.

## Acknowledgments and disclosures

Acknowledgments — none.

## Conflict of interest

None declared.

## References

1. *Horvath E., Scheithauer B.W., Kovacs K., Lloyd R.*: Hypothalamus and pituitary. In: D. Graham, P. Lantos. *Greenfield's Neuropathology*. 7<sup>th</sup> edition, London: Edward Arnold, 2000; 983–1062.
2. *Lloyd R.V., Kovacs K., Young Jr. W.F.*: Pituitary tumors: introduction. In: R.A. Delellis, R.V. Lloyd, P.U. Heitz, C. Eng. *World Health Organization Classification of Tumours: Pathology & Genetics — Tumours of Endocrine Organs*. Lyon: IARC Press, 2004; 10–13.
3. *Scheithauer B.W., Horvath E., Kovacs K., et al.*: Plurihormonal pituitary adenomas. *Semin Diagn Pathol*. 1986; 3 (1): 69–82.
4. *Zgliczyński W., Zdunowski P., Jeske W., Podgórski J., Zieliński G.*: Diagnosis and treatment of gonadotropinoma. *Pol J Endocrinol*. 2003; 54 (1): 3–12.
5. *Lopes M.B., Thapar K., Horvath E.*: Neoplasms of the sellar region. In: R. McLendon, M. Rosenblum, D. Bigner. *Russell & Rubinstein's Pathology of Tumors of the Nervous System*. 7th edition. Hodder Arnold, 2006.
6. *Dorn A., Nystrom S., Muller M., Rinne A., Kyllönen A., Bernstein H.G., et al.*: Immunocytochemical characterisation of human pituitary adenomas. *Zentralbl Neurochir*. 1985; 46 (3): 188–194.
7. *Mahta A., Haghpanah V., Lashkari A., Heshmat R., Larijani B., Tavangar S.M.*: Non-functioning pituitary adenoma: immunohistochemical analysis of 85 cases. *Folia Neuropathol*. 2007; 45 (2): 72–77.
8. *Scheithauer B.W., Horvath E., Lloyd R.*: Pathology of pituitary adenomas and pituitary hyperplasia. In: K. Thapar, K. Kovacs, B. Scheithauer. *Diagnosis and management of pituitary tumors*. Totowa: Humana Press, 2001; 91–154.
9. *Hamid Z., Mrak R., Ijaz M., Faas F.*: Sensitivity and specificity of immunohistochemistry in pituitary adenomas. *Endocrinologist*. 2009; 19: 38–43.
10. *Gsponer J., De Tribolet N., Deruaz J.P., Janzer R., Uské A., Mirimanoff R.O., et al.*: Diagnosis, treatment, and outcome of pituitary tumors and other abnormal intrasellar masses. Retrospective analysis of 353 patients. *Medicine*. 1999; 78 (4): 236–269.
11. *Kojima Y., Suzuki S., Yamamura K., Ohhashi G., Yamamoto I.*: Comparison of ACTH secretion in Cushing's adenoma and clinically silent corticotroph adenoma by cell immunoblot assay. *Endocr J*. 2002; 49 (3): 285–292.
12. *Münscher A., Schmid M., Saeger W., Schreiber S, Lüdecke D.K.*: GH-, PRL-, POMC-, beta-TSH-, beta-LH-, beta-FSH-mRNA in gonadotrophic adenomas of the pituitary by in situ hybridization in comparison with immunostaining and clinical data. *Endocr Pathol*. 2001; 12 (2): 171–180.
13. *Farnoud M.R., Kujas M., Derome P., Racadot J., Peillon F, Li J.Y.*: Interactions between normal and tumoral tissues at the boundary of human anterior pituitary adenomas. *Virchows Arch*. 1994; 424: 75–82.
14. *Pawlikowski M., Kunert-Radek J., Radek M.*: Plurihormonality of pituitary adenomas in light of immunohistochemical studies. *Endokrynol Pol*. 2010; 61 (1): 63–66.

15. Sano T, Horiguchi H, Xu B, Li C, Hino A, Sakaki M, et al.: Double pituitary adenomas: six surgical cases. *Pituitary*. 1999; 1: 243–50.
16. Saeger W, Wilczak W, Ludecke D.: Hormone markers in pituitary adenomas: changes within last decade resulting from improved method. *Endocr Pathol*. 2003; 14 (1): 49–54.
17. Horvath E, Lloyd R.V, Kovacs K.: Plurihormonal adenoma. In: R.A. Delellis, R.V. Lloyd, P.U. Heitz, C. Eng. World Health Organization Classification of Tumours: Pathology & Genetics — Tumours of Endocrine Organs. Lyon: IARC Press, 2004; 35.
18. Kontogeorgos G., Watson Jr. R.E., Lindell E.P., et al.: Growth hormone producing adenoma. In: R.A. Delellis, R.V. Lloyd, P.U. Heitz, C. Eng. World Health Organization Classification of Tumours: Pathology & Genetics — Tumours of Endocrine Organs. Lyon: IARC Press, 2004; 14–19.
19. Gołkowski F, Trofimiuk M, Buziak-Breza M, Czepko R, Adamek D, Huszno B.: Pituitary tumors: hormonal status and immunohistochemical evaluation. *Przegl Lek*. 2003; 60 (5): 338–341.
20. Herzog T, Schlotte W, Lorenz R, Jungmann E, Althoff P.H.: Pituitary adenomas: serum hormone levels and immunohistochemical staining for ACTH, GH and prolactin. *Clin Neuropathol*. 1993; 12 (2): 117–120.
21. Yamada S, Ohyama K, Taguchi M, Takeshita A, Morita K, Takano K, et al.: A study of the correlation between morphological findings and biological activities in clinically nonfunctioning pituitary adenomas. *Neurosurgery*. 2007; 61 (3): 580–584 (discussion 584–585).
22. Xu Q, Yuan X, Tunici P, Liu G, Fan X, Xu M, et al.: Isolation of tumour stem-like cells from benign tumours. *Br J Cancer*. 2009; 101: 303–311.
23. Ho D.M., Hsu C.Y., Ting L.T., Chiang H.: Plurihormonal pituitary adenomas: immunostaining of all pituitary hormones is mandatory for correct classification. *Histopathol*. 2001; 39: 310–319.
24. Matsuo T, Mori H, Nishimura Y, Maeda T, Nakagawa J.I., Obashi A.: Quantification of immunohistochemistry using an image analyser: correlation with hormone concentrations in pituitary adenomas. *Histochem J*. 1995; 27: 989–996.
25. Knosp E, Krisch K, Schmidbauer M, Schmidbauer M, Budka H.: Immunologischer Hormonnachweis bei Hypophysenadenomen: Korrelation von Serumhormonbefunden mit immunzytochemischem Hormonbefund am Tumorschnitt. *Wien Klin Wochenschr*. 1988; 100 (10): 322–325.
26. Zhao D, Tomono Y, Tsuboi K, Nose T.: Immunohistochemical and ultrastructural study of clinically nonfunctioning pituitary adenomas. *Neurol Med Chir*. 2000; 40: 453–457.
27. Balinisteanu B., Ceausu R.A., Cimpeani A.M., Baciu I., Băculescu N., Coculescu M., et al.: Conventional examination versus immunohistochemistry in the prediction of hormone profile of pituitary adenomas. An analysis on 142 cases. *Rom J Morphol Embryol*. 2011; 52 (3 Suppl.): 1041–1045.
28. Ortiz-Plata A., Tena-Suck M.L., Perez-Neri I, Rembao-Bojórquez D., Fernández A.: Pituitary Adenomas — Clinico-Pathological, Immunohistochemical and Ultrastructural Study. In: V. Rahimi-Movaghar (ed.). *Pituitary Adenomas*. InTech, 2012 (ISBN: 978-953-51-0041-6).
29. Cimpeani A.M., Melnic E., Balinisteanu B., Corlan A., Coculescu M., Rusu S., et al.: Geographic-Related Differences of Pituitary Adenomas Hormone Profile: Analysis of Two Groups Coming from Southeastern and Eastern Europe. *Int J Endocrinol*. 2015; 192094. doi: 10.1155/2015/192094.
30. Hamilton P.W., Allen D.C.: Morphometry in histopathology. Review article. *J Pathol*. 1995; 175: 369–379.
31. Bieniecki W., Sekulska J.: Segmentacja i analiza obrazów mikroskopowych barwionych immunohistochemicznie. *Automatyka* 2003; 7 (3): 283–293.
32. Saeger W, Ludecke D.K., Buchfelder M., Fahlbusch R, Quabbe H.J., Petersenn S.: Pathohistological classification of pituitary tumors: 10 years of experience with the German Pituitary Tumor Registry. *Eur J Endocrinol*. 2007; 156: 203–216.
33. Kontogeorgos G.: Classification and pathology of pituitary tumors. *Endocrine*. 2005; 28 (1): 27–35.

34. *Ho D.M., Hsu C.Y., Ting L.T., Chiang H.*: The clinicopathological characteristics of gonadotroph cell adenoma: a study of 118 cases. *Hum Pathol.* 1997; 28 (8): 905–911.
35. *Samejima N., Shozo Y., Takada K., Sano T., Ozawa Y., Shimizu T., et al.*: Serum  $\alpha$ -subunit levels in patients with pituitary adenomas. *Clin Endocrinol.* 2001; 54: 479–484.
36. *Maksymowicz M.*: Ocena przydatności mikroskopii elektronowej i immunocytochemii na poziomie ultrastrukturalnym w diagnostyce klasyfikacji gruczolaków przysadki. Praca Doktorska. Akademia Medyczna w Warszawie; Warszawa 2002.
37. *Osamura R.Y., Sano T., Ezzat S.*: TSH producing adenoma. In: R.A. DeLellis, R.V. Lloyd, P.U. Heitz, C. Eng. World Health Organization Classification of Tumours: Pathology & Genetics — Tumours of Endocrine Organs. Lyon: IARC Press, 2004; 24–25.
38. *Teramoto A., Sanno N., Tahara S., Osamura Y.R.*: Pathological study of thyrotropin-secreting pituitary adenoma: plurihormonality and medical treatment. *Acta Neuropathol.* 2004; 108: 147–153.
39. *Sen O., Ertorer M.E., Aydin M.V., Erdogan B., Altinors N., Zorludemir S., et al.*: Silent pituitary macroadenoma co-secreting growth hormone and thyroid stimulating hormone. *J Clin Neurosci.* 2005; 12 (3): 318–320.