

DOI 10.1515/pjvs-2017-0004

Original article

Germocyte lesions caused by porcine circovirus type 2b in Kunming mice

A.W. Yuan¹, P. Pang¹, Q.L. Gong, Z.B. DengCollege of Veterinary Medicine,
Hunan Agricultural University, Changsha, Hunan 410128, China

Abstract

Porcine circovirus type 2 (PCV2) has been known as a causative agent of reproductive failure in the sow. In the present study mouse model was used to investigate PCV2 infection. In order to investigate whether PCV2 can induce lesions of spermatocytes and oocytes, 6 male and 6 female mice were each inoculated intraperitoneally with PCV2b, and 3 male and 3 female mice mock-infected with cell culture supernatant served as controls. Samples of testes and ovaries from PCV2b-inoculated and mock-infected mice were investigated using PCR, histopathological, ultrastructural and immunofluorescent histochemical methods at 14 and 21 day post infection (dpi). The study revealed that in the virus-inoculated mice leydig cells in testes and granulosa cells in ovaries were degenerated, and a small number of spermatocytes and oocytes showed apoptosis. Positive PCV2b antigen signals were also observed in these apoptotic cells. It can be suggested that PCV2 can cause lesions of spermatocyte and oocyte prior to zygotes formation in its host.

Key words: germocytes lesions, porcine circovirus type 2b, Kunming mice

Introduction

Porcine circovirus type 2 (PCV2) was found to be the main cause of postweaning multisystemic wasting syndrome (PMWS) in pigs in the late 1990s in Canada. Since then, the PMWS and other porcine circovirus associated diseases (PCVAD) have caused severe economic losses to the global swine industry. One such disease, porcine-circovirus-associated reproductive failure, has been diagnosed on numerous PCV2-contaminated swine farms (de Castro et al. 2012, Karuppannan et al. 2016). Stillbirths, mummification, embryonic death, dysgenesis, declines in spermatozoa quality and decreases in litter size were common findings in the field of PCV2-associated repro-

ductive failure (Madson and Opriessnig 2011). PCV2 has been shown to be a fetal pathogen by clinical and experimental studies (Yoon et al. 2004, Karuppannan et al. 2016). However, the mechanism by which PCV2 harms or may harm the germocytes in its host is poorly understood. The objective of this study was to determine whether PCV2 can induce lesions on spermatocytes and oocytes, thereby decreasing the quality of spermatozoa and the number of mature ovarian follicles.

Materials and Methods

Nine male and 9 female Kunming mice, 6 weeks old, were purchased from SJA Laboratory Animal

Correspondence to: Z.B. Deng, e-mail: zbangd@hunau.edu.cn

¹ The first and second authors contributed equally to this work

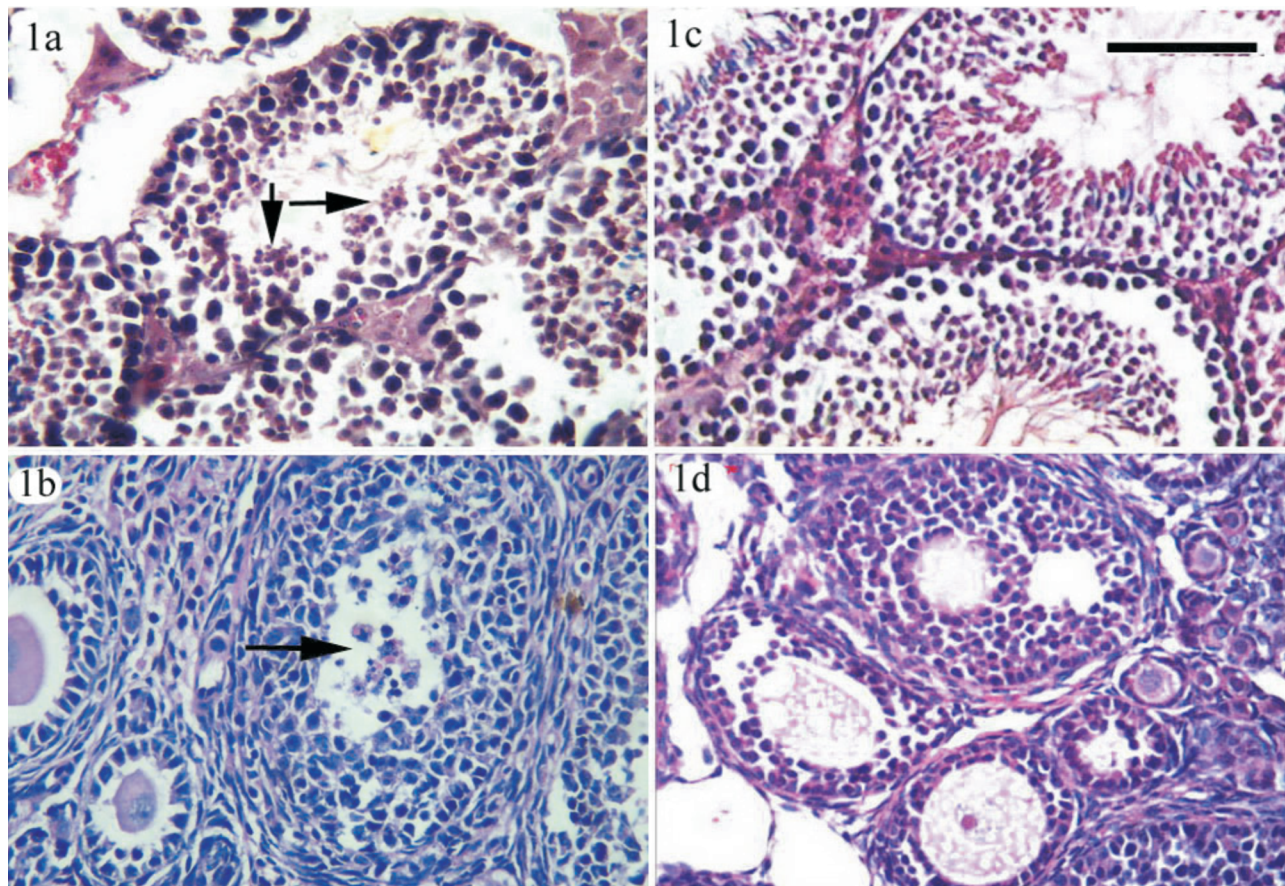


Fig. 1. Histopathologic sections. Spermatocytes (Fig. 1a) and oocytes (Fig. 1b) undergoing apoptosis in PCV2b-inoculated mice at 21 dpi are indicated with arrows. Testes (Fig. 1c) and ovaries (Fig. 1d) from mock-infected mice served as controls. Sections were stained with hematoxylin-eosin (HE) staining method. Bar = 100 μ m.

Co., Ltd, Changsha, Hunan, China. Their specific-pathogen free (SPF) status was verified by the supplier. PCV2b (GenBank accession number EU095020) preparation was as described in our previous reports (Deng et al. 2013b).

Six male and 6 female mice ($n = 12$) were each inoculated intraperitoneally with a PCV2b inoculum containing 10,000 TCID₅₀ in 0.2 ml cell culture supernatant and kept in 2 cages (male-female separation). An additional 3 male and 3 female mice were mock-infected with cell culture supernatant to serve as controls ($n = 6$). At 14 and 21 days post infection (dpi), 3 PCV2b-inoculated female and 3 male mice were euthanatized. Samples of testes and ovaries were collected for PCR, histopathological, ultrastructural, and immunofluorescent histochemical assessment. Samples from mock-infected mice were collected at 21 dpi and served as controls. The study was conducted in accordance with ethical guidelines for animal care and use in China (IACUC permit No. HNPR-2009-05003).

PCV2b DNA in tissues was extracted using a viral DNA extract kit (Nanjing Keygen Biotech. Co. Ltd., Nanjing, Jiangsu, China) and detected using PCR with PCV2b-specific primers (Forward primer: 5'-GGAGCTTCCAATCTCCC-3', Reverse primer: 5'-TAGGAGCTCCACACTCC-3'). In brief, PCR amplifications were performed with ABI 2720 (Applied Biosystem, Foster City, CA, U.S.) using 0.8 μ l DNA template, 1.8 pmol of each forward and reverse primers in 15 μ l 2 \times Taq Platinum PCR Mix (Tiangen Co., Ltd., Beijing, China). The reactions were conducted for 35 cycles under the following cycle conditions: 94°C for 30 s, 55°C for 30 s, and 72°C for 30 s. This was followed by elongation at 72°C for 10 min. The PCR products were analyzed on 1.0% agarose gel stained with an ethidium bromide solution. The testes and ovaries from PCV2b-infected and uninfected mice served as positive and negative controls, respectively.

Samples of testes and ovaries from PCV2b-inoculated mice were fixed in 2.5% aldehyde for 24 h, then in osmium tetroxide for 2 h. Tissues of testes and




Fig. 2. TEM sections. Spermatocytes (Fig. 2a) and oocytes (Fig. 2b) undergoing apoptosis, and PCV2b-inclusion bodies in spermatozoa (Fig. 2c) and oocytes (Fig. 2d) in PCV2b-inoculated mice at 21 dpi are indicated with arrows. Sections were stained with lead citrate and uranyl acetate staining method. Bar 1 = 12 μ m, bar 2 = 2 μ m.

ovaries were embedded in Epon812, and ultrathin sections were cut with a LKB-3 ultramicrotome (LKB, Bromma, Sweden) and stained with lead citrate and uranyl acetate. Sections were examined with a transmission electron microscope (TEM) H7500 (Hitachi, Tokyo, Japan).

The immunofluorescent histochemical tests were performed as described in a previous study (Deng et al. 2013a). Briefly, antigens in paraffin tissues were retrieved in 1.0% EDTA at 95°C for 15 min and cooled to room temperature. Then endogenous peroxidase activity was quenched with 3.0% H₂O₂ in methanol (v/v) at room temperature for 10 min. Sections were incubated with 1:100 dilution of mouse anti-PCV2b monoclonal antibody (Abmart Co. Ltd., Shanghai, China) at 37°C for 2.5 h. Then a 1:50 dilution of secondary anti-mouse IgG antibody with fluorescein (Zhong Shan Golden Bridge Co. Ltd; Beijing, China) was added at 37°C for 1 h. Finally, samples

were photographed under a fluorescence microscope (Olympus, Tokyo, Japan).

Results

PCV2b DNA was detected in all PCV2b-inoculated mice at 14 and 21 dpi, and no gross lesions in testes and ovaries were observed in either PCV2b-inoculated or mock-infected mice during the experiment. At 14 dpi, no histopathological lesions were observed in PCV2b-inoculated mice, but TEM assays revealed a certain amount of apoptosis in spermatocytes and oocytes. Histopathological lesions were apparent in the testes and ovaries at 21 dpi. Some of the leydig cells in the testes and granulosa cells in ovaries were found to have degenerated. A small number of spermatocytes (Fig. 1a) and oocytes (Fig. 1b) showed apoptosis in the virus-inoculated mice. Furthermore, the

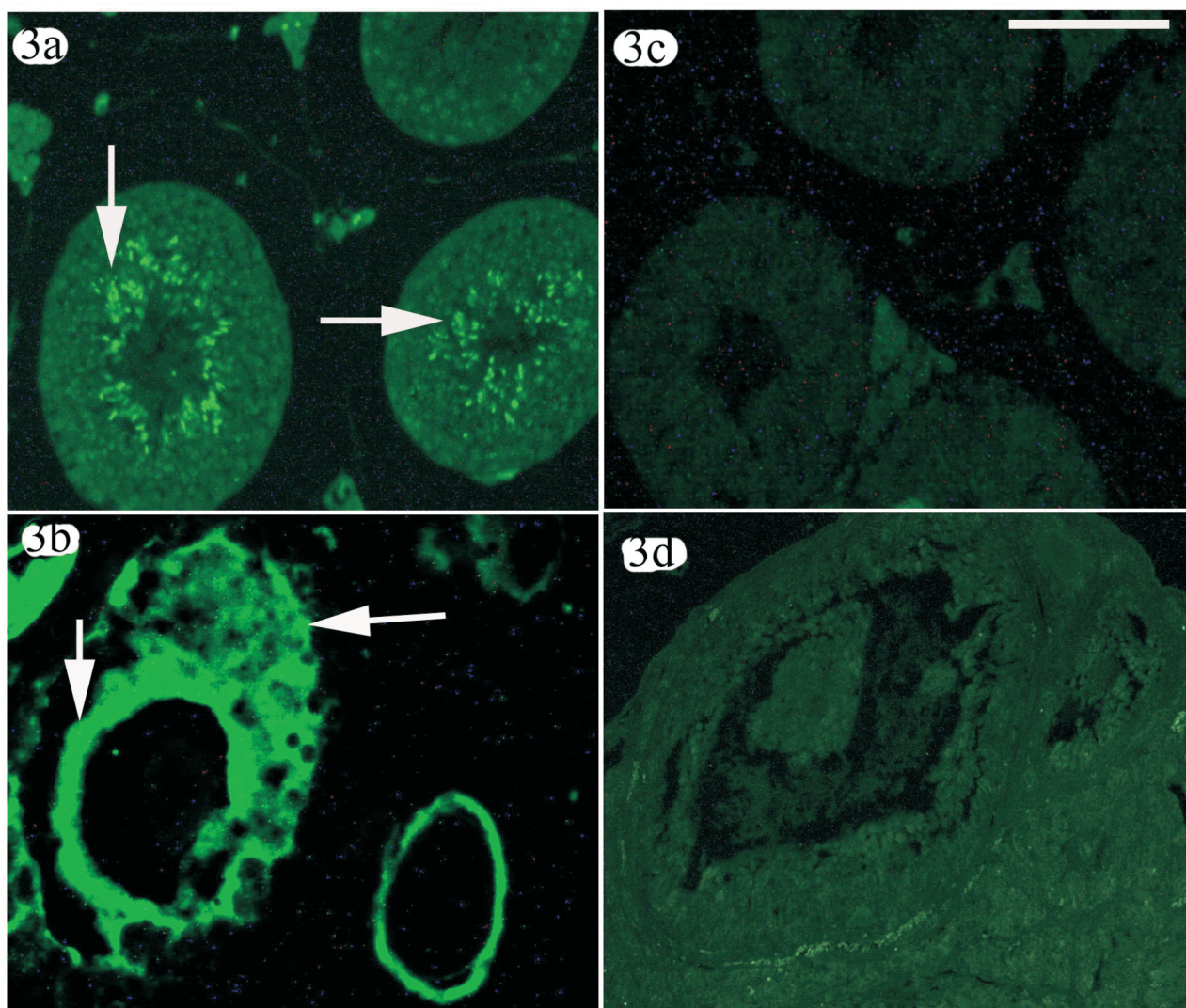


Fig. 3. Immunofluorescent histochemical sections. Positive signals of PVC2b antigen in spermatocytes (Fig. 3a), granulosa cells and zona pellucida (Fig. 3b) of PCV2b-inoculated mice at 14 dpi are indicated with arrows. Testis (Fig. 3c) and ovary (Fig. 3d) were from mock-infected mice and served as negative controls. Sections were stained using the immunohistochemical method. Bar = 100 μ m.

epithelia of the testicular seminiferous tubules were thin, and some of oocytes and ovarian follicles underwent an involutional process, after which follicular atresia developed. The ultrastructural lesion observation showed apoptosis in spermatocytes (Fig. 2a) and oocytes (Fig. 2b), and PCV2b-inclusion bodies were found in spermatozoa (Fig. 2c) and oocytes (Fig. 2d) via TEM. Immunofluorescent histochemical assays revealed positive PCV2b antigen signals in spermatocytes (Fig. 3a), granulosa cells, and zona pellucida (Fig. 3b) in the virus-inoculated mice at 14 dpi and 21 dpi. No histopathological or ultrastructural pathological lesions or positive PCV2b antigen signals were observed in the controls during the experiment.

Discussion

The fetal pathogen PCV2 was first reported by Karuppannan et al. (2016), who found that PCV2 transplacental infection resulted in viral infection of embryos or fetuses in sows. Sarli et al. (2012) found that reproductive failure could be experimentally induced in sows via artificial insemination with PCV2b-spiked semen. They reported that PCV2-seropositive gilts could be infected with PCV2 after intrauterine exposure and that low maternal antibody titers may increase the probability of fetal infection. Madson et al. (2008) were the first to detect PCV2 in semen. They observed continuous shedding of PCV2 in semen for 90 days in Landrace boars. These findings collectively show that PCV2-con-

taminated semen can be singular potential harms to spermatozoa prior to fertilization.

Tummaruk et al. (2016) assessed the expression of PCV2 antigen in ovarian tissues of gilts. Their findings indicated that PCV2 antigen was expressed in all types of ovarian follicles and corpora lutea in naturally PCV2-infected gilts. Bielański et al. (2004) reported that PCV2 can invade to the zona pellucida of developing swine oocytes and embryos. They detected PCV2 DNA by PCR in the follicular fluid, oviductal cells and oocytes. These findings showed that PCV2 poses specific harm to oocytes.

In the PCV2b-inoculated mice in this study, PCV2b DNA was detected in testes and ovaries, and apoptosis and positive PCV2b antigen signals were observed in spermatocytes and oocytes. These results were consistent with those reported by Bielański et al. (2004) and Madson et al. (2008). We here suggest that PCV2 can induce lesions in host spermatocytes and oocytes prior to zygote formation.

In general, PCV2-infected germocytes may decrease sow fertility and cause them to produce infected, mummified, stillborn, or weak piglets. In pig husbandry, rapid PCV2 detection in the breeding boars and sows is very important for producing healthy newborn piglets.

Acknowledgments

This project was supported by the General Program of National Natural Science Foundation of China (Grant No. 31372406); Hunan Provincial Natural Science Foundation of China (Grant No.2015JJ2082); and the Research Foundation of Hunan Provincial Education Department, China (Grant No.15A086).

References

- Bielański A, Larochelle R, Algire J, Magar R (2004) Distribution of PCV-2 DNA in the reproductive tract, oocytes and embryos of PCV-2 antibody-positive pigs. *Vet Rec* 155: 597-598.
- de Castro AM, Cruz TF, Salgado VR, Kanashiro TM, Ferrari KL, Araujo JP Jr, Brandão PE, Richtzenhain LJ (2012) Detection of porcine circovirus genotypes 2a and 2b in aborted fetuses from infected swine herds in the State of São Paulo, Brazil. *Acta Vet Scand* 54: 29.
- Deng ZB, Gong QL, Wang ND, Yuan AW, Yu XL (2013a) Vertical transmission of porcine circovirus 2b (PCV2b) to mouse fetuses in maternal uterus by artificial insemination with semen from PCV2b-infected male mouse. *Turk J Vet Anim Sci* 37: 475-478.
- Deng ZB, Yuan AW, Luo W, Wang ND, Gong QL, Yu XL, Xue LQ (2013b) Transmission of porcine circovirus type 2b (PCV2b) in Kunming mice. *Acta Vet Hung* 61: 234-243.
- Karuppannan AK, Ramesh A, Reddy YK, Ramesh S, Mahaprabhu R, Jaisree S, Roy P, Sridhar R, Pazhanivel N, Sakthivelan SM, Sreekumar C, Murugan M, Jaishankar S, Gopi H, Purushothaman V, Kumanan K, Babu M (2016) Emergence of Porcine Circovirus 2 Associated Reproductive Failure in Southern India. *Transbound Emerg Dis* 63: 314-320.
- Madson DM, Opriessnig T (2011) Effect of porcine circovirus type 2 (PCV2) infection on reproduction: disease, vertical transmission, diagnostics and vaccination. *Anim Health Res Rev* 12: 47-65.
- Madson DM, Ramamoorthy S, Kuster C, Pal N, Meng XJ, Halbur PG, Opriessnig T (2008) Characterization of shedding patterns of Porcine circovirus types 2a and 2b in experimentally inoculated mature boars. *J Vet Diagn Invest* 20: 725-734.
- Sarli G, Morandi F, Panarese S, Bacci B, Ferrara D, Bianco C, Fusaro L, Bacci ML, Galeati G, Dottori M, Bonilauri P, Lelli D, Leotti G, Vila T, Joisel F, Allan G, Benazzi C, Ostanello F (2012) Reproduction in porcine circovirus type 2 (PCV2) seropositive gilts inseminated with PCV2b spiked semen. *Acta Vet Scand* 54: 51.
- Tummaruk P, Pearodwong P (2016) Expression of PCV2 antigen in the ovarian tissues of gilts. *J Vet Med Sci* 78: 457-461.
- Yoon KJ, Jepsen RJ, Pogranichniy RM, Sorden S, Stammer R, Evans LE (2004) A novel approach to intrauterine viral inoculation of swine using PCV type 2 as a model. *Theriogenology* 61: 1025-1037.