

DOI 10.1515/pjvs-2017-0063

Original article

A trial of doramectin injection and ivermectin spot-on for treatment of rabbits artificially infested with the ear mite “*Psoroptes cuniculi*”

N.M. Elhawary¹, SH. S.G.H. Sorour¹, M.A. El-Abasy³, E.K. Bazh², K. Sultan¹

¹ Department of Parasitology, Faculty of Veterinary Medicine, Kafrelsheikh University, 33516 Kafrelsheikh, Egypt

² Department of Pathology and Parasitology, Faculty of Veterinary Medicine, Damanhour University, 22111 Damanhour, Egypt

³ Department of Poultry Diseases, Faculty of Veterinary Medicine, Kafrelsheikh University, 33516 Kafrelsheikh, Egypt

Abstract

The ear mite “*Psoroptes cuniculi*” is the main cause of ear mange, a highly contagious parasitic skin disease in rabbits all over the world. In the current work, a preliminary therapeutic trial to study the effect of the broad use acaricides doramectin and ivermectin on *P. cuniculi* was performed on artificially infested rabbits.

Twenty five adult New Zealand white rabbits were used in this study. The rabbits were assigned randomly into five groups/ 5 rabbits in each group. Each rabbit was experimentally infested with 100 mites/ ear. The first group was designated the positive control group and was not treated. The second and third groups were treated with doramectin 200 and 400 µg/kg bw, respectively. Groups 4 and 5 were treated by dressing with ivermectin in one dose and 2 doses with a 1 week interval. After the therapy, all rabbits were examined microscopically on the 7th, 14th, and 28th day post treatment and the number of live mites (larvae, nymphs, and adults) on each rabbit was counted at the end of the experiment (28th day).

The results showed that the rabbits treated subcutaneously with doramectin at a single dose of 200 µg /kg bw showed a very low effect, although there was significant improvement when the dose was doubled to 400 µg /kg bw, with the number of mites counted decreasing significantly. Rabbits treated topically with ivermectin spot-on, a single dose or 2 doses, showed great improvement of the lesion: the number of mites was reduced to zero. In conclusion, this work showed that ivermectin spot-on applied locally on infested ears proves to be more effective against *P. cuniculi* than doramectin injected subcutaneously. Further trials on ear mange therapeutics in rabbits are to be encouraged.

Key words: rabbits, *Psoroptes cuniculi*, ear mange, treatment, ivermectin, doramectin

Introduction

Ear mange caused by *Psoroptes cuniculi* is a common parasitic disease worldwide in domestic rabbits (White et al. 2002). *Psoroptes* mites are cosmopolitan ectoparasites that infest several mammalian hosts; the ear mite, *P. cuniculi*, is a highly contagious mite which mainly affects the rabbit and usually lives inside the ear pinnae, where it reproduces in a quick life cycle (Burke 1992, Harkness and Wagner 1997). *P. cuniculi* infestation also causes reduction of body weight and may result in death, as it feeds on serous exudate, skin secretions and blood, causing pruritis in untreated rabbits, with the formation of crusts and scabs (Bates 1999, Beck 2000, Wall and Shearer 2001). In addition, *P. cuniculi* can spread to other parts of the body of the host, causing a generalized pruritis and crusting dermatitis of the head and neck (Hughes 2004), ventral abdomen and urogenital regions (Wall and Shearer 2001). Furthermore, it is zoonotic parasite as it can easily infest human beings (Burke 1992, Harrenstien et al. 1995, Acaret et al. 2007).

The choice of an effective acaricidal drug is an important question for all veterinarians as well as rabbits holders, to combat the serious problem of mite infestation. The cost, efficacy, toxicity and application method of the acaricidal drug should be taken into account in selecting treatment for ear mange in rabbits. Multiple drugs and therapeutics can be used in treatment of ear mange such as ivermectin (Bowman et al. 1992, Kurade et al. 1996), doramectin (Narayanan et al. 2004, Kanbur et al. 2008), selamectin (McTier et al. 2003, Kurtdede et al. 2007, Farmaki et al. 2009) and moxidectin (Wagner and Wendlberger 2000); all these drugs in various doses and several routes of delivery have been reported to be effective against *P. cuniculi* in rabbits.

The aim of the present study was to carry out a preliminary trial to assess the therapeutic effect on *P. cuniculi* infestation of two commonly used acaricidal agents (doramectin and ivermectin), in order to find a safe, convenient and easily applicable treatment to control this highly contagious parasitic skin disease.

Materials and Methods

Collection and quantification of the adult mite of *P. cuniculi*

Live *P. cuniculi* mites were collected from naturally infested rabbits in the Kafrelsheikh Governorate, Egypt. Infestation was identified by macroscopic lesions and confirmed through microscopic examin-

ation, selecting and counting *P. cuniculi* with a mobility and morphology coincident with those described in earlier studies (Lekimme et al. 2006, Bowman 2009).

Experimental design and treatment strategy

Twenty five adult New Zealand white rabbits of the same age were used in these experiments. The rabbits were kept under farm conditions, at room temperature (15-25°C).

All rabbits were healthy and fed on balanced rations and had a clean source of water ad libitum.

Ethical approval

The sampling procedures adhered to institutional ethical and animal care guidelines, and all methods were conducted in accordance with the Guide for the Care and Use of Laboratory Animals.

Experiment procedures

After one week of purchasing and housing of rabbits, experimental infestation was carried out by placing previously collected live mites in the ear conduct (100 mites/ear), which was occluded with cotton held with tape (Siegfried et al. 2004, Calleros et al. 2013). To confirm that the rabbits were infested with the mites, microscopic examination of ear swabs of the external ear canal mixed with mineral oil from each rabbit was carried out. During the course of the experiment, all rabbits were observed carefully and weighed daily.

Rabbits were assigned randomly into five groups (5 rabbits each). Each rabbit in all groups was experimentally infested. Rabbits in the first group underwent the same procedure, excluding application of treatment. This group (G1) was the positive control group.

The second and third groups (G2 & G3) were treated with doramectin (Dectomax[®], Pfizer, Egypt) 200 µg/kg bw and 400 µg/kg bw delivered by subcutaneous injection, respectively. Finally, groups G4 & G5 were treated by dressing with ivermectin (Iverzine[®] lotion 1%, Unipharma, Egypt) delivered topically by spot-on in one dose and 2 doses with a 1 week, respectively.

After 3 weeks of experimental infestation, the tested drugs were applied as mentioned above (i.e. 0 day post treatment). After therapy, all rabbits were examined microscopically on the 7th, 14th, and 28th day post treatment. To calculate the efficacy of the experiment,

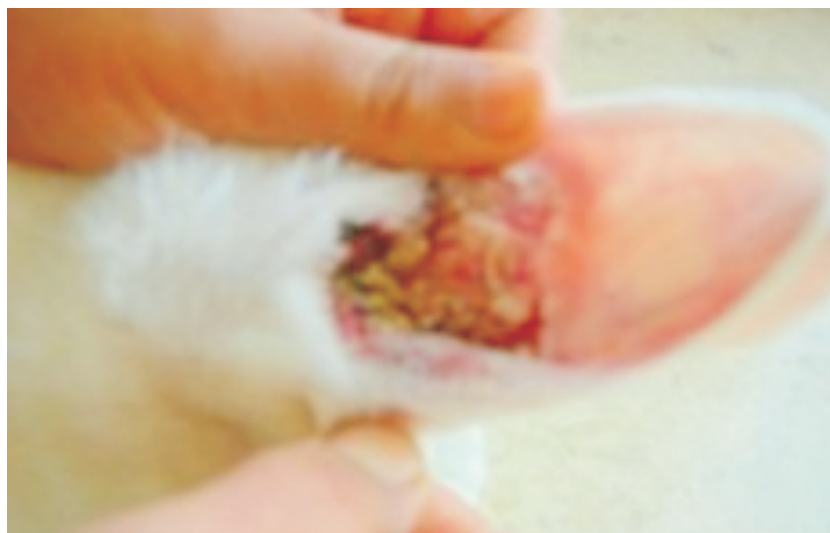


Fig 1. Ear of artificially infested rabbit with *Psoroptes cuniculi* showing formation of crusts and scabs.

the number of live mites (larvae, nymphs, and adults) on each rabbit was counted at the end of the experiment (i.e. 28th day post treatment).

Statistical analysis

Statistical analysis was performed using SPS software (SPS, 2007) to assess the presence of statistically significant differences in the therapeutic effects of the treatments used.

We corrected for significance values using Duncan's multiple range test (Gomez and Gomez 1984). Statistical significance was set at $p < 0.01$.

The efficacy of the treatment with doramectin injection and ivermectin spot-on was calculated using the formula below:

$$\text{Efficacy \%} = \frac{\text{Mean of MPG from GC} - \text{Mean of MPG from GT}}{\text{Mean of MPG from GC}} \times 100$$

Mean of MPG from GC

Where: MPG: Mites per gram of crust, GC: control group, and GT: treated group.

The efficacies were categorized as: highly effective when Efficacy % > 98%; effective when 90-98%; moderately effective 80-89%; and insufficiently effective < 80% (Ordination 79/1996 MERCOSUL, GMC, 1996; In Holsback et al. 2016).

Results

After the infestation of *P. cuniculi* mites was established successfully, clinicopathological features of

ear mange infestation were observed in all infested groups (G1 to G5). These features were restlessness, severe inflammation and irritation of the ear pinna, and accumulation of a yellowish brown, sour smelling discharge leading to crust and ulcer formation (Fig. 1). Severe itching and head shaking to get rid of the discharge was evidenced and documented. In cases of severe mite infestation, torticollis, oblique position and the turning in a circular direction of the afflicted rabbit was apparent, due to the mites penetrating the inner ear and the base of the brain.

This was manifested most clearly in the infested but untreated control positive group (G1). Artificial infestation was confirmed microscopically by demonstration of *P. cuniculi* in ear swabs from infected groups.

There was little amelioration of the mites in rabbits treated with doramectin at a single dose of 200 $\mu\text{g}/\text{kg}$ bw/ by subcutaneous injection (G2). This appeared from the number of living mites. However, doramectin administered at a dose of 400 $\mu\text{g}/\text{kg}$ bw (G3) significantly reduced the number of mites, which became scarce (Table1). No mortality occurred and there were no adverse effects in performance or in body weight in both groups treated with doramectin.

Finally, rabbits treated topically with locally applied ivermectin lotion (Iverzine1%) in a single application (G4) or 2 applications with 1 week interval (G5) exhibited a marked decrease in the number of mites, which were reduced to zero in group G5 (Table 1). No mortality or adverse effects occurred, either in rabbits' performance or in their body weight, in the groups that were treated with ivermectin.

Table 1. Efficacy comparison of doramectin injection and ivermectin spot-on to treat *Psoroptes cuniculi*, efficacy calculated based on number of living mites per gram / ear scraping in control and treated rabbit groups.

Rabbit	Group				
	G1	G2	G3	G4	G5
R1	100	22	0	2	0
R2	67	30	0	0	0
R3	60	55	4	0	0
R4	90	5	0	0	0
R5	80	45	7	0	0
Mean**	79.4 ^a	31.4 ^b	2 ^{cd}	0.4 ^d	0 ^d
Efficacy (%)	–	60.45	97.48	99.50	100.00

D = dead; R = Rabbit; ** = $p < 0.01$

Means designated by the same letter are not significantly different at 5% level using Duncan's multiple range test.

* G1 = infected and non-treated control, G2 = infected and treated by doramectin subcutaneous injection at a dose 200 µg/kg bwt, G3 = infected and treated by doramectin subcutaneous injection at a dose 400 µg/kg bwt, G4 = infected and treated by ivermectin local dressing once, and G5 = infected and treated by ivermectin local dressing twice at 1 week interval.

Discussion

The ear mite *P. cuniculi* is a universal ectoparasite frequently found on rabbits. Lesions are usually restricted to the ears, but without proper medication and control, these ectoparasites may spread vigorously (Saunders, 1979). In the present study, a preliminary experiment was performed to investigate the effect of doramectin (s/c injection) and ivermectin (topical dressing) on *P. cuniculi* in experimentally infested rabbits.

The avermectins are a group of potent, broad spectrum antiparasitic drugs that act as an agonist of the GABA (gamma – aminobutyric acid) neurotransmitter in nerve cells. Avermectins also bind to glutamate-gated chloride channels in the nerve and muscle cells of invertebrates. In both cases, the drug blocks the transmission of neuronal signals of the parasites and causes paralysis and death of the parasites (Chabala et al. 1980, Albers-Schoenberg et al. 1981).

Doramectin is a highly effective acaricidal drug when applied subcutaneously, in a dose of 200 µg/kg bw for treatment of *P. cuniculi* infestation (Narayanan et al. 2004, Voyvoda et al. 2005, Kanbur et al. 2008) and also when applied in a dose of 400 µg/kg bw (Kaya et al. 2010). In our experiment, doramectin was used in 2 doses of 200 µg/kg body weight and 400 µg/kg bw as recommended. The findings showed that using 200 µg/kg bw for the treatment of *P. cuniculi* infestation is not effective for the complete elimination of mites. The findings show that using 400 µg/kg bw is more effective than using the lower dose (200 µg/kg bw). This was apparent from the number of mites eliminated, as shown

in Table 1. No adverse effect was observed in doramectin-treated groups during the whole course of the experiment. It is concluded that using doramectin in a dose of 400 µg/kg bw is the recommended dose for treatment of *P. cuniculi* infestation in rabbits.

The topical application of acaricidal drugs like ivermectin and salamectin in order to treat *P. cuniculi* infested rabbits is an effective and convenient method (McTier et al. 2003, Kurtdeedee et al. 2007, Fisher et al. 2007, El-Abasyet al. 2008). The results of the present study confirm that a single topical application of ivermectin 1% spot-on can completely eliminate mites from rabbits infested with *P. cuniculi* (i.e. G4). Our results show that no live ear mites were recovered from any ivermectin spot-on treated rabbits in group G5, while all control rabbits (G1) remained infested with *P. cuniculi* mites. This result agrees with the results of (El-Abasyet al. 2008, Kaya et al. 2010). Moreover, the topical application of ivermectin did not negatively affect the rabbits' performance or body condition, nor did it cause any mortality in the treated rabbits. It is found to be easier and safer to deliver the drug by local application, like ivermectin, than by subcutaneous injection, like doramectin.

In conclusion: this study was a preliminary trial to treat rabbits experimentally infested with *P. cuniculi* by two drugs of different methods of application; doramectin by subcutaneous injection and ivermectin by local topical application. Further experiments and investigations on acaricidal therapeutics against rabbit mange are highly encouraged to test its efficacy and side effects.

Acknowledgments

The authors wish to express their deep gratitude to all members of the Parasitology Department, Faculty of Veterinary Medicine, Kafrelsheikh University for their valuable help in this study. Also, they are thankful to Agatha Bardoel for her language revision of the manuscript.

References

- Acar A, Kurtde A, Ural K, Cingi CC, Karakurum MC, Yaci BB, Sari B (2007) An Ectopic Case of *Psoroptes cuniculi* Infestation in a Pet Rabbit. *Turk J Vet Anim Sci* 31: 423-425.
- Albers-Schoenberg G, Arison BH, Chabala JC, Douglas AW, Eskola P, Fisher MH (1981) Avermectins: Structure determination. *J Am Chem Soc* 103: 4216-4221.
- Bates PG (1999) Inter and intra-specific variation within the genus *Psoroptes* (Acari: Psoroptidae). *Vet Parasitol* 83: 201-217.
- Beck W (2000) Ear mange in domestic rabbit caused by *Psoroptes cuniculi* (Acari: Psoroptidae) – Biology of *Psoroptes cuniculi*, pathogenesis, clinical features, diagnosis and treatment. *Kleintierprax* 45: 301-308.
- Bowman DD (2009) *Georgis' Parasitology for Veterinarians* 9th ed. Saunders-Elsevier Publishers, Missouri, pp 64-70.
- Bowman DD, Fogelson ML, Carbone LG (1992) Effect of ivermectin on the control of ear mites (*Psoroptes cuniculi*) in naturally infested rabbits. *Am J Vet Res* 53: 105-109.
- Burke TJ (1992) Skin disorders of rodents, rabbits and ferrets. In: Kirk RW, Bonagura JD (eds) *Current Veterinary Therapy XI Small Animal Practice*. W.B. Saunders Co., Philadelphia, London, Toronto, pp 1170-1175.
- Calleros CH, Montor JM, Montiel JA, Hoffman KL, Rodrtiguez AN, Perez FI (2013) Hormonal and behavioral changes induced by acute and chronic experimental infestation with *Psoroptes cuniculi* in the domestic rabbit *Oryctolagus cuniculus*. *Paras Vectors* 6: 361.
- Chabala JC, Mrozik H, Tolman RL, Eskola P, Lusi A, Peterson LH (1980) Ivermectin, a new broad-spectrum antiparasitic agent. *J Med Chem* 23: 1134-1136.
- El-Abasy MA, Desouky AY, Abdien HM (2008) Comparative field efficacy of systemic, oral and topical application of ivermectin against *Psoroptes cuniculi*, the ear mange mite in naturally infected rabbits. *Kafrelsheikh Vet Med J* 6: 460-470.
- Farmaki R, Koutinas AF, Papazahariadou MG, Kasabalas D, Day MJ (2009) Effectiveness of a selamectin spot-on formulation in rabbits with Sarcoptic mange. *Vet Rec* 164: 431-432.
- Fisher M, Beck W, Hutchinson MJ (2007) Efficacy and Safety of Selamectin (Stronghold®/Revolution™) Used Off-Label in Exotic Pets. *Int J Appl Res Vet Med* 5: 87-96.
- Gomez KA, Gomez A.A. (1984) *Statistical Procedures for Agricultural Research*. 2nd ed., Jahn Wiley Sons, New York, pp 217-215.
- Harkness JE, Wagner JE (1977) *The Biology and Medicine of Rabbits and Rodents*. Lea & Febiger Publication, Philadelphia, pp 73-75.
- Harrenstien L, Gentz EJ, Carpenter JW (1995) How to handle respiratory, ophthalmic, neurologic, and dermatologic problems in rabbits. *Symposium on Rabbit Medicine*. *Vet Med*: 373-380.
- Holsback L, Luppi PAR, Silva CS, Negrão GK, Conde G, Gabriel HV, Balestrieri JV, Tomazella L (2016) Anthelmintic efficiency of doramectin, fenbendazole, and nitroxynil, in combination or individually, in sheep worm control. *Rev Bras Parasitol Vet* 25: 353-358.
- Hughes JE (2004) Diagnosis and treatment of selected rabbit dermatologic disorders. *Exot DVM* 5: 18-20.
- Kanbur M, Atalay O, Ica A, Eraslan G, Cam Y (2008) The curative and antioxidative efficiency of doramectin and doramectin+vitamin AD3E treatment on *Psoroptes cuniculi* infestation in rabbits. *Res Vet Sci* 85: 291-293.
- Kaya D, Inceboz T, Kolatan E, Guneli E, Yilmaz O (2010) Comparison of efficacy of ivermectin and doramectin against mange mite (*Sarcoptes scabiei*) in naturally infested rabbits in Turkey. *Vet Itali* 46: 51-56
- Kurade N P, Bhat T K and Jithendran K P (1996) Effect of ivermectin against ear mange mite (*Psoroptes cuniculi*) in naturally infested rabbits. *World Rabbit Sci* 4: 25-27.
- Kurtde A, Karaer Z, Acar A, Guzel M, Cingi CC, Ural K, Ica A (2007) Use of selamectin for the treatment of *Psoroptic* and *Sarcoptic* mite infestation in rabbits. *Vet Dermatol* 18: 18-22.
- Lekimme M, Mignon B, Tombeux S, Focant C, Marechal F, Losson B (2006) In vitro entomopathogenic activity of *Beauveria bassiana* against *Psoroptes* spp. (Acari: Psoroptidae). *Vet Parasitol* 139: 196-202.
- McTier TL, Hair A, Walstrom DJ, Thompson L (2003) Efficacy and safety of topical administration of selamectin for treatment of ear mite infestation in rabbits. *J Am Vet Med Assoc* 223: 322-324.
- Narayanan K, Rajendiran AS, Rajapandi S (2004) Effect of doramectin on the treatment of ear and skin mange in rabbits. *Ind Vet J* 81: 628-630.
- Saunders EB (1979) Ear-mite infestation. *Vet Med Small Anim Clin* 74: 218-219.
- Siegfried E, Ochs H, Deplazes P (2004) Clinical development and serological antibody responses in sheep and rabbits experimentally infested with *Psoroptes ovis* and *Psoroptes cuniculi*. *Vet Parasitol* 124: 109-124.
- Voyvoda H, Ulutas B, Eren H, Karagenc T, Bayramli G (2005) Use of doramectin for treatment of Sarcoptic mange in five Angora rabbits. *Vet Dermatol* 16: 285-288.
- Wagner R, Wendlberger U (2000) Field efficacy of moxidectin in dogs and rabbits naturally infested with *Sarcoptes* species, *Demodex* species and *Psoroptes* species mites. *Vet Parasitol* 93: 149-158.
- Wall R, Shearer D (2001) The diagnosis and control of ectoparasitic infestation. In: *Veterinary Ectoparasites-Biology, Pathology & Control*. 2nd ed., Oxford, London, Edinburgh: Blackwell, 179-242.
- White SD, Bordeaux PJ, Meredith A (2002) Dermatologic problems of rabbits. *Semin Avian Exot Pet Med* 11: 141-150.