

Structural approach to medical image understanding

R. TADEUSIEWICZ and M. R. OGIELA*

Institute of Automatics, AGH University of Science and Technology, 30 Mickiewicza Ave., 30-059 Kraków, Poland

Abstract. This paper proposes a new approach to the processing and analysis of medical images. We introduce the term and methodology of medical data understanding, as a new step in the way of starting from image processing, and followed by analysis and classification (recognition). The general view of the situation of the new technology of machine perception and image understanding in the context of the more well known and classic techniques of image processing, analysis, segmentation and classification is shown below.

Keywords: artificial intelligence, image understanding, pattern analysis, medical imaging.

1. Introduction

Medical procedures which involve the use of various images constitute a particularly interesting and important field of informatics, especially as contemporary medical diagnosis is to a large extent based on images. Medical imaging technology (IT) has now become one of the major sources of information for therapy and also for research in medicine, biology and in other related fields. This information covers the morphology of examined organs and their function (though in a limited degree), which affords us the means to infer whether their functioning is correct and whether the structures are pathological. This allows well-founded conclusions to be drawn or helps in modern diagnostic reasoning processes.

Thanks to the inventiveness of many engineers' and their attempts to still find better ways to collect and present information about the shape and functioning of man's internal organs, we now have at our disposal a vast number of medical imaging techniques. Present-day biomedical engineering provides physicians with all images of the internal organs and processes; and furthermore it gives them the tool for improvement, appraisal and the classification of images: computer vision- an advanced IT technique. At the present stage computer vision enables three types of computer processing of images:

- image processing — aimed to improve the quality of the image (enhancement, sharpening and contrasting) and to separate and highlight only those objects which are vital from the medical point of view (segmentation)
- image analysis — aimed to determine the features of the whole image or specified objects, to count the objects and compute the value of quantitative parameters or names of categories assigned to quality features
- pattern recognition — aimed to identify and classify the highlighted elements or areas through indexing them as objects belonging to certain categories determined a priori — mainly on the basis of their shape, dimensions and texture.

One has to bear in mind that all of these three steps of classical computer processing of medical images are be-

coming more widespread, which clearly shows their major role in biomedical engineering. These techniques prove to be particularly useful tools for medical physicians as thanks to image processing and enhancement the details of the examined organs and processes are brought to light, which helps them to provide a reliable diagnosis. Having at their disposal computer results of analyses of image features and objects, physicians may support their reasoning on more tangible and reliable premises than just visual image evaluation, which improves their efficiency and gives them the feeling of confidence and security. Finally, more and more widespread techniques of automatic recognition and classification of highlighted biological structures may help the physicians to provide the right diagnosis though they sometimes require a critical approach to automatically suggested categorization as each pattern recognition technique admits a certain level of error. Physicians, on the other hand, are never free from personal responsibility for their decisions.

But there are some problems in this model of co-operation between 'computer vision' engineers and the physician because of the still insufficient development of proper methods for automatic interpretation of medical images. This task is very difficult because of two types of troubles:

- first, the morphology of the health organ is different for every human being, so we do not have any kind of template (or pattern) of the 'proper view' of the analysed object.
- second, deformations of the organ shape and size can be very different in form, number and also in localization if the diseases are in fact identical!

Despite such troubles we need a new mechanism for the application of contemporary computers for medical image utilization for physicians' purposes. This mechanism needs to be connected with the merit content of medical images instead of its form. We have proposed and developed such a mechanism and have called it the 'automatic understanding' of medical images. We have dedicated this entire paper to the description of this concept and its application.

* e-mail: mogiela@agh.edu.pl

R. Tadeusiewicz, M. Ogiela

All afore mentioned techniques of computer processing, analysis and recognition of medical images prove insufficient to tackle all the tasks and problems that arise in connection with the use of images as valuable sources of medical information. The most fundamental and vital aspect is the interpretation of collected data, referring to the physician's knowledge. At the present stage the physicians' knowledge of correct and pathological anatomy and the physiology of examined organs and structures is the only key to their proper understanding, and this why the medical image looks the way it does. Owing to the computer processing of images the shapes of organs and lesions can be better visible; however physicians provide their interpretation of the image.

The process of selection and definition of image features, supplementing the automatic analysis and classification provides only certain premises for the process of physicians' reasoning based on their knowledge, imagination and sometimes also intuition. Without a meritorious interpretation of the results of all analyses and elements of automatic classification, they become useless for the purpose of diagnosis and therapy; the actual values of specified image parameters or the categorization of imaged objects are of minor importance. One thing that is important for the physician (and the patient of course): what does this all imply in terms of patient's condition, the suggested diagnosis of an illness, the optimal therapy or rehabilitation and the chances for success? Contemporary techniques providing various types of medical images as well as IT technologies including computer vision depend on one major factor: the interpretation of medical images by humans (i.e. well-qualified physicians).

The process, however, is becoming increasingly difficult for humans (i.e. physicians) as the numerous and complex images made available to us by technological advancements require that physicians acquire new skills and qualifications to correctly interpret them and it usually takes longer than the development of new technologies. Furthermore, new imaging techniques provide the physician giving the diagnosis not only with one image as before, but with many (sometimes more than ten) images taken for one patient that have to be analysed. These numerous images portray, for example, subsequent cross-sections of the brain tissue obtained with the use of tomography or present the organ at various stages of the process of absorption or removal of the chemical agent. Sometimes the same organ can be observed with the use of several imaging techniques. Thus the diagnostic procedure becomes more detailed and reliable though, at the same time, however, it requires extra effort on the part of physicians.

As the analysis of such a number of different images is becoming increasingly difficult and time-consuming, a physician may overlook a lesion visible in one of the images only, which in consequence may lead to an error in the diagnosis. Besides, we can hardly expect that

a physician will be able to analyse and evaluate all available medical images as there are so many of them and the visual forms of the presented organs may differ too, depending on the applied imaging technique. Further complications result from the fact that a physician has in fact no time to become accustomed with all forms and shapes of images since new-generation medical apparatuses are entering the market at a fast pace. In the past physicians found routine a great help: at a first glance an experienced radiologist would pinpoint the part of the image which required his particular attention and then ignore other morphological details, visible but not important. Nowadays physicians are not able to acquire such a routine as medical apparatuses are now always being replaced with newer, improved versions and physicians are not given an opportunity to become accustomed with them. Renowned (and rather rich) hospitals which try to catch up with the technological advancements and attempt to acquire the newest diagnostic apparatus are now faced with a major problem. The apparatus are better, there is more information available and yet the physicians feel somewhat lost: before an image provided by one of the diagnostic systems becomes as familiar to them as a dial-plate of the clock, new-generation equipment will appear and well-known images will be replaced with new ones: maybe better and more refined but unfamiliar.

When we consider in this short summary of problems associated with the interpretation of presently available medical images, how many organs can be examined and how many types of deformations and lesions are possible, we should not be surprised by the statement that this branch urgently needs the strong support of advanced IT technologies. Actually as new techniques of medical imaging are developed, there is a growing demand for better techniques of computer-assisted analysis, interpretation, classification and recognition of available medical images. People tend to expect that modern equipment will not only portray the interiors of the human body and give it a maximally clear representation, but will also perform the preliminary analysis of the image thus obtained, directing the physicians' attention to those elements which may carry the most vital information for the diagnosis. This means that the computer has to make a (sometimes complex) computation of the value of each of several million pixels making up the image. Furthermore, it is expected to perform an intelligent analysis and pass on suggestions to physicians — this is a major challenge for IT engineers who must not only develop but also constantly improve imaging techniques. This paper is the result of several years' of work of the Authors, who developed and tested several methods for assisting the meritorious interpretation of medical images, which involved going 'deep inside' the image contents. In light of the main concept presented in this paper, two basic assumptions have to be made. The first assumption is that a semantically-oriented (linguistic) description of

the medical image contents can be created automatically, which is exclusively on the basis of duly performed analysis of graphic structures detected in the image and their interrelations. As a rule, such analysis ought to be preceded by preliminary image processing, involving the carefully chosen sequences of routine procedures of image filtering, segmentation and transformations so that the components vital for image interpretation are brought to light while technical distortions and factors responsible for biological variety are eliminated as they may hinder the semantically-oriented analysis. The other assumption is that a semantically-oriented description of the medical image contents, vital for diagnostic purposes, ought to be confronted with the appropriately expressed semantic expectations and predictions (in our case those included in the graph grammar). These semantic expectations are derived from our knowledge a priori about the diagnostic and prognostic meaning of certain structures contained in the considered class of medical images; hence they are specific for the given field. This means that a proper representation of knowledge, which is the key to an automatic understanding of medical images, is not universal and has to be generated separately for each category of medical problems. In other words, a proper representation of medical knowledge (for instance in the form of graph grammar) is required for each type of medical imaging, for each organ and disease. Undoubtedly, this is long and hard work, but when completed, automatic understanding of a wider range of medical images can be made possible. This should prove to be a strong incentive for the further development of medical imaging techniques, particularly in the field of medical image interpretation which so far has received little attention, thus the classical triad: processing, analysis and recognition of medical images can be extended and/or strengthened.

2. Features of automatic image understanding

Now we shall try to explain what automatic image understanding is and how we can force the computer to understand the image content. Before we get down to details we must demonstrate that there is in fact a fundamental difference between a formal description of an image (typically obtained by means of a variety of computer viewing methods) and the content meaning of the image, which can be discovered by an intelligent entity, capable of understanding the profound sense of the image in question.

The fundamental features of medical image automatic understanding (according to our proposal) can be listed as follows:

- We try to imitate the natural method in which a medical doctor thinks: he/she needs to understand the disease before making a formal diagnosis and choosing the right treatment.
- First we make a linguistic description of the image

contents, using a special kind of image description language. Owing to this idea we can describe every image without specifying any limited number of a priori described classes.

- The linguistic description of an image content constructed in this manner is the basis for an understanding image diagnosis or for indexing multimedia data bases.

3. Fundamental definition of picture grammar

This section presents the two basic terms of the picture grammars (context-free and graph) that are associated with syntactic pattern recognition methods.

DEFINITION 1. A context-free grammar $G=(V_N, V_T, SP, STS)$ is the LR(k)-type grammar (for $k \geq 0$) if, for each derivation step of forms:

$$\begin{aligned} STS &\Rightarrow^R \mu A \omega \Rightarrow \mu \chi \omega, \mu \in V^*, \omega \in V_T^*, A \rightarrow \chi \in SP \\ STS &\Rightarrow^R \mu' B \omega' \Rightarrow \mu' \gamma \omega', \mu' \in V^*, \omega' \in V_T^*, B \rightarrow \gamma \in SP. \end{aligned}$$

The condition $(|\mu\chi| + k) : \mu\chi\omega = (|\mu'\gamma| + k) : \mu'\gamma\omega'$ implies that:

$$\mu = \mu', \quad A = B, \quad \chi = \gamma$$

where: \Rightarrow^R denotes the right-hand derivation (right-hand derivation or a derivation step) in grammar, i.e. in each new step a new text string is derived from the rightmost non-terminal symbol.

$V = V_T \cup V_N, V^* = \{\mu : \mu = x_1 x_2 \dots x_n, n \geq 1, x_i \in V \text{ for } i = 1 \dots n\} \cup \lambda$ (λ is an empty symbol)

$V_T^* = \{\omega : \omega = y_1 y_2 \dots y_m, m \geq 1, y_i \in V_T \text{ for } i = 1 \dots m\} \cup \lambda,$

$$k : w = \begin{cases} w, & \text{when } |w| < k \\ \alpha, & \text{when } \omega = \alpha\gamma \text{ and } |\alpha| = k. \end{cases}$$

DEFINITION 2. Expansive G_{edt} tree grammar generating trees with directed and labelled edge, i.e. EDT trees. It is defined as a set of five other sets defined as follows [1]:

$$G_{edt} = (\Sigma, \Gamma, r, P, Z)$$

where Σ is a set of terminal and non-terminal vertex labels, r is a function assigning to the tree vertex the number of its successors (children), Z is finite set of start trees, Γ is a set of edge labels and P is a production set with the following form:

$$A \rightarrow a(\tau_1 A_1 \tau_2 A_2 \dots \tau_{r(a)} A_{r(a)})$$

where: $A_1, A_2 \dots A_{r(a)}$ are non-terminal vertexes while 'a' is a terminal vertex; $\tau_1, \tau_2 \dots \tau_{r(a)}$ are edge labels.

The right-hand side of the production $a(\tau_1 A_1, \tau_2 A_2 \dots \tau_{r(a)} A_{r(a)})$ denotes an EDT tree written in the parentheses form. The tree has a root and $r(a)$ successor leafs designated labelled $A_1, A_2 \dots A_{r(a)}$, connected to the root by means of $r(a)$ edges labelled as $\tau_1, \tau_2 \dots \tau_{r(a)}$ respectively and directed from the root to the leaves.

The formalism of tree grammars defined in this way will be used later in the paper for analysis of renal pelvis morphology.

4. Analysis and understanding of medical visualisations

This section will present the results of actual medical applications of the new approach described in previous sections. We shall try to demonstrate that the structural pattern analysis can be regarded as an effective tool for medical image understanding, replacing simple recognition. Structural image analysis can be considered as a totally new approach to the analysis and description of shapes of selected organs in medical imaging in general. Examples of syntactic methods of pattern recognition application for the understanding and analysis of selected medical images presented in this section show their usefulness for early diagnosis of some diseases of selected organs.

The section will discuss in particular disease symptom recognition tasks for three selected types of medical images:

1. Analysis of coronary arteries seen on coronographic images [2]. This analysis is aimed to discover the symptoms of the ischaemic heart disease.
2. Renal pelvis with ureters visible on urograms of these structures [3]. An analysis of urograms allows one to diagnose some lesions characteristic for hydronephrosis or extrarenal uraemia.
3. Pancreatic ducts visible on images obtained in the course of ERCP (Endoscopic Retrograde Cholangio-Pancreatography) examinations [4,5]. In this case the objective of the analysis is early computer-aided diagnosis of neoplastic lesions and pancreatitis.
4. Spine and spinal cord visualised on NMR images. The objective is to detect and diagnose lesions that might evidence a whole range of various disease units (from numerous forms of inflammatory conditions to most serious cases of tumours).

The process of recognition will be based mainly on the use of context-free attributed grammars, languages of shape feature description as well as graph grammars used to recognise disease symptoms, which can occur in these organs. This type of recognition may not only support the diagnosis of disease lesions but it also constitutes intelligent information systems imitating the method of image interpretation and understanding as performed by qualified professionals.

For a proper diagnosis of the mentioned changes, and for a verification of how advanced their level is, an attributed context-free grammars of type LR (1) and a graph grammar of type EDT [1] have been proposed. These grammars permit in an unusually effective way the detection of these kinds of irregularities and are also useful in the analysis of coronary artery images, urograms, pancreatograms and spinal cord images. These

methods have been applied to detect changes in the width of different structures, visible in graphs. These graphs are obtained owing to the application of a straightening transformation at the stage of image pre-processing, which enables the production of straightened structure graphs, while preserving morphological lesions occurring in them. The following operations - should be first conducted in the course of pre-processing of the examined images:

1. Segmentation and filtering of the analysed images [6–9].
2. Skeletonisation of the analysed structures [10].
3. Analysis of real and verification of apparent skeleton ramifications [11].
4. Smoothing the skeleton by averaging its elements [12].
5. The application of a specially prepared straightening transformation, transforming the external contour of the examined structures in a two-dimensional space to the form of 2D width diagrams, visualising contours of the ‘numerically straightened’ organ. This transformation retains all morphological details of the analysed structures (in particular their deformations and pathological lesions). For this reason it is a convenient starting point for further analysis of shape feature properties of the analysed structure and for detecting such deformations (with the use of syntactic methods of pattern recognition).

4.1. Structural analysis of coronary vessels. In this section we have presented methods of computer-aided diagnosis for the recognition of morphological lesions of coronary vessels. Recognising such lesions is extremely important from the viewpoint of a correct diagnosis of myocardial ischaemia states caused by coronary atherosclerosis lesions resulting in stenoses of artery lumen, which in consequence lead to myocardial ischaemia disease. This disease can take the form of either stable or unstable angina pectoris or myocardial infarction [2].

The objective of methods described in this section will be to diagnose the stenoses of coronary arteries, in particular the so-called important stenoses: artery lumen stenoses which exceed 50% and occur in the left coronary artery trunk as well as stenoses exceeding 70% of the artery lumen in the remaining segments of coronary vessels. An example of coronary artery image with stenoses has been shown in Fig. 1.

Diagnosing looked-for morphological lesions occurring in the form of various kinds of coronary artery lumen strictures will be conducted on width diagrams obtained in the course of coronary angiogram pre-processing. Those diagrams show the width of the examined coronary vessels. To analyse them we have proposed an attributed grammar allowing the definition of all potential shapes of the expected morphological lesions.

The following attributed grammar has been proposed to diagnose various types of stenosis shapes:

$G_{CA} = (V_N, V_T, SP, STS)$, V_N — set of non-terminal symbols, V_T — set of terminal symbols, SP — production

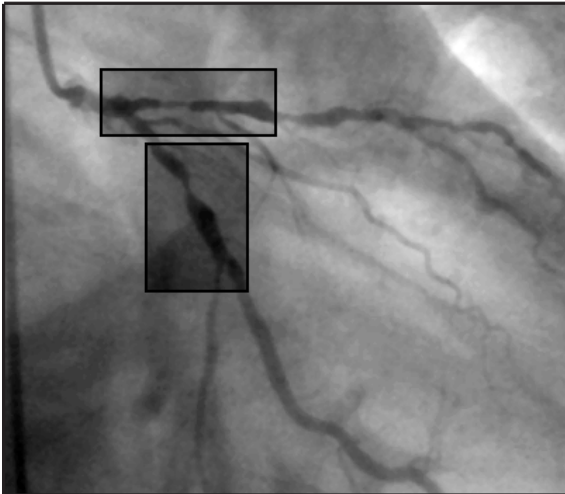


Fig. 1. Image of coronary arteries obtained in the course of coronography examination. The frames mark important strictures of the examined arteries, which will be localised and analysed with the use of structural pattern recognition methods

set, STS — grammar start symbol

$$V_N = \{\text{SYMPTOM}, \text{STENOSIS}, \text{H}, \text{V}, \text{NV}\}$$

$$V_T = \{h, v, nv, \lambda\} \text{ for } h \in (-10^\circ, 10^\circ), v \in (11^\circ, 90^\circ), nv \in (-11^\circ, -90^\circ)$$

$$\text{STS} = \text{SYMPTOM}$$

SP:

1. SYMPTOM \rightarrow STENOSIS Symptom = Stenosis
2. STENOSIS \rightarrow NV H V — NV V — NV H
3. V \rightarrow v — V v $w_{sym} := w_{sym} + w_v$; $h_{sym} := h_{sym} + h_v$
4. NV \rightarrow nv — NV nv
5. H \rightarrow h — H h ...

The use of attributes in this grammar is aimed to determine numeric parameters of the diagnosed stricture, which allow us to determine the percentage rate of the coronary artery lumen stenosis, important for the prognosis of the patient's state.

During the test the image set of analysed data, which has been used in order to determine the efficiency of a correct recognition of the size of stenoses in coronary arteries, included 55 different images obtained for patients with heart disease. Figure 2 presents example of recognising the looked-for lesions in coronary artery image analysed in this paper. Recognised symptoms have been marked with a bold line.

4.2. Understanding of lesions in urinary tract. This section will present the methodology of analysing and diagnosing morphological lesions occurring in upper urinary tracts. The diagnosis of these lesions has been conducted based on analysis of radiograms (urograms) of renal pelvis and upper segments of urinary tracts [3]. In the case of renal radiogram analysis, the main task is to recognise local stenoses or dilations of upper segments of urinary tracts (examples of those images have been presented in Fig. 3) and attempt to define the correct morphology of renal pelvis and renal calyces. Lesions in those structures can suggest the occurrence of renal calculi or deposits

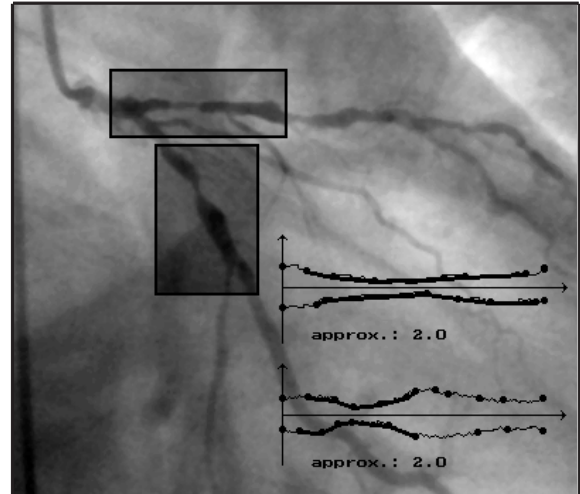


Fig. 2. Figure showing the result of diagnosing pathological lesions in the examined coronary arteries. The graphs visible here present width profiles of the examined arteries section with a structure. Bold lines on diagrams mark the areas diagnosed by syntax analyser as the place where pathological structures occur. These symptoms are of considerable diagnostic importance and they must be taken into consideration in planning further therapy

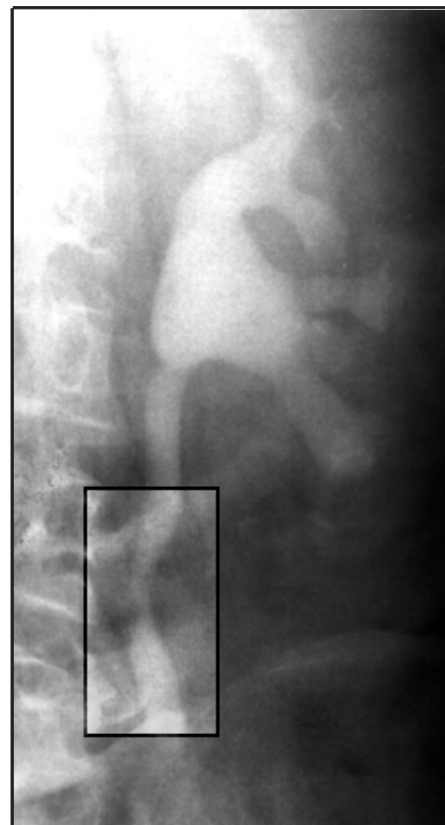


Fig. 3. Image obtained from urography examinations showing upper section of the urinary tract. Visible left renal pelvis and urinary tract section with ureterostenosis (shown in the frames)

that by causing ureter artresia can lead to diseases such as acute extrarenal uraemia or hydronephrosis.

Diagnosing morphological lesions in the form of ureter stenosis or dilations has been conducted with the use of the following attributed grammar:

$G_U = (V_N, V_T, SP, STS)$, where

$V_N = \{\text{SYMPTOM, STENOSIS, DILATATION, H, V, NV}\}$

$V_T = \{h, v, nv\}$ for $h \in (-8^\circ, 8^\circ)$, $v \in (9^\circ, 180^\circ)$, $nv \in (-9^\circ, -180^\circ)$

$STS = \text{SYMPTOM}$

$SP:$

1. SYMPTOM \rightarrow STENOSIS Symptom = Stenosis
2. SYMPTOM \rightarrow DILATATION Symptom = Dilatation
3. STENOSIS \rightarrow NV H V — NV V — NV H
4. DILATATION \rightarrow V H NV — V NV — V H
5. V \rightarrow v — V v $w_{sym} := w_{sym} + w_v$; $h_{sym} := h_{sym} + h_v$
6. NV \rightarrow nv — NV nv
7. H \rightarrow h — H h ...

On the other hand the analysis of the renal pelvis and the renal calyx has been accomplished with the use of G_{EDT} expansive tree grammar generating trees with directed and labelled edges, i.e. the EDT trees [1]. Analysis of such structures has been made with the use of a tree grammar defined to analyse the skeleton morphology of the examined renal pelvis and renal calyx. The skeletonisation has been made with the use of the Pavlidis skeletonisation algorithm, and the tree grammar describing the correct skeletons of renal pelvis and renal calyx will be defined in such a way that the tree root will be defined by the location of the point where larger calyces ramify; its successors will be determined by the ramification points of the 2nd order, that is the beginning of smaller calyces. The last layer of peaks is defined by ramification points of the 3rd order, which is by ramifications occurring if a renal papilla has a concave shape (Fig. 4).

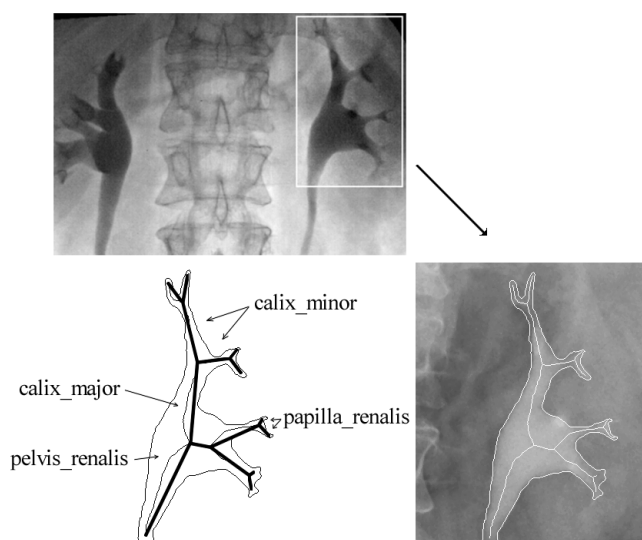


Fig. 4. Urogram of a healthy renal pelvis and calyces together with the skeleton and graph description obtained after skeleton approximation

To define the primitive components used in the tree grammar we can use the approximation algorithm of skeleton ramification in renal pelvis and renal calyx. This allows us to identify every ramification with a single segment, which ends are determined by the ends of the approximated ramification. Next, edge terminal labels are attributed to each of the determined segments, depending on the inclination angle. As a result of the operation we obtain a representation of the analysed object in the form of a tree.

The following graph grammar was used to diagnose morphological changes in renal pelvises: $G_{edt} = (\Sigma, \Gamma, r, P, Z)$, where $\Sigma = \Sigma_N \cup \Sigma_T$ is a set of terminal and non-terminal vertex labels, r is a function which assigns to the graph vertex the number of its consequents, Z is a finite set of starting graphs, Γ — is a set of edge labels, and P — is a set of production.

$\Sigma_T = \{\text{pelvis_renalis, calix_major, calix_minor, papilla_renalis}\}$

$\Sigma_N = \{\text{PELVIS_RENALIS, CALIX_MAJOR, CALIX_MINOR}\}$

$\Gamma = \{x, y, z\}$ for $y \in (-30^\circ, 30^\circ)$, $x \in (30^\circ, 180^\circ)$, $z \in (-30^\circ, -180^\circ)$, $Z = \{\text{PELVIS_RENALIS}\}$

Set of production P is defined in Fig. 5.

The interpretation of disease lesions in the upper urinary tracts has been conducted based on a set of test images composed of 30 X-ray images showing disease lesions. Figure 6 shows example of diagnosing the looked-for lesions in urinary tract. The recognised symptoms are marked with a bold line in the figure.

4.3. Syntactic methods supporting the diagnosis of pancreatitis and pancreas neoplasm.

In this section we shall discuss possibilities to apply methods of structural image analysis and understanding to morphological lesion description in the main pancreatic ducts shown in images obtained in the course of ERCP examinations (Endoscopic Retrograde Cholangiopancreatography) [4]. Those methods are aimed to determine and examine the correctness of morphological shapes of pancreatic ducts and to diagnose such pathological lesions, which demonstrate the existence of neoplasm lesions or inflammation states. The most important symptoms characteristic for pancreas neoplasm are first of all the occurrence of local stenoses or dilations in the main pancreatic duct as well as the occurrence of cysts or cavernous projections on the external edges of the pancreatic duct. Ducts with symptoms of chronic pancreatitis can be characterised by the occurrence of irregular side ramifications of the I, II or III order as well as local stenoses or dilations (Fig. 7).

The analysis of the looked-for morphological lesions has been conducted based on width diagrams obtained during image pre-processing, with the use of context-free attributed grammars of the LR(1)-type. Such grammars, similarly as in the previous tasks, with the appropriate definition of primitive components on width diagrams and

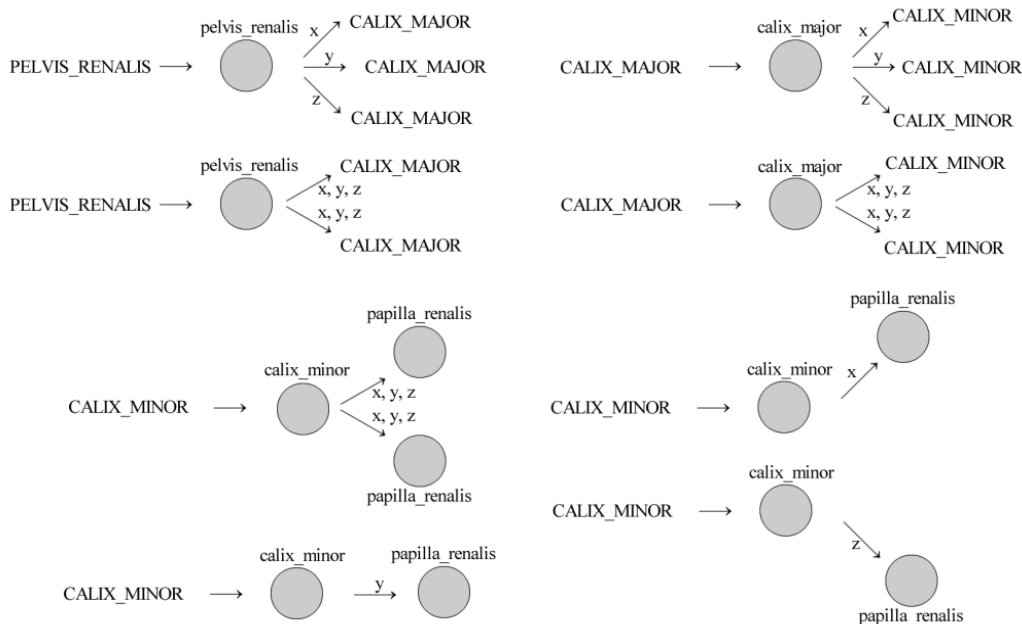


Fig. 5. Set of production P for the graph grammar describing the morphology of renal pelvises

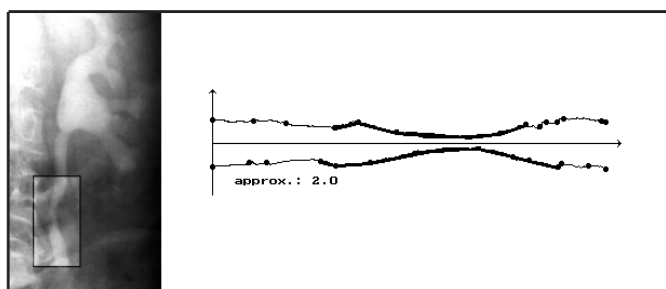


Fig. 6. Result of diagnosing disease symptoms with the use of syntactic methods of pattern recognition in the case of urogram. Circles on width profiles mark the beginnings and ends of segments approximating the external contour of the straightened structure

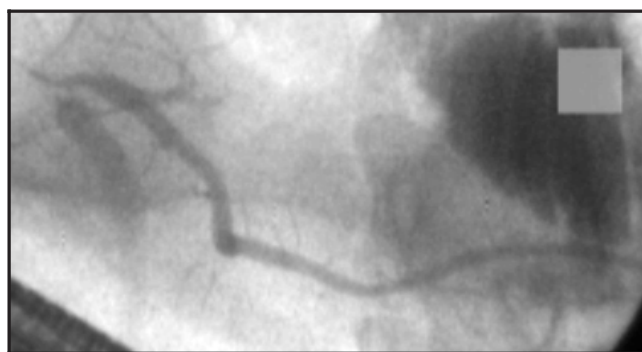

Fig. 7. ERCP image showing pancreatic duct with symptoms of chronic pancreatitis

primitive terminal symbols corresponding to those, allow us to diagnose — on ERCP images — all pathological lesions important from the diagnostic point of view: cysts, strictures, dilations and ramifications.

The use of attributes in this grammar allows, similarly as it did earlier, to determine additional information defining the width and height of the discovered pathology; this can be used for diagnosing numerous uncertain or ambiguous cases.

The following attributed grammar has been used to describe morphological lesions in the examined pancreatic ducts: $G = (V_N, V_T, SP, STS)$, where $V_N = \{LESION, CYST, STENOSIS, DILATATION, BRANCH, P, S, G, I, N, NS, NG, NI, NN\}$ $V_T = \{p, s, ns, g, ng, i, ni, n, nn\}$, where $p \in (-9^\circ, 9^\circ)$, $s \in (9^\circ, 40^\circ)$, $ns \in (-9^\circ, -40^\circ)$, $g \in (40^\circ, 52^\circ)$, $ng \in (-40^\circ, -52^\circ)$, $i \in (52^\circ, 95^\circ)$, $ni \in (-52^\circ, -95^\circ)$,

$n \in (95^\circ, 180^\circ)$, $nn \in (-95^\circ, -180^\circ)$,

$STS = LESION$

$SP:$

1. $LESION \rightarrow CYST \text{ — } STENOSIS$ Lesion=Cyst; Lesion=Stenosis
2. $LESION \rightarrow DILATATION \text{ — } BRANCH$ Lesion=Dilatation; Lesion=Branch
3. $CYST \rightarrow I P NI \text{ — } G P NG \text{ — } I P NG \text{ — } G P NI \text{ — } I S NI \text{ — } G S NG \text{ — } I S NG \text{ — } G S NI \text{ — } I NS NI \text{ — } G NS NG \text{ — } I NS NG \text{ — } G NS NI$
4. $STENOSIS \rightarrow NS S \text{ — } NS G \text{ — } NS P S \text{ — } NS P I \text{ — } NG S \text{ — } NI NS I \text{ — } NI S$
5. $DILATATION \rightarrow S P NG \text{ — } S G NS \text{ — } S NS \text{ — } G NS$
6. $BRANCH \rightarrow I NI \text{ — } I NS \text{ — } I P NI NN \text{ — } I NS NI NN \text{ — } G NI \text{ — } G S NN \text{ — } G P NN \text{ — } G S NI NN \text{ — } S NG \text{ — } S NS NN \text{ — } N G NG NI$

7. $N \rightarrow n - N n \{w_{sym} = w_{sym} + w_n; h_{sym} = h_{sym} + h_n\}$
8. $NN \rightarrow nn - NN nn$
9. $I \rightarrow i - I i \dots$
10. $NI \rightarrow ni - NI ni \dots$
11. $G \rightarrow g - G g \dots$
12. $NG \rightarrow ng - NG ng \dots$
13. $S \rightarrow s - S s \dots$
14. $NS \rightarrow ns - NS ns \dots$
15. $P \rightarrow p \dots$

Despite the complicated grammatical reasoning process, also in this case the syntactic methods of pattern recognition supply practically all information on morphological lesions on the external edges of the pancreatic ducts analysed here.

The recognition of lesions has been conducted based on a set of a few dozen pancreatograms including images with symptoms of chronic pancreatitis and pancreas neoplasm. The overall test set of pancreatograms available included over 100 images of neoplasm and chronic pancreatitis as well as images with healthy pancreatic ducts.

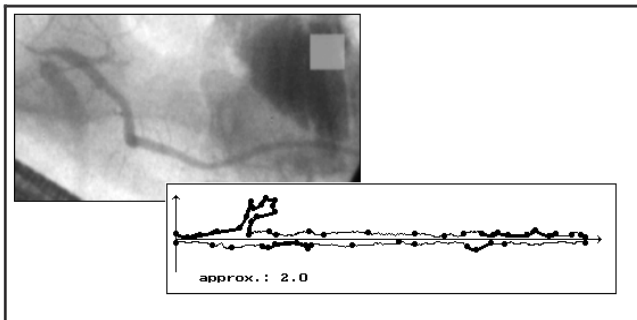


Fig. 8. Pancreatic duct with symptoms of chronic pancreatitis. Result of disease symptoms diagnosis with the use of syntactic methods

The effectiveness of this methods in computer-aided diagnosis of cancerous and inflammatory lesions based on ERCP pictures can be estimated at 90%. This value stands for the percentage of correct recognitions of symptoms defined in the grammar: symptoms in the form of strictures, ramifications and lesions with cyst-like features. Figures 8 present example of recognition of looked-for lesion in ERCP image. The recognised symptoms have been marked with a thick line.

4.4. Analyses of spinal cord images. Another interesting application of syntactic approach to automatic perception analysis is a morphological classification of spinal cord diseases and the diseases of surrounding spinal meninges. This section will show an exemplary analysis of such structures based on an examination of congenital and acquired lesions in the cord structure, visible on images obtained in the magnetic resonance technique (MR).

In the case of analysis of backbone and spinal cord MRI images, the chief objective in the recognition is to detect and diagnose lesions that might evidence a whole range of various disease units: from myelomeningocele,

numerous forms of inflammatory conditions or cerebral or spinal cord ischaemia, to most serious cases of intra- and extradullary tumours. An unambiguous identification of all units with the use of one recognising software is extremely difficult due to rather subtle differences, critical to the correct classification of every one of them. All the same, structural analysis proves to be extremely useful in the specification of the degree of the disease unit development by means of specifying the size of lesions in the cord morphology and by defining the compression of the spinal cord and meninges [8].

The analysis of this structure uses a developed context-free grammar. It allows us to identify symptoms and to draw diagnostic conclusions relating to the inner nature of the visible pathology.

The grammar developed for the analysis of spinal cord images is defined as follows: $G_{sc} = (V_n, V_t, STS, SP)$, where

$V_N = \text{LESION, NARROWING, ENLARGEMENT, H, E, N}$

$V_T = \{h, e, n\}$ for $h \in [-11^\circ, 11^\circ]$, $e \in (11^\circ, 180^\circ)$, $n \in (-11^\circ, -180^\circ)$

$STS = \text{LESION}$

$SP:$

1. $\text{LESION} \rightarrow \text{ENLARGEMENT}$ Lesion=enlargement
2. $\text{LESION} \rightarrow \text{NARROWING}$ Lesion=narrowing
3. $\text{ENLARGEMENT} \rightarrow E H N - E N - E H$
4. $\text{NARROWING} \rightarrow N H E - N E - N H$
5. $H \rightarrow h - h H \quad w_{sym} := w_{sym} + w_h; h_{sym} := h_{sym} + h_h$
6. $E \rightarrow e - e E \dots$
7. $N \rightarrow n - n N \dots$

This grammar permits to detect different forms of stenoses and dilations which may characterize the different disease units (for example neoplasm or inflammation processes). An example of MR image; visible compression on the spinal cord is shown in Fig. 9.

As we can see, the method of cognitive medical image analysis described in this paper allows for a general enhancement of classical image recognition methods targeted at deeper image interpretation. As it was mentioned in the previous sections, there is a great number of images that can be automatically interpreted in this manner. Among them there is also a class of images showing lesions in the central nervous system.

5. Conclusions

The research carried out by the authors into the possibilities of recognising pathological changes in the morphology of coronary arteries and renal pelvises, along with upper parts of the ureter and spine have confirmed the universality of the application of the mathematical linguistic method for the recognition and analysis of morphological changes in medical images. Syntactical methods of pattern recognition and, in particular, the attributed context-free grammars, can be an additional tool supporting early

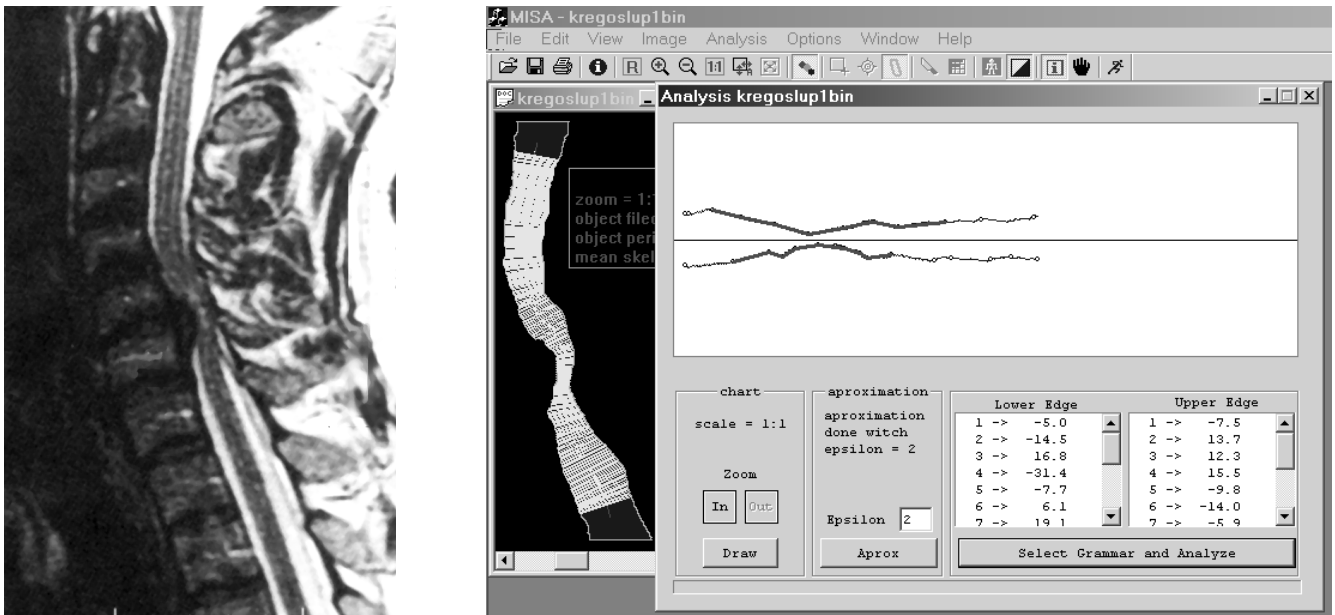


Fig. 9 A,B. The result of the disease symptom recognition and understanding with the application of syntactic methods of pattern recognition. Width profiles indicate the spots where the looked-for lesion was diagnosed. On the left, the original image showing spinal cord with disk herniation. On the right, the recognised place with compression of the thecal sac

diagnosis of chest organ and abdominal cavity diseases. The great efficiency of the presented algorithms makes these methods an unusually useful tool from a practical point of view in the domain of scientific engineering; they allow us to enhance and recognise essential diagnostic features in the analysis of medical images.

Syntactic methods of pattern recognition presented in this paper have an enormous application in the field of artificial intelligence and medical IT, especially in the field of computer medical imaging and computer-aided diagnosis (CAD). Those methods, originating from mathematical linguistics allow not only diagnosing and creating formal and advanced descriptions for complicated shapes of disease symptoms carrying diagnostic information. They can also be used to create intelligent computer systems constructed for the purpose of image perception: allowing to obtain a definition and machine-interpretation of semantic contents of the examined image. Those systems may assist the operation of medical robots widely used in operational theatres of various surgeries. They can constitute also an integral part of CAD systems or intelligent information systems managing pictorial medical data bases located (scattered) in various places.

Acknowledgements. This work was supported by the AGH University of Science and Technology under Grant No. 10.10.120.39.

REFERENCES

- [1] R. Tadeusiewicz and M. Flasiński, *Pattern Recognition*, Polish Scientific Publisher, Warsaw, 1991.
- [2] M. G. Khan, *Heart Disease Diagnosis and Therapy*, Williams & Wilkins, Baltimore, 1996.
- [3] A. K. Mandal and J. Ch. Jennette, (eds.), *Diagnosis and Management of Renal Disease and Hypertension*, Carolina Academic Press, 1994.
- [4] E. M. Bellon, *Radiologic Interpretation of ERCP: a Clinical Atlas*, Medical Examination Publishing Co., New York, 1983.
- [5] F. H. Netter and S. Colacino, *Atlas of Human Anatomy*, Novartis Medical Education, 1998.
- [6] G. Bertrand, J.-Ch. Everat and M. Couprie, "Image segmentation through operators based on topology", *J. Electronic Imaging* 6, 395-405 (1997).
- [7] G. B. J. Mancini (eds.), *Clinical Applications of Cardiac Digital Angiography*, Raven Press, New York, 1988.
- [8] Z. Mikrut, "A method of linear star-sections applied for object separation in ERCP images", in: *Proceedings of International Conference on Image Processing*, pp. 363-366, Lausanne, (1996).
- [9] M. Sonka and J. M. Fitzpatrick, "Handbook of Medical Imaging: Vol. 2- Medical Image Processing and Analysis", *SPIE PRESS* PM80, (2000).
- [10] M. R. Ogiela and R. Tadeusiewicz, "Artificial intelligence structural imaging techniques in visual pattern analysis and medical data understanding", *Pattern Recognition* 36, 2441-2452 (2003).
- [11] M. R. Ogiela and R. Tadeusiewicz, "Advances in syntactic imaging techniques for perception of medical images", *The Imaging Science J.* 49, 113-120 (2001).
- [12] M. R. Ogiela and R. Tadeusiewicz, "Advanced image understanding and pattern analysis methods in medical imaging", in: *Proceedings of the Fourth IASTED International Conference SIGNAL and IMAGE PROCESSING (SIP 2002)*, pp. 583-588, Kauai, Hawaii, (2002).