

The course of the main septum in the sphenoid sinuses — evaluation before the FESS

JOANNA JAWOREK-TROĆ^{1,2}, MICHAŁ ZARZECKI¹, WOJCIECH PRZYBYCIEŃ¹, MARCIN LIPSKI¹,
ANNA CURLEJ-WĄDRZYK³, JOE IWANAGA⁴, JERZY WALOCHA¹, AGATA MAZUREK¹,
ROBERT CHRZAN², ANDRZEJ URBANIK²

¹ Department of Anatomy, Jagiellonian University Medical College, Kraków, Poland

² Department of Radiology, Jagiellonian University Medical College, Kraków, Poland

³ Department of Integrated Dentistry, Institute of Dentistry, Jagiellonian University Medical College, Kraków, Poland

⁴ Department of Neurosurgery, Tulane University, New Orleans, USA

Corresponding author: Michał Zarzecki, M.D.

Department of Anatomy, Jagiellonian University Medical College

ul. Kopernika 12, 31-034 Kraków, Poland

Phone: +48 12 422 95 11; E-mail: michal.zarzecki96@gmail.com

Abstract: The purpose of this study was to determine the course of the main septum (MS) in the sphenoid sinuses in the adult population.

Materials and Methods: 296 patients (147 females, 149 males), who did not present any pathology in the paranasal sinuses, were included in this retrospective analysis of the computed tomography (CT) scans. Spiral CT scanner (Siemens Somatom Sensation 16) was used in order to glean the images of the paranasal sinuses, using standard procedure, in the option Siemens CARE Dose 4D, without using any contrast medium. Secondary reconstructions of the sagittal and frontal planes were obtained using multiplans reconstruction (MPR) tool after obtaining transverse planes in the first instance.

Results: The course of the MS changed the most often from the anterior to the posterior part of the sphenoid sinuses. Such situation took place in 83.78% of the patients, in 32.43% of whom a clear shift to the lateral side was noticed only in the posterior part of the MS: in 18.24% of the patients to the right side, and in 14.19% of the patients to the left side. In 17.57% of the patients the lateral shift was visible in both anterior and posterior parts of the septum, where in 9.46% of the patients it was from the left side to the right, whereas in 8.11% of the patients the shift took place from the right side to the left. The MS had the shape of the letter 'C' in 22.29% of the cases, and 11.82% had the typical shape of the letter 'C,' and in 10.47% of the patients it paralleled the inverted letter 'C' (upside down). Amongst the types of the MS shifting directions the rarest was the MS that resembled the letter 'S' — 11.48% of the patients. In 5.74% of the cases it looked like the typical letter 'S,' and in 5.74% of the cases it was similar to the inverted letter 'S.' Only 16.22% of the cases had the MS that did not change its course nor its shape and ran medially in the sagittal plane from the anterior to the posterior part of the sinuses.

Conclusions: In furtherance of reducing the risk of problems occurring during a surgery in the paranasal sinuses, it is prudent to have a CT scan done in all the patients beforehand, due to the high prevalence of the anatomical variations in the sinuses.

Keywords: main septum (MS), sphenoid sinus, FESS.

Submitted: 04-Apr-2020; **Accepted in the final form:** 23-Jun-2021; **Published:** 30-Jul-2021.

Introduction

The sphenoid sinuses have to this day been a subject to numerous evaluations, as their anatomy is vastly varied and so far no single variant has been assigned as the “typical” appearance of the sphenoid sinuses [1–10].

It goes without a saying that it is imperative for a surgeon to be well acquainted with the anatomy of the operating region and the sphenoid sinuses neighbor with many neurovascular entities, some of which still remain unbeknown to doctors and tutees (e.g. the route of parasympathetic innervation of sphenoid and ethmoid sinuses) [11]. Appropriate preprocedural planning undoubtedly diminishes the risk of surgical iatrogenic complications [12–21].

Understandably, computed tomography (CT) remains the diagnostic method of choice whilst evaluating osseous structures, as it facilitates appropriate distinction of anatomical variants present. Notwithstanding, modern technologies such as virtual dissection tables might come in handy in more complicated evaluations [22], but classical methods still find their use (e.g. lateral cephalometric radiographic assessments in orthodontics) [23].

Functional endoscopic sinus surgery (FESS) is a rapidly developing branch of medicine [24, 25] that has been assigned as the method of choice in surgical treatment of the chronic paranasal sinusitis. Its advantages include namely the possibility to gain access into otherwise troublesome regions and minimized collateral iatrogenic damage in juxtaposition to classical surgeries [25, 26]. Henceforth, the detailed knowledge of the course of the main septum in specific population settings is required from those undertaking said procedures.

Materials and Methods

296 patients (147 females, 149 males) were referred to the Department of Medical Imaging of the University Hospital in Kraków. People over 18 years of age, without any visible / confirmed pathology in the sphenoid sinuses, were included in this retrospective analysis of the paranasal sinuses CT scans. Notwithstanding, the patients who suffered from a head injury or underwent a surgical procedure involving nasal, orbital or cranial basis regions, were excluded from the research group.

Standard procedure in the option Siemens CARE Dose 4D applied while obtaining the CT scans of the paranasal sinuses, using spiral CT scanner (Siemens Somatom Sensation 16). No contrast medium was given to the patients. Sagittal and frontal planes were obtained by using the multiplans reconstruction — MPR tool. Siemens Volume Wizard diagnostic station was used in order to evaluate the data.

The analysis of the obtained images involved the change in the course of the main septum (MS) — the septum regarded as undergoing a course shift was considered as such when it changed its direction in the paranasal sinuses from the median or paramedial to the lateral side (relative to the median line). What is more, the location of the MS basing on its course on the transverse planes obtained via CT scans was studied, involving the classification of the septa into groups.

Results

A deflection in the course of the MS was visible the most often from the anterior to the posterior part of the sphenoid sinuses. Such situation took place in 248 of the cases (120 females, 128 males). In 96 patients (45 females, 51 males) there was a clear shift to the lateral side of only the posterior part of the septum: in 54 of them (23 females, 31 males) to the right side, and in 42 of them (22 females, 20 males) to the left side. 52 patients (23 females, 29 males) had the septum that changed its course to the lateral side in both anterior and posterior parts, but in 28 cases (11 females, 17 males) it occurred from the left side to the right side, and in 24 cases (12 females, 12 males) from the right side to the left side. The MS took the shape of the letter 'C' in 66 patients (33 females, 33 males), 35 of whom had the typical shape of the letter 'C' (17 females, 18 males), and in 31 cases it resembled the inverted letter 'C' (16 females, 15 males). The rarest variant of the MS shifting its course - when it paralleled the letter 'S' — was seen in 34 patients (19 females, 15 males), where in 17 cases it took the shape of the typical letter 'S' (12 females, 5 males), and in 17 patients it resembled the inverted letter 'S' (7 females, 10 males). Only in 48 patients (27 females, 21 males) the MS did not shift its course nor its shape, and ran medially in the sagittal plane from the anterior to the posterior part of the sinuses.

No statistically significant relations were found between the types of the course of the MS and gender ($p = 0.19$, Chi^2 test). The percentage distribution of the aforementioned types is very approximate between both males and females. In 80% of females and 80% of males, the MS had a different course to the medial one. No statistical significance was noticed while analysing the relations of the sorts of the course of the MS and gender ($p = 0.561$, Chi^2 test). In both groups of males and females, the percentage distribution of the course of the MS is very similar (Table 1 and 2, Fig. 1–14).

Table 1. The course of the main septum (MS).

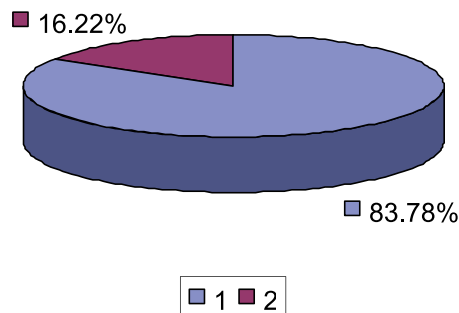
The course of the MS	F	F%	M	M%	F + M	F + M%
Non-medial course	120	81.63%	128	85.91%	248	83.78%
Medial course	27	18.37%	21	14.09%	48	16.22%

MS — main septum, non-medial course — the MS shifting its course from the anterior to the posterior part of the sphenoid sinuses, F — females, F% — the percentage of females, M — males, M% — the percentage of males.

Table 2. The course of the main septum shifting its direction from the anterior to the posterior part of the sphenoid sinuses.

The course of the MS	F	F%	M	M%	F + M	F + M%
Other course	27	18.37%	21	14.09%	48	16.22%
Post. dex.	23	15.65%	31	20.81%	54	18.24%
Post. sin.	22	14.97%	20	13.42%	42	14.19%
Ant. et post. dex.	11	7.48%	17	11.41%	28	9.46%
Ant. et post. sin.	12	8.16%	12	8.05%	24	8.11%
C	17	11.56%	18	12.08%	35	11.82%
Inverted C	16	10.88%	15	10.07%	31	10.47%
S	12	8.16%	5	3.36%	17	5.74%
Inverted S	7	4.76%	10	6.71%	17	5.74%

MS — main septum, F — females, F% — the percentage of females, M — males, M% — the percentage of males, post. dex. — the shift of only the posterior part of the septum to the right, post. sin. — the shift of only the posterior part of the septum to the left, ant. et post. dex. — the shift of both the anterior and posterior parts of the septum to the right, ant. et post. sin. — the shift of both the anterior and posterior parts of the septum to the left, C — the MS in the shape of letter 'C,' inverted C — the MS in the shape of the inverted letter 'C,' S — the MS in the shape of the letter 'S,' inverted S — the MS in the shape of the inverted letter 'S.'

**Fig. 1.** The frequency prevalence of the main septum (MS) course in the total research group.

1 — non-medial course of the MS (83.78%), 2 — medial course of the MS (16.22%).

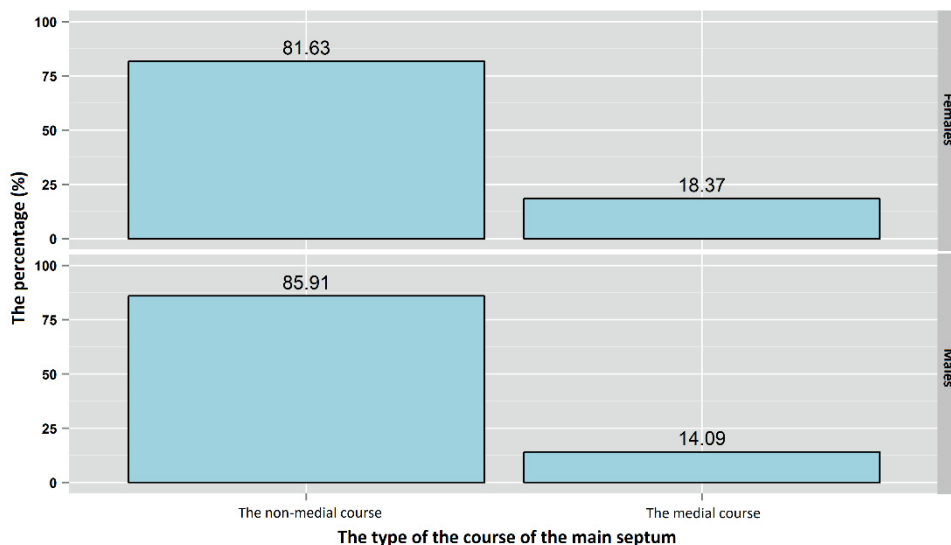


Fig. 2. The percentage distribution of the types of courses of the main septum in females and males.

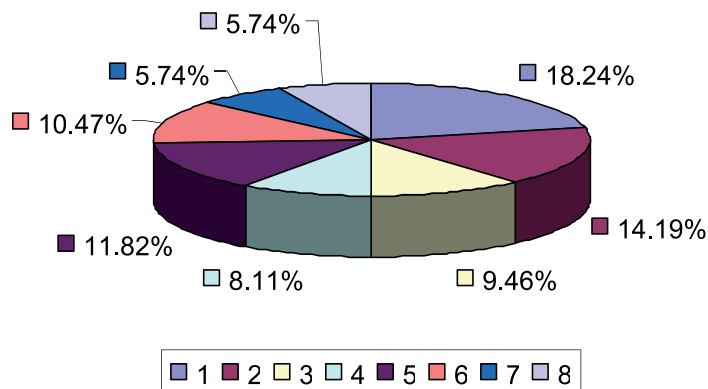


Fig. 3. The frequency prevalence of the course of the MS shifting its direction from the anterior to the posterior part of the sphenoid sinuses in the total research group.

1 — the shift of only the posterior part of the septum to the right (18.24%), 2 — the shift of only the posterior part of the septum to the left (14.19%), 3 — the shift of both anterior and posterior parts of the septum to the right (9.46%), 4 — the shift of both anterior and posterior parts of the septum to the left (8.11%), 5 — the MS in the shape of the letter 'C' (11.82%), 6 — the MS in the shape of the inverted letter 'C' (10.47%), 7 — the MS in the shape of the letter 'S' (5.74%), 8 — the MS in the shape of the inverted letter 'S' (5.74%).

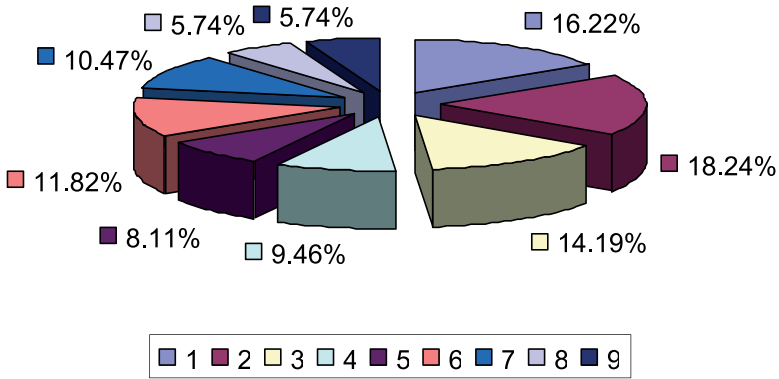


Fig. 4. The frequency prevalence of the course of the main septum (MS) in the total research group — cumulative data.

1 — the medial course (16.22%), 2 — the shift of only the posterior part of the septum to the right (18.24%), 3 — the shift of only the posterior part of the septum to the left (14.19%), 4 — the shift of both anterior and posterior parts of the septum to the right (9.46%), 5 — the shift of both anterior and posterior parts of the septum to the left (8.11%), 6 — the MS in the shape of the letter 'C' (11.82%), 7 — the MS in the shape of the inverted letter 'C' (10.47%), 8 — the MS in the shape of the letter 'S' (5.74%), 9 — the MS in the shape of the inverted letter 'S' (5.74%).

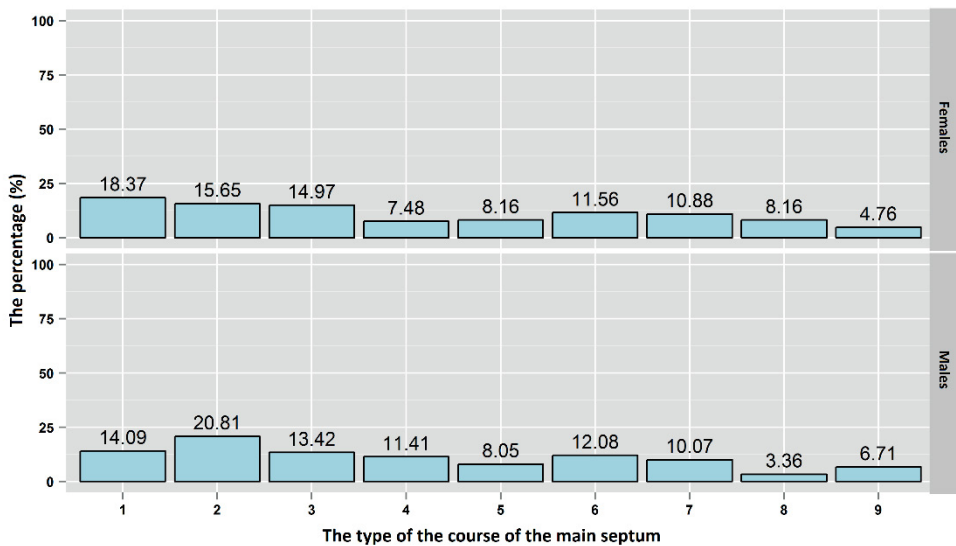


Fig. 5. The percentage distribution of the course types (aforementioned) of the main septum in females and males.

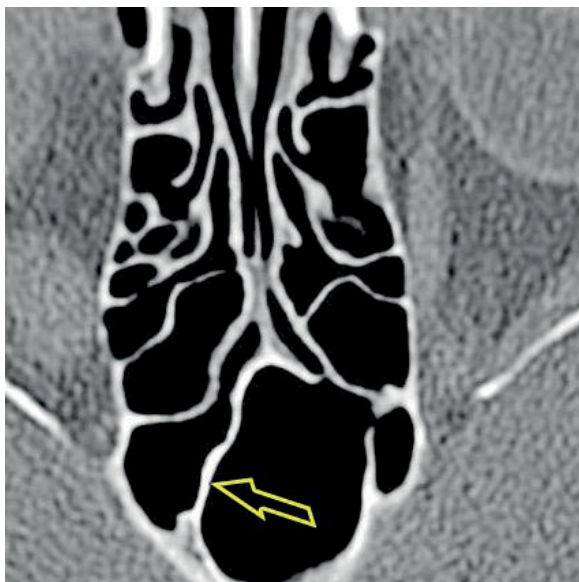


Fig. 6. A CT scan of the paranasal sinuses, transverse plane. The shift of only the posterior part of the septum to the right.

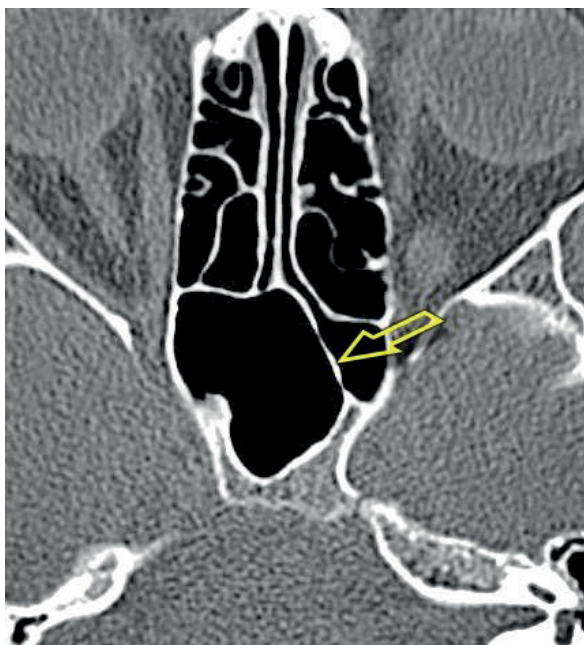

Fig. 7. A CT scan of the paranasal sinuses, transverse plane. The shift of only the posterior part of the septum to the left.

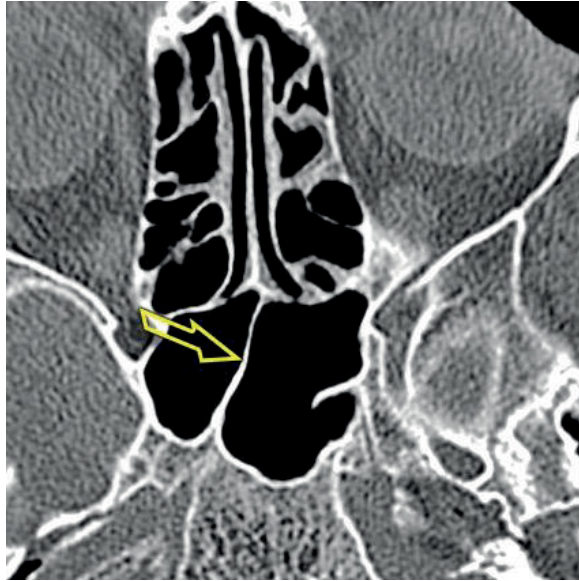

Fig. 8. A CT scan of the paranasal sinuses, transverse plane. The shift of both the anterior and posterior parts of the septum to the right.

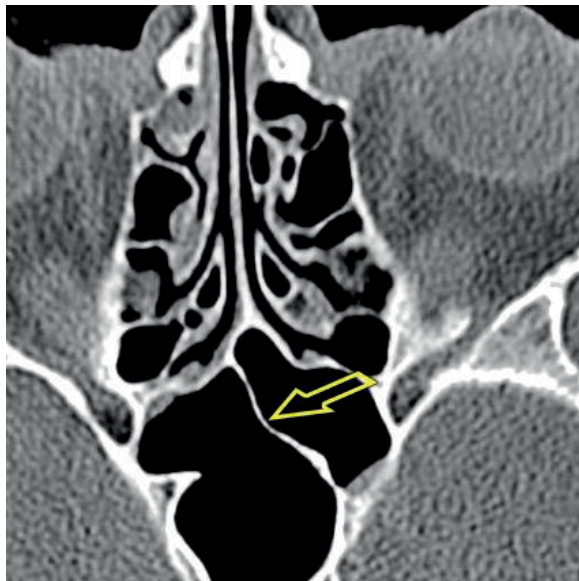


Fig. 9. A CT scan of the paranasal sinuses, transverse plane. The shift of both the anterior and posterior parts of the septum to the left.

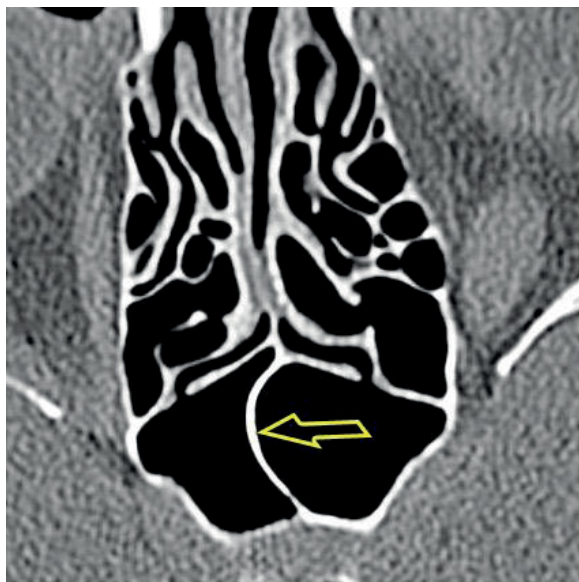

Fig. 10. A CT scan of the paranasal sinuses, transverse plane. The main septum in the shape of the letter 'C.'

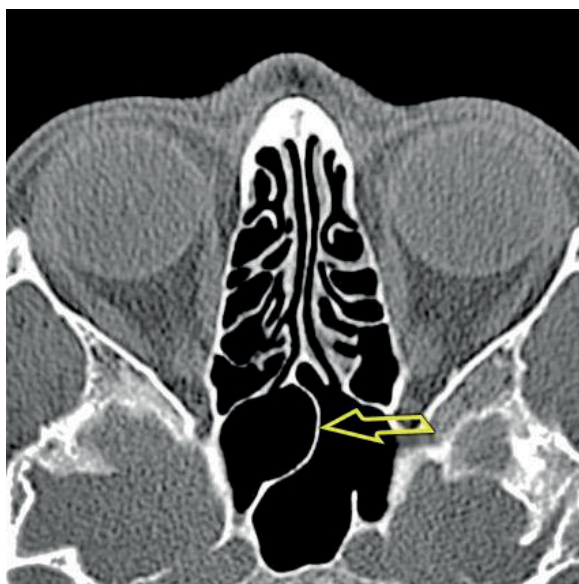


Fig. 11. A CT scan of the paranasal sinuses, transverse plane. The main septum in the shape of the inverted letter 'C.'

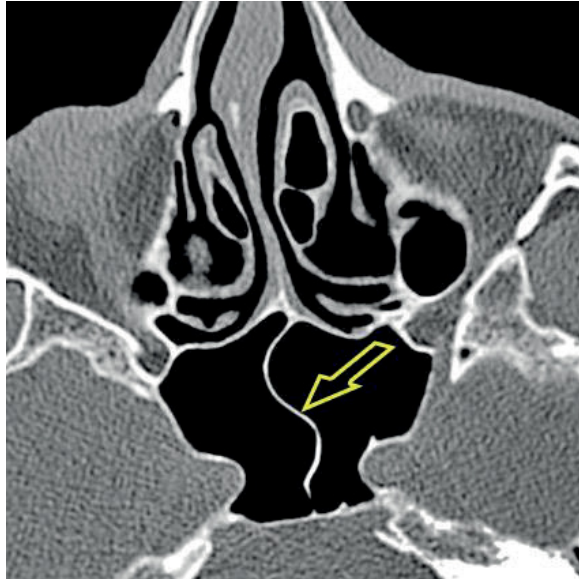


Fig. 12. A CT scan of the paranasal sinuses, transverse plane. The main septum in the shape of the letter 'S.'

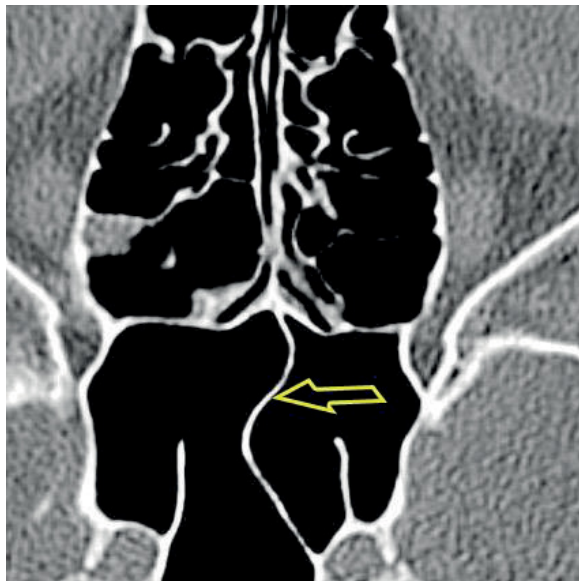


Fig. 13. A CT scan of the paranasal sinuses, transverse plane. The main septum in the shape of the inverted letter 'S.'

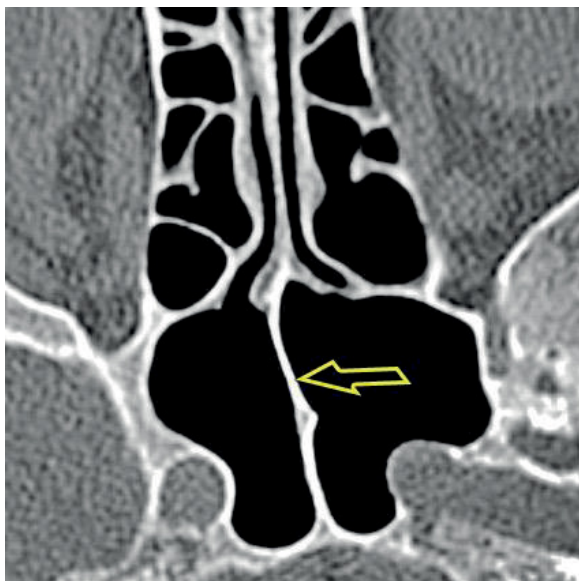

Fig. 14. A CT scan of the paranasal sinuses, transverse plane. The medial course of the main septum.

When the MS shifted its course, in 32 patients (10 females, 22 males) it co-formed a part of the posterior part of one of the sphenoid sinuses: right sphenoid sinus in 21 cases (6 females, 15 males), left sphenoid sinus in 11 cases (4 females, 7 males). The co-formation of the part of the wall of the right sphenoid sinus took place in 10 patients (5 females, 5 males) whose posterior part of the MS shifted to the right and in 11 patients (1 female, 10 males) whose anterior and posterior parts of the MS shifted from the left to the right. The co-formation of the part of the wall of the left sphenoid sinus was visible in all 11 patients (4 females, 7 males) where the posterior part of the MS shifted to the left (Table 3, Fig. 15).

Table 3. Co-formation of a part of the posterior wall of the sinus not dominated by the main septum (MS).

	F	F%	M	M%	F + M	F + M%
RSS MS post. dex.	5	3.4%	5	3.36%	10	3.38%
RSS MS ant. et post. dex.	1	0.68%	10	6.71%	11	3.72%
LSS MS post. sin.	4	2.72%	7	4.7%	11	3.72%
LSS MS ant. et post. sin.	0	0%	0	0%	0	0%

RSS — right sphenoid sinus, MS post. dex. — the course of the MS with the shift of only the posterior part to the right, MS ant. et post. dex. — the course of the MS with the shift of both anterior and posterior parts to the right, LSS — left sphenoid sinus, MS post. sin. — the course of the MS with the shift of only the posterior part to the left, MS ant. et post. sin. — the course of the MS with the shift of both anterior and posterior parts to the left.

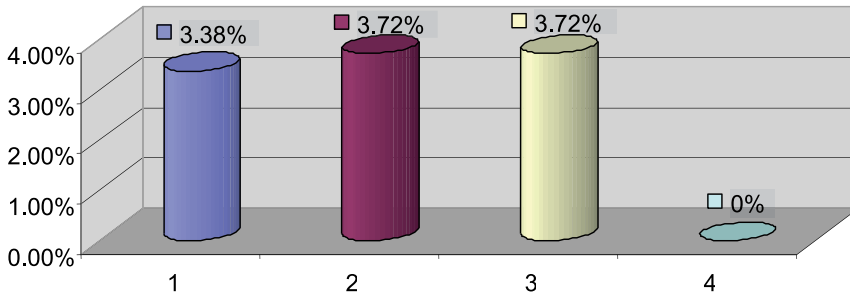


Fig. 15. The frequency of the co-formation of a part of the posterior wall of the sinus not dominated by the main septum (MS) in the total research group.

1 — the co-formation of a part of the posterior wall of the right sphenoid sinus, the course of the MS with the shift of only the posterior part to the right (3.38%); 2 — the co-formation of a part of the posterior wall of the right sphenoid sinus, the course of the MS with the shift of both anterior and posterior parts to the right (3.72%); 3 — the co-formation of a part of the posterior wall of the left sphenoid sinus, the course of the MS with the shift of only the posterior part to the left (3.72%); 4 — the co-formation of a part of the posterior wall of the left sphenoid sinus, the course of the MS with the shift of both anterior and posterior parts to the left (0%).

A statistically significant relation was found between the type of the co-formation of a part of the posterior part of the sinus, or its absence, with gender ($p = 0.036$, χ^2 test). LSS MS ant. et post. sin. variant was not taken into the consideration in this study, since its prevalence was 0% in both females and males. The analysis of the results shows that the RSS MS post. dex., as well as the change's absence appear with the same frequency in both groups: females and males, but the two remaining types are definitely more common in the male group — RSS MS ant. et post. dex. 10 out of 11 cases were males (90.9%) and LSS MS post. sin. 7 out of 11 cases (63.6%) were males (Fig. 16–18).

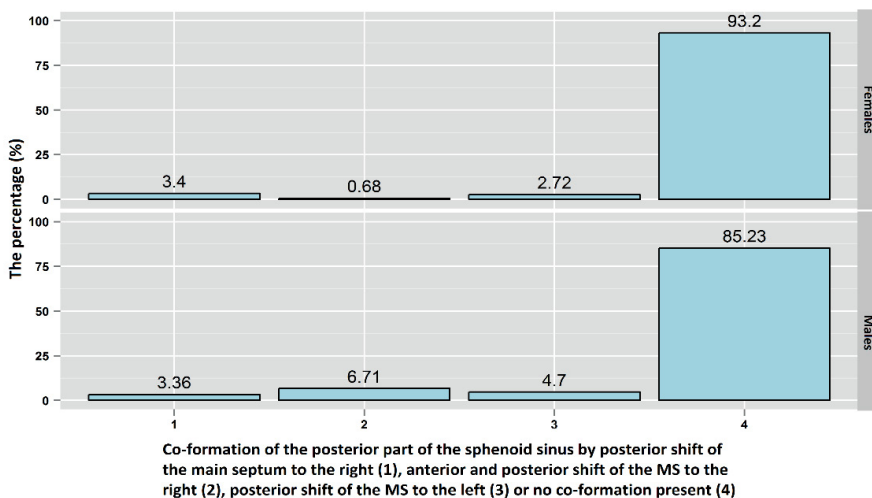


Fig. 16. The percentage distribution of the co-formation of the posterior part of the sinus not dominated by the main septum (MS) or with no apparent shift in the course of the MS in females and males.

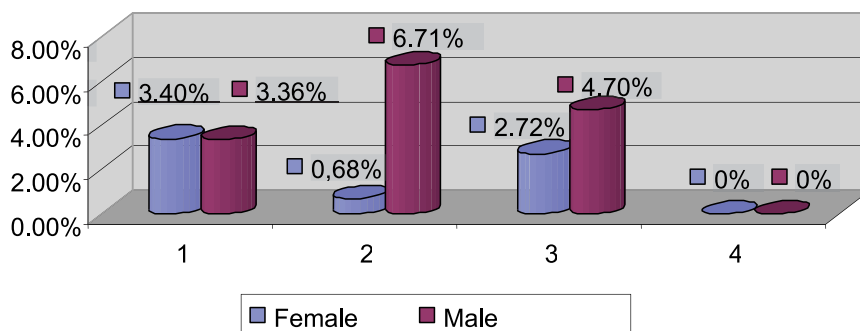


Fig. 17. The frequency of the co-formation of the part of the posterior wall of the sinus not dominated by the main septum (MS) in the total research group — variations between genders.

1 — the co-formation of the part of the posterior wall of the right sphenoid sinus, the course of the MS shifting only in the posterior part to the right (females — 3.40%, males — 3.36%); 2 — the co-formation of the part of the posterior wall of the right sphenoid sinus, the course of the MS shifting in both anterior and posterior parts to the right (females — 0.68%, males — 6.71%); 3 — the co-formation of the part of the posterior wall of the left sphenoid sinus, the course of the MS shifting only in the posterior part to the left (females — 2.72%, males — 4.7%); 4 — the co-formation of the part of the posterior wall of the left sphenoid sinus, the course of the MS shifting in both anterior and posterior parts to the left (females — 0%, males — 0%).

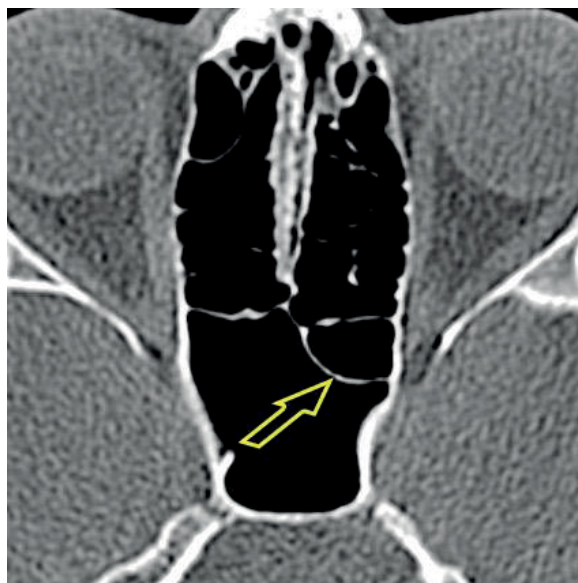


Fig. 18. A CT scan of the paranasal sinuses, transverse plane. The dominant right sphenoid sinus. The course of the main septum shifts to the left and co-forms the posterior wall of the left sphenoid sinus (non-dominant).

Table 4. Cont.

Kayalioglu <i>et al.</i> (180 MRI scans, 77 skulls — dissection study)	64	—	—	—	—	—	—	—	—	—	—	—
Sareen <i>et al.</i> (20 skulls, dissection study)	?											
Tan and Chong (-)	?											
Cope (-)	?											
Yune <i>et al.</i> (-)	?											
Jaworek-Troć <i>et al.</i> (296 CT scans)	16.22	27.7	22.3	18.24	14.19	9.46	8.11	11.82	10.47	5.74	5.74	

The septation of the sphenoid sinus is said to result from the fusion of the trabecular cartilage that forms the sella turcica when ossified and hence could be responsible for the creation of sphenoid sinus septum / septa if the process was to continue caudally towards the diaphysis of the sphenoid bone [40]. Notwithstanding, exact mechanisms and reasons as to why in some individuals there is a single septum and more in others remain eluded.

The clinical importance of the MS during a surgery is that it can represent the midline, should it be found in the midline on the preoperative planning using CT, and hence aid in spatial orientation during the procedure [40]. However, medical professionals need to be vigilant of the possibility of the MS shifting its course, a common variant as shown in the current study.

Conclusions

- The MS changes its course most often from the anterior to the posterior part of the sphenoid sinuses.
- In the majority of the patients studied, the shift of only the posterior part of the septum to the right was visible.
- The great variance in the anatomy of the paranasal sinuses may complicate the surgical procedures undertaken in the aforementioned region, hence a CT scan is advisable in all the patients who are to undergo such an invasive procedure in order to alleviate the surgical risks.

Conflict of interest

None declared.

References

1. Jaworek-Troć J., Zarzecki M., Bonczar A., Kaythampillai L.N., Rutowicz B., Mazur M., Urbaniak J., Przybycień W., Piątek-Koziej K., Kuniewicz M., Lipski M., Kowalski W., Skrzat J., Loukas M., Walocha J.: Sphenoid bone and its sinus — anatomical-clinical review of the literature including application to FESS. *Folia Med Crac.* 2019; 59 (2): 45–59.
2. Jaworek-Troć J., Zarzecki M., Mróz I., Troć P., Chrzan R., Zawiliński J., Walocha J., Urbanik A.: The total number of septa and antra in the sphenoid sinuses — evaluation before the FESS. *Folia Med Crac.* 2018; 58 (3): 67–81.
3. Jaworek-Troć J., Iwanaga J., Chrzan R., Zarzecki J.J., Żmuda P., Pękala A., Tomaszewska I.M., Tubbs R.S., Zarzecki M.P.: Anatomical variations of the main septum of the sphenoidal sinus and its importance during transsphenoidal approaches to the sella turcica. *Transl Res Anat.* 2020; 21: 100079.
4. Jaworek-Troć J., Walocha J.A., Chrzan R., Żmuda P., Zarzecki J.J., Pękala A., Depukat P., Kucharska E., Lipski M., Curlej-Wądrzyk A., Zarzecki M.P.: Protrusion of the carotid canal into the sphenoid sinuses: evaluation before endonasal endoscopic sinus surgery. *Folia Morph.* 2020 (Ahead of print). doi: 10.5603/FM.a2020.0086.
5. Jaworek-Troć J., Walocha J.A., Loukas M., Tubbs R.S., Iwanaga J., Zawiliński J., Brzegowy K., Zarzecki J.J., Curlej-Wądrzyk A., Kucharska E., Burdan F., Janda P., Zarzecki M.P.: Extensive pneumatization of the sphenoid bone — anatomical investigation of the recesses of the sphenoid sinuses and their clinical importance. *Folia Morph.* 2020 (Ahead of print). doi: 10.5603/FM.a2020.0120.
6. Jaworek-Troć J., Zarzecki M., Zamojska I., Chrzan R., Curlej-Wądrzyk A., Iwanaga J., Walocha J., Urbanik A.: The height and type of the main septum in the sphenoid sinuses — evaluation before the fess. *Folia Med Crac.* 2020; 60 (3): 65–74.
7. Jaworek-Troć J., Zarzecki M., Lusina D., Gładysz T., Depukat P., Mazurek A., Twardokęs W., Curlej-Wądrzyk A., Iwanaga J., Walocha E., Chrzan R., Urbanik A.: Incorporation of the sphenoid sinuses' septum / septa in the carotid canal — evaluation before the fess. *Folia Med Crac.* 2020; 60 (4): 65–78.
8. Jaworek-Troć J., Zarzecki M., Zamojska I., Iwanaga J., Przybycień W., Mazur M., Chrzan R., Walocha J.A.: The dimensions of the sphenoid sinuses — evaluation before the functional endoscopic sinus surgery. *Folia Morph.* 2021; 80 (2): 275–282.
9. Jaworek-Troć J., Walocha J.A., Skrzat J., Iwanaga J., Tubbs R.S., Mazur M., Lipski M., Curlej-Wądrzyk A., Gładysz T., Chrzan R., Urbanik A., Zarzecki M.P.: A computed tomography comprehensive evaluation of the ostium of the sphenoid sinus and its clinical significance. *Folia Morph.* 2021 (Ahead of print). doi: 10.5603/FM.a2021.0063.
10. Tesfaye S., Hamba N., Gerbi A., Negeri Z.: Radio-anatomic variability in the sphenoid sinus pneumatization with its relationship to adjacent anatomical structures and their impact upon reduction of complications following endonasal transsphenoidal surgeries. *Transl Res Anat.* 2021; 24: 100126.
11. Carvey M., Baek W.K., Hage R.: Bridging the divide: The widening gap between basic science and clinical research. *Transl Res Anat.* 2021; 24: 100117.
12. Abdullah B.J., Arasaratnam A., Kumar G., Gopala K.: The sphenoid sinuses: computed tomographic assessment of septation, relationship to the internal carotid arteries and sidewall thickness in the Malaysian population. *J HK Coll Radiol.* 2001; 4: 185–188.
13. Eryilmaz A., Ozeri C., Bayiz U., Samim E., Gocmen H., Akmansu H., Safak M.A., Dursun E.: Functional endoscopic sinus surgery (FESS). *Turk J Med Res.* 1993; 11 (5): 221–223.
14. Haetinger R.G., Navarro J.A.C., Liberti E.A.: Basilar expansion of the human sphenoidal sinus: an integrated anatomical and computerized tomography study. *Eur Radiol.* 2006; 16: 2092–2099.
15. Kantarci M., Karasen R.M., Alper F., Onbas O., Okur A., Karaman A.: Remarkable anatomic variations in paranasal sinus region and their clinical importance. *Eur J Radiol.* 2004; 50: 296–302.
16. Kazkayasi M., Karadeniz Y., Arıkan O.K.: Anatomic variations of the sphenoid sinus on computed tomography. *Rhinology.* 2005; 43: 109–114.

17. Keast A., Yelavich S., Dawes P., Lyons B.: Anatomical variations of the paranasal sinuses in Polynesian and New Zealand European computerized tomography scans. *Otolaryngol Head Neck Surg.* 2008; 139: 216–221.
18. Mafee M.F., Chow J.M., Meyers R.: Functional endoscopic sinus surgery: anatomy, CT screening, indications and complications. *AJR.* 1993; 160: 735–744.
19. Mutlu C., Unlu H.H., Goktan C., Tarhan S., Egrilmez M.: Radiologic anatomy of the sphenoid sinus for intranasal surgery. *Rhinology.* 2001; 39: 128–132.
20. Perez-Pinas I., Sabate J., Carmona A., Catalina-Herrera C.J., Jimenez-Castellanos J.: Anatomical variations in the human paranasal sinus region studied by CT. *J Anat.* 2000; 197: 221–227.
21. Terra E.R., Guedes F.R., Manzi F.R., Boscolo F.N.: Pneumatization of the sphenoid sinus. *Dentomaxillofacial Radiology.* 2006; 35: 47–49.
22. Stecco A., Boccafoschi F., Falaschi Z., Mazzucca G., Carisio A., Bor S., Valente I., Cavalieri S., Carriero A.: Virtual dissection table in diagnosis and classification of Le Fort fractures: A retrospective study of feasibility. *Transl Res Anat.* 2020; 18: 100060.
23. Sinha S., Shetty A., Nayak K.: The morphology of Sella Turcica in individuals with different skeletal malocclusions — a cephalometric study. *Transl Res Anat.* 2020; 18: 100054.
24. Becker D.G.: The minimally invasive, endoscopic approach to sinus surgery. *Journal of Long-Term Effects of Medical Implants.* 2003; 13 (3): 207–221.
25. Bogusławska R.: Badanie zatok przynosowych metoda tomografii komputerowej dla celów chirurgii endoskopowej. Warszawa 1995.
26. Anusha B., Baharudin A., Philip R., Harvinder S., Mohd Shaffie B., Ramiza R.R.: Anatomical variants of surgically important landmarks in the sphenoid sinus: a radiologic study in Southeast Asian patients. *Surg Radiol Anat.* 2015; 37: 1182–1190.
27. Tan H.K.K., Ong Y.K.: Sphenoid sinus: an anatomic and endoscopic study in Asian cadavers. *Clinical Anatomy.* 2007; 20: 745–750.
28. Battal B., Akay S., Karaman B., Hamcan S., Akgun V., Sari S., Bozlar U., Tasar M.: The relationship between the variations of sphenoid sinus and nasal septum. *Gulhane Tip Derg.* 2014; 56: 232–237.
29. Hammer G., Radberg C.: The sphenoidal sinus. *Acta Radiologica.* 1961; 56 (6): 401–422.
30. Elwany S., Yacout Y.M., Talaat M., El-Nahass M., Gunied A., Talaat M.: Surgical anatomy of the sphenoid sinus. *The Journal of Laryngology and Otology.* 1983; 97: 227–241.
31. Kinnman J.: Surgical aspects of the anatomy of the sphenoidal sinuses and the sella turcica. *J Anat.* 1977; 124 (3): 541–553.
32. Lupascu M., Comsa Gh., Zainea V.: Anatomical variations of the sphenoid sinus — a study of 200 cases. *ARS Medica Tomitana.* 2014; 2 (77): 57–62.
33. Lee J.-Ch., Chuo P.-I., Hsiung M.-W.: Ischemic optic neuropathy after endoscopic sinus surgery: a case report. *Eur Arch Otorhinolaryngol.* 2003; 260: 429–431.
34. Dundar R., Kulduk E., Soy F.K., Aslan M., Kilavuz A.E., Sakarya E.U., Yazici H., Eren A.: Radiological evaluation of septal bone variations in the sphenoid sinus. *J Med Updates.* 2014; 4 (1): 6–10.
35. Kayalioglu G., Erturk M., Varol T.: Variations in sphenoid sinus anatomy with special emphasis on pneumatization and endoscopic anatomic distances. *Neurosciences.* 2005; 10 (1): 79–84.
36. Sareen D., Agarwail A.K., Kaul J.M., Sethi A.: Study of sphenoid sinus anatomy in relation to endoscopic surgery. *Int J Morphol.* 2005; 23 (3): 261–266.
37. Tan H.M., Chong V.F.H.: CT of the paranasal sinuses: normal anatomy, variations and pathology. *CME Radiology.* 2001; 2 (3): 120–125.
38. Cope V.Z.: The internal structure of the sphenoidal sinus. *J Anat.* 1917; 51 (2): 127–136.
39. Yune H.Y., Holden R.W., Smith J.A.: Normal variations and lesions of the sphenoid sinus. *AM J Roentgenol Radium Ther Nucl Med.* 1975; 124 (1): 129–138.
40. Hayashi Y., Kita D., Iwato M., Fukui I., Sasagawa Y., Oishi M., Tachibana O., Nakada M.: Midline dural filum of the sellar floors: its relationship to the septum attachment to the sellar floor and the ossification in the sphenoid sinus. *Clin Neurol Neurosurg.* 2016; 147: 53–58.