

DOI 10.24425/pjvs.2021.139982

Original article

# Effect of kebar grass extract (*Biophytum petersianum* Klotzsch) on histopathological changes in liver of mice offspring from the parent exposed to carbofuran during lactation period

N.A. Yulitasari<sup>1</sup>, S. Hidanah<sup>1</sup>, Widjiati<sup>1</sup>, V.F. Hendrawan<sup>2</sup>, E.M. Luqman<sup>1</sup>

<sup>1</sup>Department of Veterinary Science Faculty of Veterinary Medicine Universitas Airlangga  
Kampus C Unair, Jalan Mulyorejo Surabaya 60115 Indonesia,

<sup>2</sup>Department of Animal Reproduction Faculty of Veterinary Medicine, Universitas Brawijaya,  
Jl. MT. Haryono No.169, Ketawanggede, Lowokwaru, Kota Malang, 65144 Indonesia

## Abstract

This study aims to determine the potential of Kebar grass extract in reducing the impact of liver damage in mice offspring (*Mus musculus*) from parent exposed to carbofuran during lactation period. 42 lactation mice (*Mus musculus*) used in the study were divided into seven groups, each group consisting of six mice. Carbofuran, Kebar grass extract, and vitamin C are administered orally on days 1 to 14 after birth. This group consisted of K (aquadest), P1 (carbofuran 1/4 LD<sub>50</sub> 0.0125 mg/day), P2 (carbofuran 1/8 LD<sub>50</sub> 0.00625 mg/day), P3 (Kebar grass extract 3.375 mg (0.2 ml) + carbofuran 1/4 LD<sub>50</sub>), P4 (Kebar grass extract 3.375 mg (0.2 ml) + carbofuran 1/8 LD<sub>50</sub>), P5 (vitamin C 5 mg (0.2 ml) + carbofuran 1/4 LD<sub>50</sub>), and P6 (vitamin C 5 mg (0.2 ml) + carbofuran 1/8 LD<sub>50</sub>). On the 15<sup>th</sup> day after birth, mice were sacrificed and their liver taken for microscopic examination with *hematoxylin and eosin* staining. The scoring data were analyzed using Kruskal-Wallis and Mann-Whitney test. The result showed significant different ( $p < 0.05$ ) among the treatment groups. Mean of P4 in degeneration is (1.13), necrosis (1.13) and inflammation (0.73), while the mean of P6 in degeneration is (2.20), necrosis (2.73) and inflammation (1.93). The conclusion of this research is giving Kebar grass extract is more effective in reducing degeneration, necrosis and inflammatory cell's infiltration than vitamin C in mice offspring (*Mus musculus*) from parent exposed to carbofuran during lactation period.

**Key words:** pesticide stress, carbofuran, Kebar grass extract, lactation period, liver

## Introduction

Carbofuran (2,3-dihydro-2, 2-dimethyl, -7benzofuranyl methyl carbamate) is an insecticide from the carbamate group. Carbofuran is most often used and causes many poisoning incidents in humans and animals (Deepak et al. 2011). Otieno et al. (2010) reported that the intensive use of carbofuran can leave residues, contamination, and poison the environment thereby reducing the population of various useful animals.

Oral administration of carbofuran has been shown to stimulate *Reactive Oxygen Species* (ROS) (Luqman et al. 2019). Cell damage by carbofuran is associated with the formation of ROS or free radicals in the body (Jaiswal et al. 2013). Target organ damaged due to the effects of carbofuran is the brain, liver, muscles, and heart (Gupta et al. 1994, Kaur et al. 2006, Rai et al. 2009).

The liver is the largest gland and is a vital organ for humans and animals. The liver is an organ that plays a role in the process of detoxifying the waste products of the metabolism of food substances, drugs, and toxic substances that enter the body (Gibson 2003). The presence of toxic substances carried in the portal vein bloodstream can cause the liver cells around the portal vessels to experience the most cell damage. The impact of ROS triggers congestion, infiltration of inflammatory cell (inflammation) and necrosis of the liver (Gbadegesin et al. 2013).

The lactation period is a critical period for the development of postpartum individuals because the function and organ systems are still developing so they are more susceptible to disease (Chin et al. 2017). Metabolites in milk coming from insecticides in lactating mothers allow the transmission of toxic substances to children (Keegan et al. 2009). Milk that passes through the digestive system will undergo a process of absorption and will be distributed to all organs of the body including the liver. Therefore toxic substances in milk are thought to cause liver cell damage.

Kebar grass contains flavonoids (Unitly and Inara 2011) and phenolic compounds (Trisetiyono et al. 2019) which function as antioxidants. Phenolic compounds as antioxidants have mechanisms as reducers, free radical scavengers, metal binders, and prevent the formation of singlet oxygen (Sayuti and Rina 2015).

## Materials and Methods

The research procedure was conducted according to the permit by testing the code of ethics committee of experimental animals with the number 1. KE.107.06.2019 at the Faculty of Veterinary Medicine, Universitas Airlangga. The research design used was

a completely randomized design (CRD) with seven groups. The experimental animals used were mother and mice offspring (*Mus musculus*) Balb/C at the lactation period, aged 0-14 days. The treatment group consisted of seven groups: P0, P1, P2, P3, P4, P5, P6

## Materials

The tools used in this study were plastic cages and wire mesh for experimental animal cages, drinking containers, sonde needles, test tubes, and 3 ml syringes. Equipment for the making manufacture of liver histopathological preparations includes object glasses, cover glasses, automatic tissue processor, water bath, hot plate, microtome, and blade. Histology of the liver was assessed using a camera and an Olympus® CX-4 microscope.

The materials used in this study were female mice (*Mus musculus*), Kebar grass (*Biophytum petersianum Klotzsch*) in dry form obtained from the district of Kebar, Papua and the extraction was carried out in the Testing Service Unit of the Faculty of Pharmacy, Universitas Airlangga. Carbofuran (2,3-dihydro-2,2-dimethyl-7-benzofuranol N-methylcarbamate 98%) was obtained from Aldrich Chemistry with Bellstain Registry number 1428746 (Product of USA). Pellet feed for mice, aquadest as a solvent for carbofuran, carbofuran, and vitamin C, drinking water, husks as cage mats, ether, 10% formalin, and alcohol.

## Methods

Mice were divided into seven groups, each group consisting of six mice that were: group consisted of K (aquadest), P1 (carbofuran  $1/4 LD_{50}$  0.0125 mg/day), P2 (carbofuran  $1/8 LD_{50}$  0.00625 mg/day), P3 (Kebar grass extract 3.375 mg (0.2 ml) + carbofuran  $1/4 LD_{50}$ ), P4 (Kebar grass extract 3.375 mg (0.2 ml) + carbofuran  $1/8 LD_{50}$ ), P5 (vitamin C 5 mg (0.2 ml) + carbofuran  $1/4 LD_{50}$ ), and P6 (vitamin C 5 mg (0.2 ml) + carbofuran  $1/8 LD_{50}$ ). On the 15<sup>th</sup> day after birth, mice offspring were sacrificed and their liver taken for microscopic examination with hematoxylin and eosin staining.

## Histopathological preparations

Counting the number of hepatocyte damaged for each treatment group was done in five different fields of view in each histopathological preparation. Microscopic observation of hepatocytes in histopathological preparations was done using a 400X magnification of Olympus® CX-23 microscope. Observations were made by counting the number of degenerations,

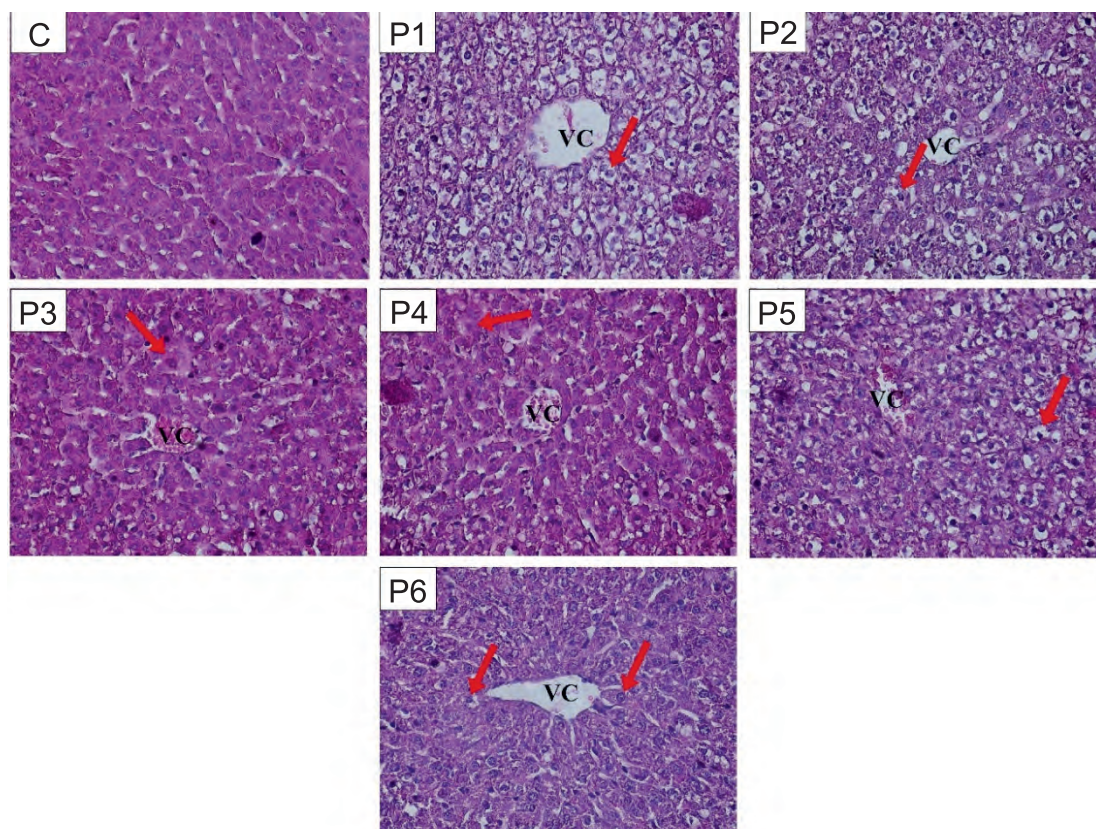


Fig. 1. Comparison of the microscopic picture of hepatocyte degeneration in mice offspring with H&E staining, magnification 400x. The arrows indicate cell degeneration (➡), VC (Vena Centralis). K (aquadest), P1 (carbofuran 1/4 LD<sub>50</sub> 0.0125 mg/day), P2 (carbofuran 1/8 LD<sub>50</sub> 0.00625 mg/day), P3 (Kebar grass extract 3.375 mg (0.2 ml) + carbofuran 1/4 LD<sub>50</sub>), P4 (Kebar grass extract 3.375 mg (0.2 ml) + carbofuran 1/8 LD<sub>50</sub>), P5 (vitamin C 5 mg (0.2 ml) + carbofuran 1/4 LD<sub>50</sub>), and P6 (vitamin C 5 mg (0.2 ml) + carbofuran 1/8 LD<sub>50</sub>). x400

necrosis and infiltration of inflammatory cells. Calculation of each field of view in one preparation is summed, then averaged, then statistically analyzed.

### Data Analysis

The data that has been collected were then analyzed using the SPSS 22 (Statistical Product and Service Solutions) program, namely the Kruskal-Wallis test with the Mann-Whitney posttest.

### Results

Microscopic observation of the histology of the liver of the mice offspring from lactating mothers exposed to carbofuran given Kebar grass extract which was compared with mice offspring from lactating mothers who were given carbofuran and vitamin C. The scoring results of the liver of the mice offspring showed degeneration, necrosis, and infiltration of inflammatory cells.

The presence of degeneration is marked by the size of the enlarged cell cytoplasm and cloudy cytoplasm due to the presence of vacuoles (Fig. 1). Observation

of necrosis was seen in the presence of cell nuclei that had picnosis, cariorexis, and karyolysis (Fig. 2). Observation infiltration of inflammatory cell (inflammation) was seen in the Kiernan triangle area (Table 1 and Fig. 3).

### Discussion

Degeneration, necrosis and infiltration of inflammatory cell are manifestations of injury. Degeneration is a reaction to a lesion that is reversible, meaning that the cell can return to normal if it is able to overcome the injury, but if the cell is unable to overcome the injury, it will continue to the point of no return where the cell experiences death or necrosis which is irreversible (Arimbi et al. 2015). The results of this study indicate that giving Kebar grass extract as an antioxidant is better in reducing the level of degeneration, necrosis, and infiltration of inflammatory cell in mice hepatocytes compared to giving vitamin C. This is related to the antioxidant content of Kebar grass which contains compounds such as flavonoids, vitamin A and vitamin E. Antioxidants can work more effectively if given



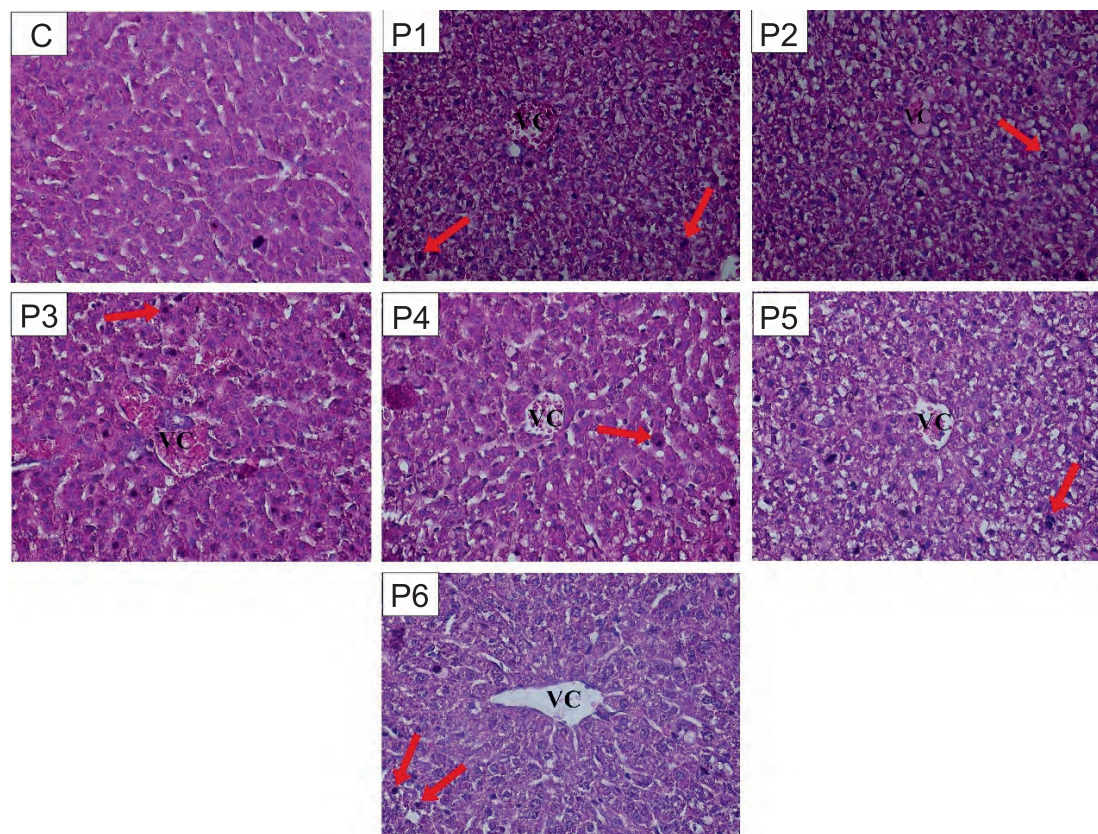


Fig. 2. Comparison of the microscopic appearance of hepatocyte necrosis in mice offspring with H&E staining, magnification 400x. Arrows indicate cell necrosis (➔), VC (Vena Centralis). K (aquadest), P1 (carbofuran 1/4 LD<sub>50</sub> 0.0125 mg/day), P2 (carbofuran 1/8 LD<sub>50</sub> 0.00625 mg/day), P3 (Kebar grass extract 3.375 mg (0.2 ml) + carbofuran 1/4 LD<sub>50</sub>), P4 (Kebar grass extract 3.375 mg (0.2 ml) + carbofuran 1/8 LD<sub>50</sub>), P5 (vitamin C 5 mg (0.2 ml) + carbofuran 1/4 LD<sub>50</sub>), and P6 (vitamin C 5 mg (0.2 ml) + carbofuran 1/8 LD<sub>50</sub>). x400

Table 1. Average score of hepatic degeneration, necrosis and inflammatory cell's infiltration of mice offspring from mothers given the extract of Kebar grass (*Biophytum petersianum Klotzsch*) and vitamin C exposed to carbofuran.

Treatments	Score Degeneration (Mean ± SD)	Score Necrosis (Mean ± SD)	Score infiltration of inflammatory cell (Mean ± SD)
K (control)	0.00±0.00 <sup>a</sup>	0.00±0.00 <sup>a</sup>	0.00±0.00 <sup>a</sup>
P1 (carbofuran 1/4 LD <sub>50</sub> )	4.73±0.23 <sup>g</sup>	4.60±0.00 <sup>f</sup>	4.33±0.23 <sup>g</sup>
P2 (carbofuran 1/8 LD <sub>50</sub> )	4.06±0.23 <sup>f</sup>	3.93±0.23 <sup>e</sup>	3.80±0.00 <sup>f</sup>
P3 (Kebar grass extract 3.375 mg + carbofuran 1/4 LD <sub>50</sub> )	1.67±0.23 <sup>c</sup>	2.06±0.23 <sup>c</sup>	1.40±0.00 <sup>c</sup>
P4 (Kebar grass extract 3.375 mg + carbofuran 1/8 LD <sub>50</sub> )	1.13±0.11 <sup>b</sup>	1.13±0.11 <sup>b</sup>	0.73±0.11 <sup>b</sup>
P5 (vitamin C + carbofuran 1/4 LD <sub>50</sub> )	3.00±0.40 <sup>e</sup>	3.13±0.46 <sup>d</sup>	3.13±0.46 <sup>e</sup>
P6 (vitamin C + carbofuran 1/8 LD <sub>50</sub> )	2.20±0.00 <sup>d</sup>	2.73±0.23 <sup>d</sup>	1.93±0.23 <sup>d</sup>

Note: different notations a, b, c, d, e, f and g (superscript) in the same column indicate a significant difference ( $p < 0.05$ )

in combination (Addor 2017). The combination of primary antioxidants (flavonoids) and phenolic antioxidants (vitamins A and E) is able to provide maximum results in overcoming oxidative stress (Sayuti and Rina 2015). The antioxidant ability activity of flavonoids is higher than vitamin C (Prior and Cao 2000). Giving solely vitamin C causes this antioxidant not to work optimally. Flavonoids are antioxidants that are included

in primary antioxidants. Flavonoids can increase endogenous antioxidant function by interfering with free radical-producing systems. One of the mechanisms of flavonoids as anti-oxidants is directly cleaning radicals so that they can prevent cell damage. caused by free radicals. Direct scavenging of flavonoids results in stable substances, because the activity of the flavonoid group is high so that it can bind reactive oxygen



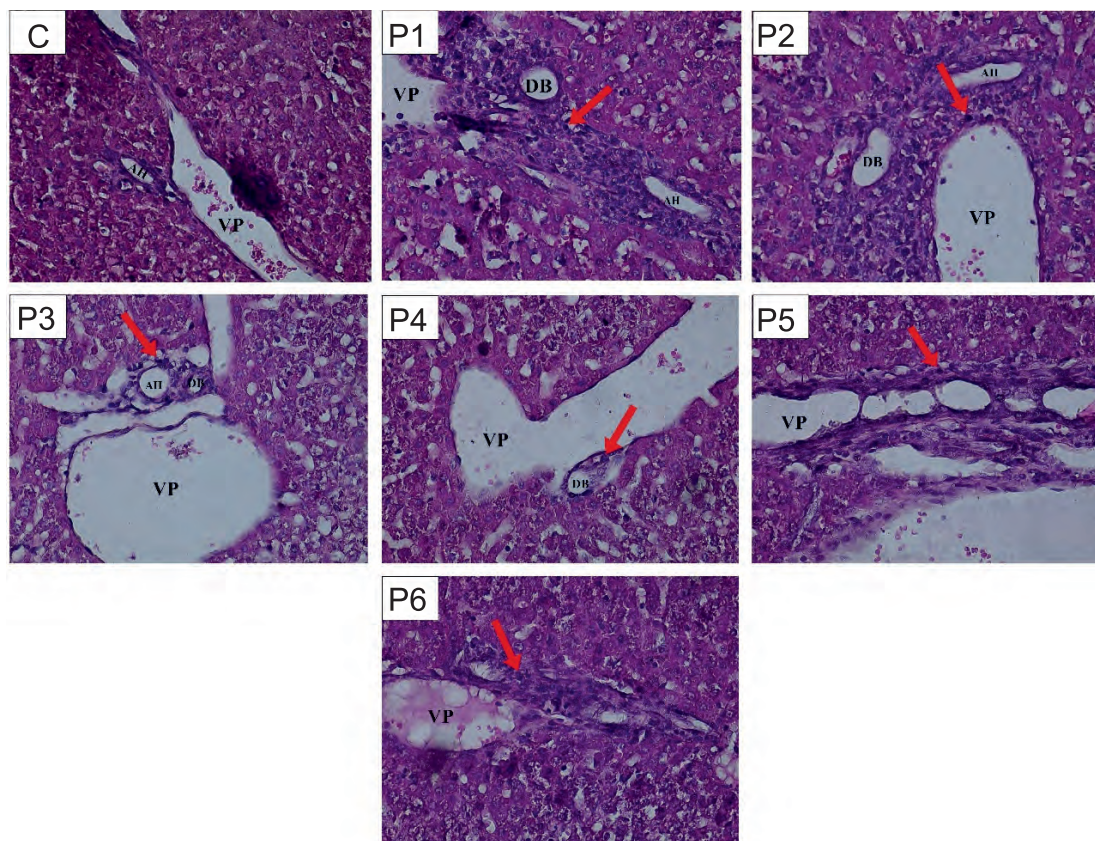


Fig. 3. Comparison of the microscopic appearance of infiltration of inflammatory cells in mice offspring hepatositis (*Mus musculus*) with H&E staining, magnification 400x. Arrows indicate infiltration of inflammatory cells (→), PV (Portal Vein), DB (Ductus Billiverus), AH (Arteria Hepatica). K (aquadest), P1 (carbofuran 1/4 LD<sub>50</sub> 0.0125 mg/day), P2 (carbofuran 1/8 LD<sub>50</sub> 0.00625 mg/day), P3 (Kebar grass extract 3.375 mg (0.2 ml) + carbofuran 1/4 LD<sub>50</sub>), P4 (Kebar grass extract 3.375 mg (0.2 ml) + carbofuran 1/8 LD<sub>50</sub>), P5 (vitamin C 5 mg (0.2 ml) + carbofuran 1/4 LD<sub>50</sub>), and P6 (vitamin C 5 mg (0.2 ml) + carbofuran 1/8 LD<sub>50</sub>). x400

species (Panche et al. 2016). The mechanism of vitamin A activity as an antioxidant is by reacting with free radicals and causing them to become stable. Tocopherol or vitamin E is the first line of defense against the peroxidation process of polyunsaturated fatty acids (General Adaptation Syndrome, GAS) and acts as a chain-breaking antioxidant in membranes (Maslachah et al. 2008). Based on the results of our research, it can be concluded that giving the extract of Kebar grass (*Biophytum petersianum* Klotzsch) is more effective in reducing degeneration, necrosis and inflammatory cell's infiltration than vitamin C in mice offspring (*Mus musculus*) from parent exposed to carbofuran during lactation period.

### Acknowledgements

The authors express sincere thanks to the Ministry of Research, Technology and Higher Education of the Republic of Indonesia for funding the research, and the Dean of Faculty of Veterinary Medicine, Universitas Airlangga for providing all necessary facilities and funds in conducting this research work.

### References

- Addor FA (2017) Antioxidants in dermatology. *An Bras Dermatol* 92: 356–362.
- Arimbi A, Azmijah, Darsono R, Plumerriastuti H, Widiyatno TV, Legowo D (2015) *Veterinary general pathology textbook*. 2<sup>nd</sup> ed., Airlangga University Press, Surabaya.
- Chandra D, Tripathi UN, Srivastava S, Amit Swaroop A (2011) Carbofuran induced biochemical toxicity in mice; Protective role of *Momordica charantia*. *Eur J Exp Biol* 1: 106-112.
- Chin AM, Hill DR, Aurora M, Spence JR (2017) Morphogenesis and maturation of embryonic and postnatal intestine. *Semin Cell Dev Biol* 66: 81-93.
- Gbadegesin MA, Owumi SE, Akinseye V, Odunola OA (2013) Evaluation of hepatotoxicity and clastogenicity of carbofuran in male Wistar rats. *Food Chem Toxicol* 5: 115-119.
- Gibson J (2003) *Modern physiology and anatomy for nurses*. 2<sup>nd</sup> ed., Jakarta, EGC Press.
- Gupta RC (1994) Carbofuran Toxicity. *J Toxicol Environ Health* 43: 383-418.
- Jaiswal SK, Siddiqi NJ, Sharma B (2013) Carbofuran induced oxidative stress in rat heart: Ameliorative effect of vitamin C. *ISRN Oxid Med*: 11: 1-10.
- Kaur M, Sandhir R (2006) Comparative effects of acute and chronic carbofuran exposure on oxidative stress and

- drug-metabolizing enzymes in liver. *Drug Chem Toxicol* 29: 415-421.
- Keegan J, Whelan M, Danaher M, Crooks S, Sayers R, Anastasio A, Elliott C, Brandon D, Furey A, O'Kennedy R (2009) Bensimidazole carbamate residues in milk: Detection by Surface Plasmon Resonance-biosensor, using a modified QuEChERS (Quick, Easy, Cheap, Effective, Rugged and Safe) method for extraction. *Anal Chim Acta* 654: 111-119.
- Luqman EM, Sudiana, IK, Darmanto W, Achmad AB, Widjiati (2019) Mouse (*Mus musculus*) embryonic cerebral cortex cell death caused by carbofuran insecticide exposure. *J Vet Res* 63: 413-421.
- Maslachah L, Sugihartuti R, Kurniasanti R (2008) The inhibition of vitamin E ( $\alpha$ -tocopherol) antioxidant to superoxide radical reactive oxygen species ( $O_2^{\cdot-}$ ) production on the white rat (*Rattus norvegicus*) stressed by an electric shock. *Vet J* 24: 22-26.
- Otieno PO, Lalah JO, Virani M, Jondiko IO, Schram KW (2010) Carbofuran and its toxic metabolites provide forensic evidence for furadan exposure in vultures (*Gyps africanus*) In Kenya. *Bull Environ Contam Toxicol* 84: 536-544.
- Panche AN, Diwan AD, Chandra SR (2016) Flavonoids: an overview. *J Nutr Sci* 5: 1-15.
- Prior RL, Cao G (2000) Antioxidant phytochemicals in fruits and vegetables; diet and health implications. *Hortic Sci* 35: 588-592.
- Rai DK, Rai PK, Rizvi SI, Watal G, Sharma B (2009) Carbofuran-induced toxicity in rats: protective role of vitamin C. *Exp Toxicol Pathol* 61: 531-535.
- Sayuti K, Rina Y (2015) Natural and synthetic antioxidants. 1<sup>st</sup> ed., Andalas University Press, Padang.
- Trisetiyono Y, Pramono N, Hidayat ST, Widjiati (2019) The differences of malondialdehyde serum level, expression of tumor necrosis factor alpha and vascular endothelial growth factor, and the area of endometriotic implants in administration of Kebar grass extract (*Biophytum petersianum*) and green tea extract (*Camelia sinensis*) to mice. *Trad Med J* 24: 169-177.
- Unitly AJA, Inara C (2011) Potential of kebar grass (*Biophytum Petersianum Klotzsch*) in improving reproductive performance. Proceedings of the National Seminar Universitas Patimura, Ambon, Indonesia, pp 329-333.