

DOI 10.24425/pjvs.2022.141813

Original article

Expression of the highly pathogenic porcine reproductive and respiratory syndrome virus (HP-PRRSV) in various types of cells in thymic tissues

Q. Liu, Y.-Y. Yu, H.-Y. Wang

Nanchong Key Laboratory of Disease Prevention, Control and Detection in Livestock and Poultry,
Nanchong Vocational and Technical College, Nanchong 637131, China

Abstract

Thymus, an important central immune organ in pigs, is the site of T lymphocyte development and maturation and an important target organ for infection and replication of various pathogens. Highly pathogenic porcine reproductive and respiratory syndrome virus (HP-PRRSV) infection results in severe thymic atrophy in piglets. This study aimed to explore the effects of HP-PRRSV on the thymic structure of piglets to elucidate the pathogenesis of thymic atrophy induced by HP-PRRSV. In this study, histopathological techniques and immunofluorescence double staining techniques were used to analyze thymic tissues infected by HP-PRRSV to explore the structural changes of thymus caused by the viral infection and its target cell types. An antibody of cluster of differentiation (CD) 3 (CD3), CD20, CD80, or calgranulin + calprotectin was applied to identify T cells, B cells, dendritic cells (DCs), and macrophages, respectively. The results indicated that a variety of cell components in the thymic tissue were diffusely damaged after viral infection. In the infected thymic tissue, CD80- or calgranulin + calprotectin-labeled cells supported the HP-PRRSV infection, whereas CD3-labeled T cells and CD20-labeled B cells did not support the viral infection. The results showed that HP-PRRSV caused the reduction of visible cell components in the thymic tissue, and the virus attacked CD80- and calgranulin + calprotectin-positive cells (such as DCs and macrophages) in the thymic tissue, which played an important role in the pathogenesis of thymus atrophy. These results lay the foundation for elucidating the immunosuppression of piglets after infection with HP-PRRSV.

Key words: pig, thymus, highly pathogenic porcine reproductive and respiratory syndrome virus, immunofluorescence double labeling method, target cells

Introduction

The thymus is an important immune organ in pigs and is located in the anterior part of the mediastinum in the chest cavity and can extend to both sides of the pig's trachea. It is pink in color and is developed in piglets but gradually shrinks as the pig matures (Wang et al. 2020a). Histologically, the thymus is divided into lobules by connective tissue and comprises the cortex, medulla, and the interface between the medulla and the cortex. The thymus contains epithelial cells, macrophages, dendritic cells (DCs), lymphocytes, and plasma cells (Pearse 2006, Bikhet et al. 2020, Wang et al. 2020a, Wang et al. 2020b). Thymus function is closely related to immunity and is an important place for T cell differentiation and maturation (Pearse 2006, Bikhet et al. 2020, Wang et al. 2020a, Wang et al. 2020b).

Porcine reproductive and respiratory syndrome (PRRS, commonly known as blue-ear disease) is an acute and highly contagious viral disease in pigs that is caused by the porcine reproductive and respiratory syndrome virus (PRRSV) (Wensvoort et al. 1991, An et al. 2020). Based on the traditional classification system, PRRSV is divided into two genotypes, namely, European (Type 1) and North American (Type 2) (Han et al. 2017). The most prevalent PRRSV in China is the North American genotype (Han et al. 2017). According to literature reports, based on the *ORF5* gene, the North American type PRRSV is further divided into nine lineages, of which, lineages 1, 3, 5, and 8 are more widely prevalent in China (Liu et al. 2019a). The NADC34-like strain of PRRSV from lineage 1 has been reported in the United States, China, and Peru in recent years (Zhang et al. 2018, Ramirez et al. 2019). The continuous emergence and evolution of new strains increases the diversity and complexity of PRRSV, which make the effective prevention and control of PRRS more difficult. Among the strains of PRRSV, the highly pathogenic porcine reproductive and respiratory syndrome (HP-PRRS), which is caused by PRRSV variant strains (characterized by 30 [1 + 29] amino acid discontinuous loss in the *Nsp2* gene), is highly pathogenic to pigs and has been persistently prevalent in China for more than 10 years; thus, these strain has been the focus of efforts for the prevention and control of PRRSV (Zhou et al. 2008): The HP-PRRS virus (HP-PRRSV) can infect pigs of any age and is characterized by severe respiratory symptoms and thymic atrophy in piglets (Lunney et al. 2016, Wang et al. 2020a, Obradovic et al. 2021). According to research reports, compared with the classic strain of PRRSV CH-1a, the HuN4 strain of HP-PRRSV infects porcine alveolar macrophages (PAMs) in the lung tissue and causes them to undergo apoptosis and induce immunosuppression,

and these results were closely related to that of the more severe histopathological damage in peripheral immune organs and lungs of pigs infected with the HuN4 strain of HP-PRRSV (Jung et al. 2009, Wang et al. 2014, Wang et al. 2016). These results suggest that the severe immunosuppression caused by HP-PRRSV infection in pigs is an important cause of pathological injury. Therefore, the objective of this study was to investigate the target cell types infected by HP-PRRSV in the thymic tissue. Findings obtained from this study could facilitate the understanding of the pathogenesis of HP-PRRSV-induced thymus atrophy.

Materials and Methods

Reagents

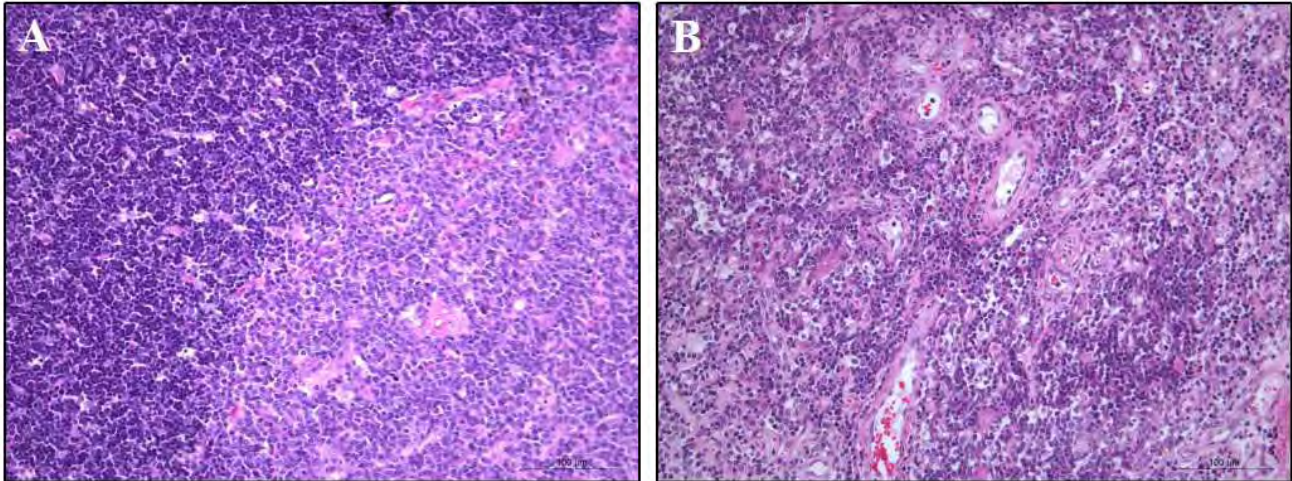
The formaldehyde solution, methanol solution, xylene, anhydrous ethanol, and other reagents were purchased from Guangdong Guanghua Chemical Factory (Guanghua, Guangdong, China). The 5% skimmed milk solution was purchased from Biyuntian Biotechnology Company (Biyuntian Biotechnology, Beijing, China). The rabbit anti-cluster of differentiation (CD) 80 (CD80) antibody was purchased from Abcam (Abcam, Cambridge, UK). The mice anti-PRRSV-N protein-specific antibody was purchased from RTI Corporation (RTI, Anyang-City, Korea). The anti-CD20 antibody (Abcam), anti-CD3 antibody (Abcam), and mouse anti-calgranulin + calprotectin antibody were purchased from Abcam. Alexa Fluor 488-labeled sheep anti-rabbit antibody (Abcam) and Alexa Fluor 647-labeled sheep anti-mouse antibody (Abcam) were purchased from Abcam Company. The 4',6-diamidino-2-phenylindole (DAPI) solution, hematoxylin dye and 0.1% Tween20 solution were purchased from Sigma-Aldrich (Sigma-Aldrich, St. Louis, MO, USA).

Sample collection

The tissue samples used in this experiment were thymic tissues of pigs collected by the research group before 2018. Tissue samples were stored in a 10% formaldehyde solution and were used for the histopathological and immunofluorescence experiments.

Histopathological assay

The thymic tissue was dehydrated in gradient alcohol (70%, 80%, 90%, and 95% alcohol) and treated for 2 h, followed by treatment with anhydrous ethanol I and anhydrous ethanol II for 1 h each. After transparent treatment of xylene I and xylene II (treatment time: 1 h), paraffin dipping (treatment time: 2 h for melted paraffin I and paraffin II; 58-60°C) and embedding treatment,



Supplementary Fig. 1. Histopathological observation of the thymus: (A) normal structures were observed in the thymus from uninfected pigs; and (B) decreased cell components were observed in the thymus from highly pathogenic porcine reproductive and respiratory syndrome virus (HP-PRRSV)-infected pigs. Hematoxylin and eosin (HE) staining. Scale bar = 100 μ m.

tissue blocks were prepared. Using a rotary microtome (Leica, Germany), the blocks were cut into 3-5 μ m thick sections, that were flattened on water at 45°C and then attached to slides coated with anti-release agent. The slices were roasted at 60°C (treatment time: 2 h), dewaxed by xylene I and xylene II (treatment time: 15 min), hydrated with gradient alcohol (100%, 95%, 85%, 70%, and 50% alcohol, consecutively), and stored in distilled water for 5 min. Then, the rehydrated sections were subjected to hematoxylin-eosin staining, placing them in hematoxylin dye solution for 5 min and washing the sections with water for a while. Next, diluted hydrochloric acid differentiation (treatment time: 1-5 s) was performed, followed by water washing for anti-blue staining (treatment time: ~20 min), gradient alcohol treatment (to create conditions for eosin alcohol dye solution staining in 50%, 70%, 85%, and 95% alcohol; treatment time: 2 min each), 0.5% alcohol eosin staining (treatment time: 30 s), and continuous gradient alcohol treatment (95% alcohol I, 95% alcohol II, and 95% alcohol III; treatment time: 2 min). The tissue sections were treated with anhydrous ethanol I and anhydrous ethanol II for 5 min, xylene I and xylene II for 5 min each, and were dried and sealed with neutral gum. The pathological changes of the tissue sections were observed under a light microscope (Carl Zeiss, Heidenheim, Germany).

Immunofluorescence assay

The tissue slices were baked in an oven at 60°C for 2 h, dewaxed with xylene I and II (treatment time: 20 min), treated with 1:1 xylene alcohol solution (treatment time: ~2 min), hydrated with gradient alcohol (from high to low concentration, including 95%, 85%, 70%, and 50% alcohol; treatment time: 5 min each).

After rehydration, the tissue sections for antigen repair were treated with citric acid buffer (pH 6.0, boiling) for 6 min, cooled at room temperature, and then blocked with 5% fetal bovine serum (Biyuntian Biotechnology) at room temperature for 30 min. The tissue sections were further incubated with the primary antibody (antibody dilution ratio: 1:50 to 1:200) at 4°C overnight, incubated with the secondary antibody (antibody dilution ratio: 1:500) at room temperature for 1 h, stained with DAPI at room temperature for 10 min, and sealed with the mounting medium (Biyuntian Biotechnology). The tissue sections were later photographed using a laser confocal microscope (Carl Zeiss).

Results

Histopathological observation

In the control group, the structure of the thymus was clear and had no pathological lesions (Supplementary Fig. 1A). In the HP-PRRSV-infected group, the thymic lobules were atrophied, and the number of lymphocytes in the lobules decreased (Supplementary Fig. 1B). In the thymus parenchyma, most cells exhibited necrotic lesions such as nuclear concentration and fragmentation (Supplementary Fig. 1B).

Dendritic cells and macrophages are the main target cells of HP-PRRSV infection

To further clarify the target cells infected by the virus, we used the immunofluorescence double labeling method to identify the virus-infected cell types in the HP-PRRSV-infected thymic tissue. As shown in Fig. 1 and Fig. 2, CD3- or CD20-positive cells were stained red, the nuclei were blue, HP-PRRSV-infected cells

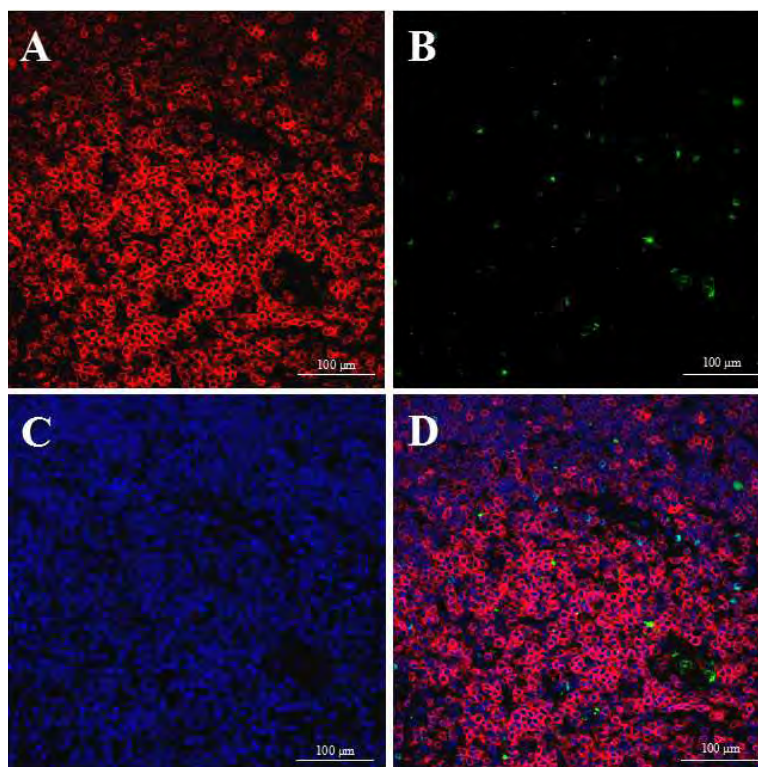


Fig. 1. Target cell types for highly pathogenic porcine reproductive and respiratory syndrome virus (HP-PRRSV) infection in thymus were detected by immunofluorescence double labeling method, and the regions were labeled with anti-cluster of differentiation (CD) 3 (CD3) antibody (in red) and anti-PRRSV-N antibody (in green). The nuclei were stained with 4',6-diamidino-2-phenylindole (DAPI; in blue): (A) CD3-positive cells; (B) HP-PRRSV-positive cells; (C) DAPI; (D) merged image. Scale bar = 100 μm.

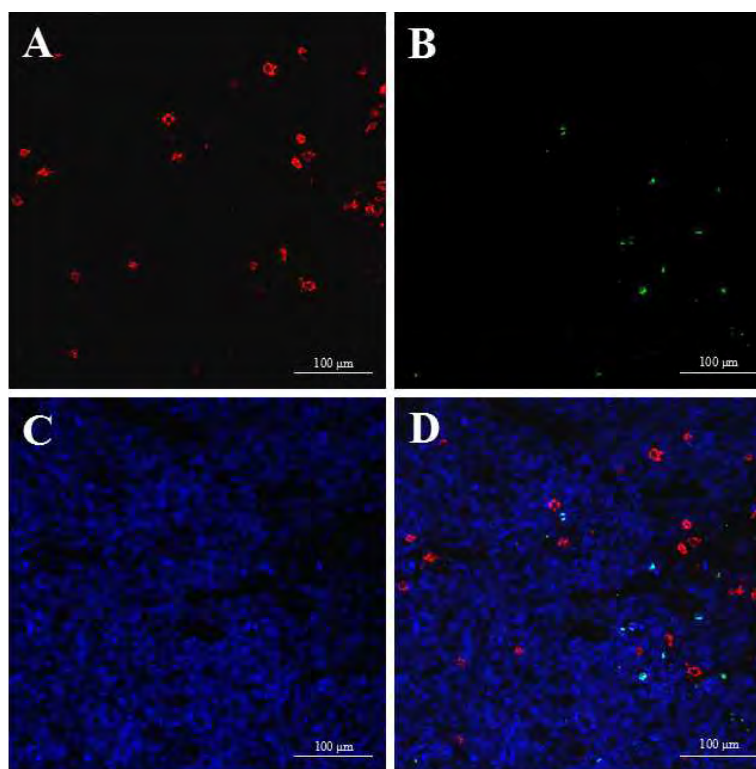


Fig. 2. Target cell types for highly pathogenic porcine reproductive and respiratory syndrome virus (HP-PRRSV) infection in thymus were detected by immunofluorescence double labeling method, and the regions were labeled with anti-cluster of differentiation (CD) 20 (CD20) antibody (in red) and anti-PRRSV-N antibody (in green). The nuclei were stained with 4',6-diamidino-2-phenylindole (DAPI; in blue): (A) CD20-positive cells; (B) HP-PRRSV-positive cells; (C) DAPI; (D) merged image. Scale bar = 100 μm.

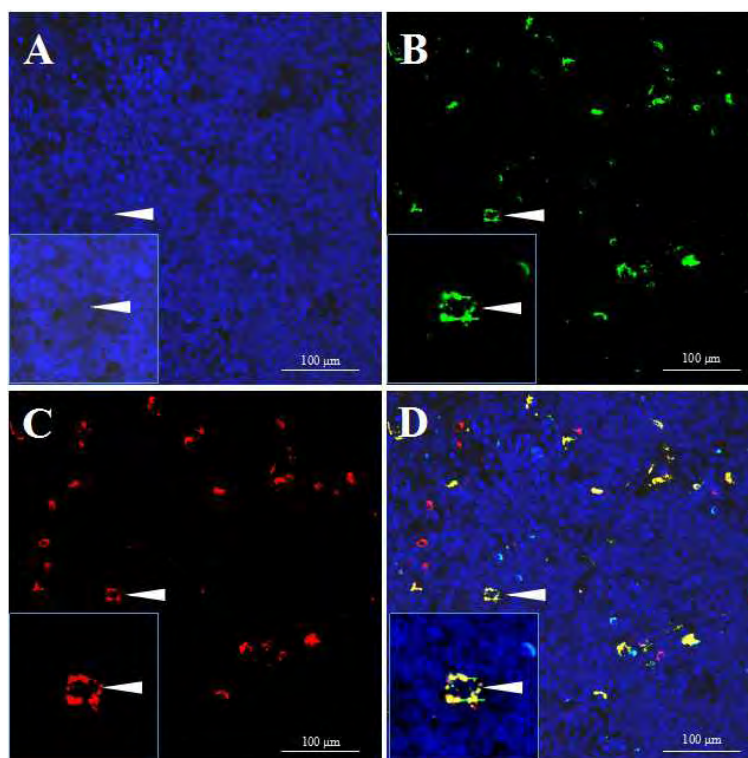


Fig. 3. Cell types of highly pathogenic porcine reproductive and respiratory syndrome virus (HP-PRRSV) infection in the thymus were detected by immunofluorescence double labeling method. The regions were labeled with anti-cluster of differentiation (CD) 80 (CD80) (in red) and anti-PRRSV-N antibody (in green). The nuclei were stained with 4',6-diamidino-2-phenylindole (DAPI; in blue): (A) CD80-positive cells; (B) HP-PRRSV-positive cells; (C) DAPI; (D) merged image (arrow indicates double-positive cell). Scale bar = 100 μ m.

were stained green, and no positive cells marked by red and green were found. As shown in Fig. 3 and Fig. 4, CD80 or calgranulin + calprotectin-positive cells were stained red, the nuclei were blue, HP-PRRSV-infected cells were stained green, and red and green co-labeled positive cells were seen.

Discussion

The thymus is the most important central immune organ of pigs, and is also a site susceptible to pathogens such as HP-PRRSV (Wang et al. 2020a). In this study, the pathological characteristics of thymic atrophy induced by HP-PRRSV in piglets were taken as the breakthrough point, and the target cell types infected by HP-PRRSV in the thymic tissue were identified by double immunofluorescence method. Then, the pathogenesis of thymic atrophy induced by HP-PRRSV was discussed. Histopathological observations showed that HP-PRRSV infection caused a decrease in the visible components of thymic tissue cells, such as the number of lymphocytes in the lobules, resulting in lobule atrophy. Most of the cells in the parenchyma showed nuclear concentration and fragmentation and were engulfed by proliferative macrophages. The results indicate that the occurrence of thymic atrophy is closely

related to the diffuse injury of multiple cell components in thymic tissues infected with HP-PRRSV. It has been reported that HP-PRRSV infection in piglets causes the apoptosis of CD3+ cells in the thymic tissue (Wang et al. 2020a). In addition, studies have confirmed that various damaged cells in the peripheral blood and thymic tissues of pigs infected with HP-PRRSV release a large number of inflammatory mediators (tumor necrosis factor alpha; interleukin (IL)-6, IL-1 β , etc.) and apoptosis-related factors (caspase-3, caspase-8, caspase-9, etc.) (Li et al. 2017), and these up-regulated factors also promote and aggravate tissue damage such as that in the thymus (Wang et al. 2020a). These results confirm that thymic atrophy is related to the apoptosis of thymus cells.

The HP-PRRSV causes an acute infectious disease involving multiple systems of the whole body, with the thymus being one of the severely affected organs (Han et al. 2017, Wang et al. 2020a). The type, number, and distribution of HP-PRRSV-infected cells in the thymus of piglets are of great significance for the occurrence and development of HP-PRRS. In previous studies, CD14+ cells were identified by immunofluorescence staining of PRRSV-infected piglet thymus (Wang et al. 2020a). CD14 is primarily distributed on the surface of monocytes, macrophages, and DCs (Sampath et al.

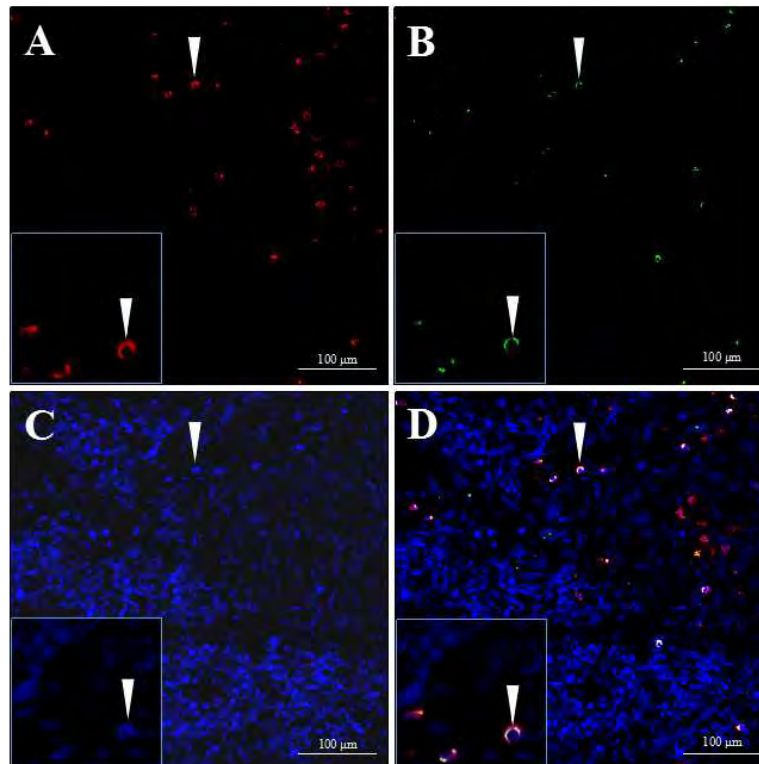


Fig. 4. Cell types of highly pathogenic porcine reproductive and respiratory syndrome virus (HP-PRRSV) infection in the thymus were detected by immunofluorescence double labeling method. The regions were labeled with anti-calgranulin + calprotectin antibody (in red) and anti-PRRSV-N antibody (in green). The nuclei were stained with 4',6-diamidino-2-phenylindole (DAPI; in blue): (A) calgranulin + calprotectin-positive cells; (B) HP-PRRSV-positive cells; (C) DAPI; and (D) merged image (arrow indicates double-positive cell). Scale bar = 100 μ m.

2018, Wu et al. 2019). In this study, the target cell type attacked by HP-PRRSV was further identified as calgranulin + calprotectin- or CD80-positive cells by double immunofluorescence method. Calgranulin + calprotectin and CD80 mainly mark macrophages and DCs. These results are consistent with the progress of basic studies on HP-PRRSV target cells, which have shown that: (1) Heparin sulfate, also known as heparin-like protein as PRRSV receptor, is expressed in alveolar macrophages and other cells (Delputte et al. 2002, Su et al. 2021); (2) Sialic acid adherin is a receptor for PRRSV, but only exists in PAM (Duan et al. 1998, Vanderheijden et al. 2003, Delputte et al. 2005, Xie et al. 2018, Su et al. 2021); (3) CD163 is a functional receptor for PRRSV and is expressed in various cells (Van Gorp et al. 2008, Xu et al. 2020); (4) The muscle myosin heavy chain II type A widely exists in a variety of cells and is essential for the invasion of PRRSV (Gao et al. 2016, Li et al. 2019, Liu et al. 2019b, Liang et al. 2020). Additionally, several other proteins may also act as receptor molecules for PRRSV invasion into host cells (Delputte et al. 2002, Su et al. 2021); (5) Vimentin is primarily expressed in fibroblasts and endothelial cells such as Marc-145 cells. The interaction between vimentin and PRRSV-N protein and the increase or decrease of vimentin expression in cultured

cells can promote or reduce PRRSV infection; thus, vimentin may be an important member of PRRSV receptor complex (Liang et al. 2020); (6) CD151 is one of the important members of the four transmembrane superfamily, and is involved in cell signal transduction, cell proliferation, platelet aggregation, and other biological processes. It was found that the overexpression of CD151 could infect cells that did not support PRRSV infection, whereas treatment of Marc-145 cells with CD151 antiserum could completely block PRRSV infection. Although these studies have shown that CD151 is an effective regulatory molecule of PRRSV infection, its role in the invasion of PRRSV remains unclear (Shanmukhappa et al. 2007); (7) DC-specific intracellular adhesion molecule-3-grabbing non-integrin (DC-SIGN; CD209) is a member of the C-type lectin receptor superfamily on the surface of DCs. Similar to CD151, the overexpression of DC-SIGN can infect cells that do not support PRRSV infection. The results suggest that DC-SIGN may also be involved in the process of PRRSV infection (Huang et al. 2009). The PRRSV binds to these receptors separately or simultaneously to mediate viral invasion and replication, leading to infection of a variety of cells. As for the existence of other PRRSV receptors in pigs, it has not been confirmed yet, and further studies are needed.

Acknowledgements

This study was supported by grants from the Nanchong Vocational and Technical College for basic scientific research (no. ZRA1904 and no. NZYBZ2002), the Applied Technology Research and Development Program of Nanchong (no. 19YFZJ0027) and the Nanchong High-Level Talents Special Support Program (Scientific Elite Of Ten-Thousands Talents Program).

References

- An TQ, Li JN, Su CM, Yoo D (2020) Molecular and Cellular Mechanisms for PRRSV Pathogenesis and Host Response to Infection. *Virus Res* 286: 197980.
- Bikhet M, Morsi M, Hara H, Rhodes LA, Carlo WF, Cleveland D, Cooper DK, Iwase H (2020) The immune system in infants: Relevance to xenotransplantation. *Pediatr Transplant* 24: e13795.
- Delputte PL, Costers S, Nauwynck HJ (2005) Analysis of porcine reproductive and respiratory syndrome virus attachment and internalization: distinctive roles for heparan sulphate and sialoadhesin. *J Gen Virol* 86: 1441-1445.
- Delputte PL, Vanderheijden N, Nauwynck HJ, Pensaert MB (2002) Involvement of the matrix protein in attachment of porcine reproductive and respiratory syndrome virus to a heparinlike receptor on porcine alveolar macrophages. *J Virol* 76: 4312-4320.
- Duan X, Nauwynck HJ, Favoreel H, Pensaert MB (1998) Porcine reproductive and respiratory syndrome virus infection of alveolar macrophages can be blocked by monoclonal antibodies against cell surface antigens. *Adv Exp Med Biol* 440: 81-88.
- Gao J, Xiao S, Xiao Y, Wang X, Zhang C, Zhao Q, Nan Y, Huang B, Liu H, Liu N, Lv J, Du T, Sun Y, Mu Y, Wang G, Syed SF, Zhang G, Hiscox JA, Goodfellow I, Zhou EM (2016) MYH9 is an Essential Factor for Porcine Reproductive and Respiratory Syndrome Virus Infection. *Sci Rep* 6: 25120.
- Han J, Zhou L, Ge X, Guo X, Yang H (2017) Pathogenesis and control of the Chinese highly pathogenic porcine reproductive and respiratory syndrome virus. *Vet Microbiol* 209: 30-47.
- Huang YW, Dryman BA, Li W, Meng XJ (2009) Porcine DC-SIGN: molecular cloning, gene structure, tissue distribution and binding characteristics. *Dev Comp Immunol* 33: 464-480.
- Jung K, Renukaradhya GJ, Alekseev KP, Fang Y, Tang Y, Saif LJ (2009) Porcine reproductive and respiratory syndrome virus modifies innate immunity and alters disease outcome in pigs subsequently infected with porcine respiratory coronavirus: implications for respiratory viral co-infections. *J Gen Virol* 90: 2713-2723.
- Li J, Wang S, Li C, Wang C, Liu Y, Wang G, He X, Hu L, Liu Y, Cui M, Bi C, Shao X, Wang X, Xiong T, Cai X, Huang L, Weng C (2017) Secondary Haemophilus parasuis infection enhances highly pathogenic porcine reproductive and respiratory syndrome virus (HP-PRRSV) infection-mediated inflammatory responses. *Vet Microbiol* 204: 35-42.
- Li L, Zhang L, Hu Q, Zhao L, Nan Y, Hou G, Chen Y, Han X, Ren X, Zhao Q, Tao H, Sun Z, Zhang G, Wu C, Wang J, Zhou EM (2019) MYH9 Key Amino Acid Residues Identified by the Anti-Idiotypic Antibody to Porcine Reproductive and Respiratory Syndrome Virus Glycoprotein 5 Involve in the Virus Internalization by Porcine Alveolar Macrophages. *Viruses* 12: 40.
- Liang Z, Li P, Wang C, Singh D, Zhang X (2020) Visualizing the Transport of Porcine Reproductive and Respiratory Syndrome Virus in Live Cells by Quantum Dots-Based Single Virus Tracking. *Virol Sin* 35: 407-416.
- Liu J, Wei C, Lin Z, Fan J, Xia W, Dai A, Yang X (2019a) Recombination in lineage 1, 3, 5 and 8 of porcine reproductive and respiratory syndrome viruses in China. *Infect Genet Evol* 68: 119-126.
- Liu Y, Li R, Chen XX, Zhi Y, Deng R, Zhou EM, Qiao S, Zhang G (2019b) Nonmuscle Myosin Heavy Chain IIA Recognizes Sialic Acids on Sialylated RNA Viruses To Suppress Proinflammatory Responses via the DAP12-Syk Pathway. *mBio* 10: e00574-19.
- Lunney JK, Fang Y, Ladinin A, Chen N, Li Y, Rowland B, Renukaradhya GJ (2016) Porcine Reproductive and Respiratory Syndrome Virus (PRRSV): Pathogenesis and Interaction with the Immune System. *Annu Rev Anim Biosci* 4: 129-154.
- Obradovic MR, Segura M, Segales J, Gottschalk M (2021) Review of the speculative role of co-infections in Streptococcus suis-associated diseases in pigs. *Vet Res* 52: 49.
- Pearse G (2006) Normal structure, function and histology of the thymus. *Toxicol Pathol* 34: 504-514.
- Ramirez M, Bauermann FV, Navarro D, Rojas M, Manchego A, Nelson EA, Diel DG, Rivera H (2019) Detection of porcine reproductive and respiratory syndrome virus (PRRSV) 1-7-4-type strains in Peru. *Transbound Emerg Dis* 66: 1107-1113.
- Sampath P, Moideen K, Ranganathan UD, Bethunaickan R (2018) Monocyte Subsets: Phenotypes and Function in Tuberculosis Infection. *Front Immunol* 9: 1726.
- Shanmukhappa K, Kim JK, Kapil S (2007) Role of CD151, A tetraspanin, in porcine reproductive and respiratory syndrome virus infection. *Virol J* 4: 62.
- Su CM, Rowland RRR, Yoo D (2021) Recent advances in PRRS virus receptors and the targeting of receptor-ligand for control. *Vaccines (Basel)* 9: 354.
- Van Gorp H, Van Breedam W, Delputte PL, Nauwynck HJ (2008) Sialoadhesin and CD163 join forces during entry of the porcine reproductive and respiratory syndrome virus. *J Gen Virol* 89: 2943-2953.
- Vanderheijden N, Delputte PL, Favoreel HW, Vandekerckhove J, Van Damme J, van Woensel PA, Nauwynck HJ (2003) Involvement of sialoadhesin in entry of porcine reproductive and respiratory syndrome virus into porcine alveolar macrophages. *J Virol* 77: 8207-8215.
- Wang G, He Y, Tu Y, Liu Y, Zhou EM, Han Z, Jiang C, Wang S, Shi W, Cai X (2014) Comparative analysis of apoptotic changes in peripheral immune organs and lungs following experimental infection of piglets with highly pathogenic and classical porcine reproductive and respiratory syndrome virus. *Virol J* 11: 2.
- Wang G, Li L, Yu Y, Tu Y, Tong J, Zhang C, Liu Y, Li Y, Han Z, Jiang C, Wang S, Zhou EM, He X, Cai X (2016) Highly pathogenic porcine reproductive and respiratory

- syndrome virus infection and induction of apoptosis in bone marrow cells of infected piglets. *J Gen Virol* 97: 1356-1361.
- Wang G, Yu Y, Cai X, Zhou EM, Zimmerman JJ (2020a) Effects of PRRSV Infection on the Porcine Thymus. *Trends Microbiol* 28: 212-223.
- Wang W, Thomas R, Sizova O, Su DM (2020b) Thymic function associated with cancer development, relapse, and antitumor immunity - A mini-review. *Front Immunol* 11: 773.
- Wensvoort G, Terpstra C, Pol JM, ter Laak EA, Bloemraad M, de Kluyver EP, Kragten C, van Buiten L, den Besten A, Wagenaar F (1991) Mystery swine disease in The Netherlands: the isolation of Lelystad virus. *Vet Q* 13: 121-130.
- Wu Z, Zhang Z, Lei Z, Lei P (2019) CD14: Biology and role in the pathogenesis of disease. *Cytokine Growth Factor Rev* 48: 24-31.
- Xie J, Christiaens I, Yang B, Trus I, Devriendt B, Cui T, Wei R, Nauwynck HJ (2018) Preferential use of Siglec-1 or Siglec-10 by type 1 and type 2 PRRSV strains to infect PK15(S1-CD163) and PK15(S10-CD163) cells. *Vet Res* 49: 67.
- Xu K, Zhou Y, Mu Y, Liu Z, Hou S, Xiong Y, Fang L, Ge C, Wei Y, Zhang X, Xu C, Che J, Fan Z, Xiang G, Guo J, Shang H, Li H, Xiao S, Li J, Li K (2020) CD163 and pAPN double-knockout pigs are resistant to PRRSV and TGEV and exhibit decreased susceptibility to PDCoV while maintaining normal production performance. *Elife* 9.
- Zhang HL, Zhang WL, Xiang LR, Leng CL, Tian ZJ, Tang YD, Cai XH (2018) Emergence of novel porcine reproductive and respiratory syndrome viruses (ORF5 RFLP 1-7-4 viruses) in China. *Vet Microbiol* 222: 105-108.
- Zhou YJ, Hao XF, Tian ZJ, Tong GZ, Yoo D, An TQ, Zhou T, Li GX, Qiu HJ, Wei TC, Yuan XF (2008) Highly virulent porcine reproductive and respiratory syndrome virus emerged in China. *Transbound Emerg Dis* 55: 152-164.