

DOI 10.24425/pjvs.2022.142029

Original article

Vitamin E protected the mouse adrenal gland against immobilization stress

F. Aşır, Y. Nergiz, A. Pala

Department of Histology and Embryology, School of Medicine, Dicle University, Diyarbakır, Turkey

Abstract

In this study, we aimed to investigate the effects of vitamin E on mouse adrenal glands in immobilization stress. Twenty-eight male, 10-week-old, BALB/C mice weighing 30-45 grams were divided into four groups. Mice were placed in a cage where no movement was allowed 6 hours/day for 7 days for immobilization stress. 10 ml/kg vitamin E was administered orogastrically 1 hour before immobilization stress in the vitamin E and stress+vitamin E group. At the end of the 7th day, all the animals were subjected to elevated-plus maze (anxiety) and forced swimming (depression) tests. Left adrenal glands were dissected for routine paraffin tissue embedding protocol. Adrenal sections were stained with hematoxylin-eosin and Azan. Malonaldehyde (MDA) levels were also measured in the adrenal tissues. Anxiety level (0.023), depression level ($p=0.042$) and MDA values ($p=0.01$) were significantly increased in the stress group. Histological sections of the stress group showed cortical atrophy, medullary hypertrophy, vascular dilation and hemorrhage. Azan staining revealed a thinned capsule and corticomedullary fibrosis in the stress group. Pathologies induced by immobilization stress were mostly reversed after vitamin E administration. The results suggested that vitamin E alleviates adverse effects of immobilization stress (oxidative, behavioral and histopathologic changes) in mice.

Key words: adrenal gland, immobilization, psychopharmacological tests, stress, vitamin E

Introduction

Stress is the reaction of the organism to all types of stressogenic stimulants that disrupt its physiological homeostasis (Chrousos and Gold 1992). Common stressogenic stimulants used in animal models are heat, coldness, physical restrictions, crowds, noise, immobilization, or isolation (Djordjević et al. 2003). Human beings always experience stressful conditions and the human body copes with these conditions in two ways: i. pumping adrenaline and noradrenaline into the body via the sympathetic nervous system; and ii. activating

the hypothalamic-pituitary-adrenal (HPA) axis and increasing corticosteroid levels. Both systems fight against stress in the body (Axelrod and Reisine 1984). The HPA and sympathoadrenomedullary systems are involved in maintaining the stability of the organism during stress, and the adrenal gland is the final decision-making center in both systems (Petrovic-Kosanovic et al. 2012). Vitamin E is a general term for fat-soluble compounds and is found in foods containing fat. It was first discovered by Evans and Bishop in 1922 (Niki and Traber 2012). Vitamin E is classified into two groups by its saturated or unsaturated side chains. Satu-

rated forms are called tocopherols, and unsaturated forms are tocotrienols. Each subgroup has four isoforms: α , β , γ , δ tocopherols, and α , β , γ , δ tocotrienols. The biologically most active form is α -tocopherol (Mitchell and Benevenga 1978, Wang and Quinn 1999). Vitamin E has been used as an antioxidant for many years (Tappel 1980, Burton et al. 1982). Burton and Traber (1990) stated that tocopherols are well recognized for their effective inhibition of lipid peroxidation in foods and living cells. Different forms of tocopherols scavenge free radicals of unsaturated lipids by their antioxidative activity (Burton and Ingold 1981, Niki et al. 1984, van Acker et al. 1993). Vitamin E shows its antioxidant activity by interacting with cellular membrane and inhibits lipid peroxidation. Tocopherols remove the free radicals by scavenging chain-propagating peroxy radical. Alpha-tocopherol protects the liver microsomes against Fe(II) NADPH-induced lipid peroxidation and cytochrome P-450 against oxidative damage.

The chromanoxyl radical alpha-tocopherol is recycled in cellular membranes and lipoproteins, thus interfering oxidative stress mechanism. A clinical trial has shown that vitamin E reduces serum cholesterol low density lipoprotein level in humans with high cholesterol levels (Qureshi et al. 2001). Vitamin E modulates expression of some genes related to lipid peroxidation due to its antioxidant activity by inhibiting protein kinase C, 5-lipoxygenase and phospholipase A2 and activating protein phosphatase 2A and diacylglycerol kinase (Sen et al. 2006).

Immobilization stress can render impacts on adrenal glands by either hormonal or histopathological changes or both. Sanchez et al. (2003) investigated the concentration of catecholamines in rat adrenal glands exposed to acute immobilization stress. They stated that immobilization stress significantly elevated epinephrine and norepinephrine concentrations in the adrenal gland in the stressed groups during 30 and 50 min as compared to the control group. In another study, transgenic mice were subjected to immobilization stress 120 min/day for 10 consecutive days, and results showed that chronic immobilization stress caused anxiety-like behavior. Moreover, adrenal glands of mice were hypertrophied, and serum corticosterone and adrenocorticotrophic hormone (ACTH) levels were increased (Qin et al. 2011). Sunwoo et al. (2019) used an electrophysiological probe to examine cortisol hormonal changes and adrenomedullary cellular activities. They injected ACTH, a biomarker of chronic stress, and observed the signals from the probe. They recorded that within minutes after ACTH injection, cortisol and glucose level were elevated with increased signal frequency. The author stated that ACTH administration

increased electrophysiological sings in adrenal cortex and medulla, indicating high cellular activities in the adrenal glands. In a histopathological and ultrastructural study of the adrenal gland by Altayeb et al. (2017), rats were subjected to immobilization stress 2 hours/day for 30 consecutive days. They observed loss of structural integrity of zones with vacuolated cells and multiple darkly stained nuclei, vascular congestion and dilation and increased collagen fibers in the cortex.

Immobilization stress causes biochemical, behavioral, and histopathological changes in adrenal glands. In this study, we aimed to investigate the effects of vitamin E administration against immobilization stress-induced changes in mice adrenal glands by analyzing oxidative stress levels, and behavioral, and histopathological changes.

Materials and Methods

A) Experimental design

The study was conducted at the Dicle University Animal Research Center. All procedures were approved by the Dicle University Animal Care and Use Local Committee with ethical approval number 2017/13. Twenty-eight male, 10-week-old, BALB/C mice weighing 30-45 grams were housed in an air-conditioned room, with 12-hour light/dark, at 25°C temperature and 65-70% humidity. Mice were assigned to 4 groups: control, vitamin E, stress and stress+vitamin E (7 mice per group).

Three tenths mg α -tocopherol (cat# T325-25G, Sigma, St. Louis, Missouri, USA) was dissolved in 0.1 ml olive oil. 10 ml/kg α -tocopherol+olive oil was administered to each animal in vitamin E and stress+vitamin E groups through the orogastric route for 7 days (0.9 mg α -tocopherol administration within 0.3 ml α -tocopherol+olive oil per animal). 10 ml/kg saline solution was introduced to mice in control and stress groups through the orogastric route for 7 days. The weights of all mice were recorded before the experiments. Immobilization stress were created by placing mice in a cage as small as their size to prevent their movement. This procedure was performed 6 hours/day for 7 days. In the stress+vitamin E group, 10 ml/kg vitamin E was given one hour before the experiment protocol. At the end of seventh day, all mice were subjected to psychopharmacological tests individually.

B) Anxiety-depression tests

At the end of the 7th day, all mice were subjected to elevated-plus maze (Pellow et al. 1985) and forced swimming tests (Burgin et al. 1996) to measure anxiety

and depression levels. The tests were expected to show behavioral changes between the groups so that the efficacy of vitamin E is proven on stress groups.

Elevated-Plus maze

The mice were observed with the EthoVision® digital software for 5 minutes in a maze, 50 cm high from ground. The maze had two open and two closed arms. The mice were placed in the intersection of arms and their movements toward the closed/open arms were recorded to evaluate their anxiety level.

Forced Swimming Test

This test was performed to assess the depression levels of mice. The mice were marked with a digital camera and they swam in a cylinder with a radius of 20 cm, a height of 50 cm, and 2/3 of water (25°C) for 6 minutes. To calculate the depression level, the mobilized and immobilized time periods in animal behaviors were recorded for the last 4 minutes by the EthoVision® XT 11.0 (Noldus Inf. Tech, Netherlands) software.

After the tests, mice were intramuscularly anesthetized with 10 mg/kg xylazine (Rompun®, Bayer, Germany) and 150 mg/kg ketamine hydrochloride (Ketalar®, Pfizer, New York, USA) and sacrificed by intracardiac blood collection.

C) Malonaldehyde (MDA) level analysis

MDA is one of the final products of polyunsaturated fatty acid peroxidation in the cells. It is an indicator of oxidative stress. MDA level is elevated during increased free radicals. In order to show antioxidant activity of vitamin E, MDA level was measured. Right adrenal glands were dissected for Malonaldehyde (MDA) analysis. The adrenal tissues were homogenized on ice-cold PBS (phosphate-buffered saline, 0.01M, PH:7.4). The homogenates were centrifuged at 5000 g for 5 minutes and pellets were discarded. MDA levels were determined by conventionally produced kits (Elabscience Biotechnology, China) with an auto enzymelinked immunosorbent assay (ELISA) plate analyzer (Robonik, Thane, India). MDA level were recorded as nmol/g.

D) Tissue processing for histopathology

The left adrenal glands were dissected and fixed in 10% formalin solution. After 24 hour of fixation, adrenal tissues were passed through ascending alcohol series (%50, %70, %80, %90, %96 and absolute alcohol) and soaked in xylene 3x15 minutes. The tissues

were incubated in paraffin wax 3x45 minutes at 58°C. 5-µm sections from paraffin tissue blocks were brought to distilled water. Sections were stained with hematoxylin-eosin (H-E) and Mallory Azan (cat # 04-020802, Biotica, Milano, Italy). For H-E, sections were soaked 6 minutes in hematoxylin and washed under trap water 5 minutes. Eosin dye was applied for 4 minutes and sections were dehydrated in ascending alcohol series and cleared in xylene and mounted. For AZAN staining, reagent A was applied to sections at 56°C for 30 minutes. Sections were allowed to cool 5 minutes at room temperature and washed in distilled water. Reagent B was left to act 1 minute, then without washing reagent C was applied for 1 minute.

Without washing reagent D was acted for 30 minutes and then reagent E for 30 minutes. Sections were dehydrated in ascending alcohols, cleared in xylene and mounted. The slides were evaluated under Zeiss Axio imager A2 (Carl Zeiss Microscopy, LLC, USA) light microscope.

E) Statistical analysis

All data were analyzed using IBM SPSS Statistics 25 (SPSS Co., Chicago, IL, USA). Results are shown as mean ± standard deviation (SD). Comparisons between groups were calculated by one-way analysis of variance (ANOVA) and then further analyzed by post-Hoc Tukey test. A value <0.05 was considered statistically significant.

Results

Elevated Plus Maze Test

Time spent in the open arms was lowest in the stress group, indicating the anxiety level of mice ($p=0.023$) (Fig. 1).

Forced Swimming Test

Immobilized time in the forced swimming test is shown in Fig. 2. Higher immobilized time was recorded in stress and stress+vitamin E groups compared to the control group ($p=0.04$ and $p=0.042$, respectively).

MDA Analysis

MDA value of the stress group was significantly higher than that of the control group. The vitamin E and the stress+vitamin E groups showed lower MDA value than the stress group ($p=0.01$ and $p=0.034$, respectively) (Fig. 3).

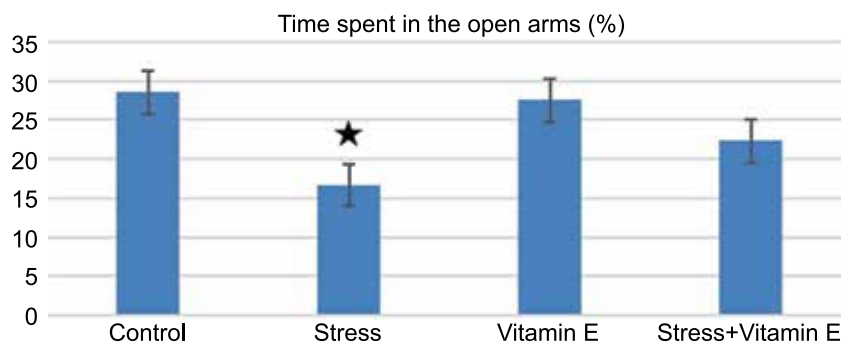


Fig. 1. Elevated plus maze results (time spent in the open arms) for all mice groups. * shows significance of the stress vs control group.

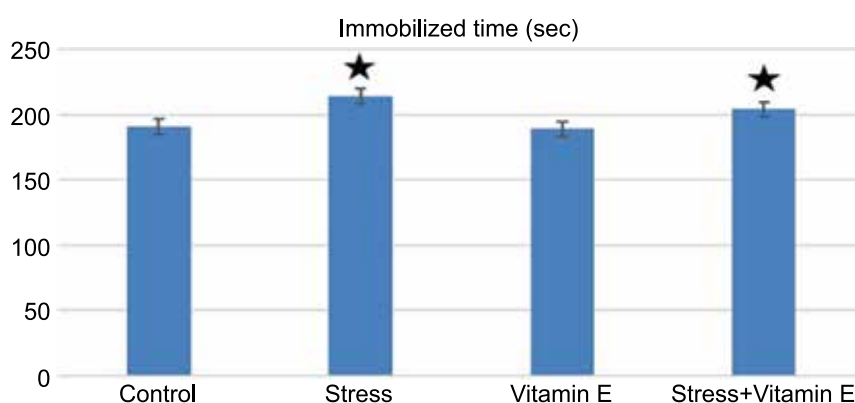


Fig. 2. The immobilized time passed in the forced swimming test for all mice groups. * shows statistical significance of stress groups vs. control group.

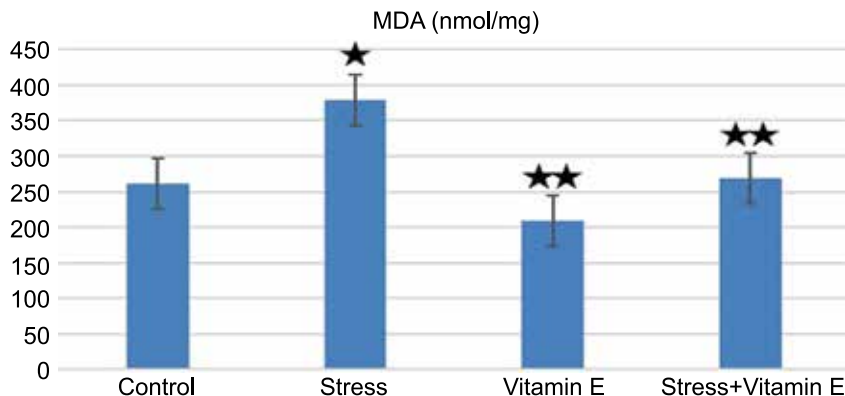


Fig. 3. The tissue MDA values of all mice groups. * shows significance of the stress vs control group, ** Vitamin E treated groups vs stress groups.

Histopathological findings

The adrenal gland was histologically normal with a fibrous capsule in the control group. The zones of glomerulosa, fasciculata, and reticularis were evident. Mitotic figures were observed in cortical zones (Fig 4a). In sections of the stress group, cortical atrophy and medullary hypertrophy were observed. The size of all three cortical zones was reduced, but the most atrophied zone was the zona glomerulosa. Vascular dilatation and hemorrhage were seen in the medulla (Fig 4b). Adrenal sections of the vitamin E group showed normal histo-

logical structure with the capsule, cortical layers, and medulla. The fibrous capsule, cortex, and medulla were histologically similar to those in the control group (Fig. 4c). In the stress+vitamin E group, histopathological findings (size of cortex, hemorrhage, vascular dilation, apoptosis) were mostly recovered compared to the stress group. The appearance of zones of glomerulosa, fasciculata, and reticularis and medulla were similar to that in the control group (Fig. 4d).

In the sections from the control group stained with AZAN dye, the adrenal gland looked histologically normal. The capsule was normal, and zona glomerulosa

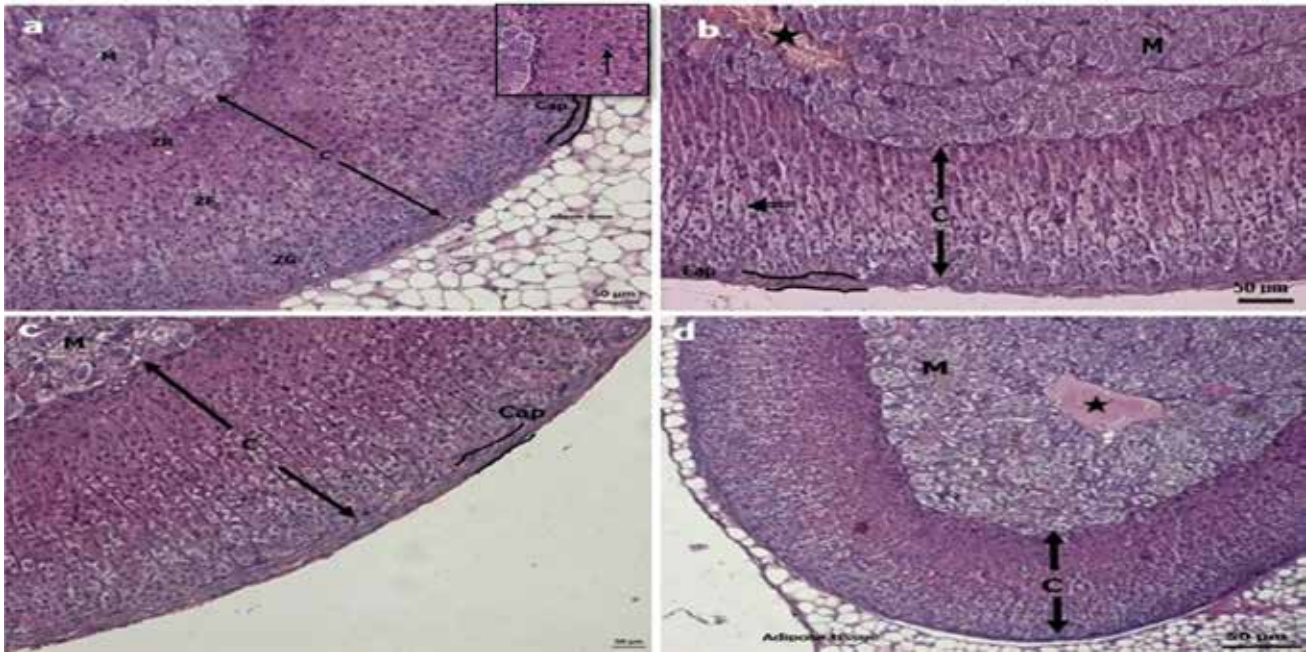


Fig. 4. **a)** Normal histological view of the adrenal cortex and medulla in the mice control group, zona glomerulosa (ZG), zona fasciculata (ZF), zona reticularis (ZR), medulla (M), cortex (C) were seen. Inset shows mitotic figures (arrowhead) at higher magnification. **b)** Cortical atrophy, zona fasciculata with pyknotic nuclei (double-tailed arrow), and medullary hypertrophy with vascular dilatation (asterisk) in the stress group section, Cap: capsule. **c)** Adrenal section of the vitamin E group. The capsule, adrenal cortex, and medulla were seen in normal histological structure. **d)** Cross-section of the adrenal gland with surrounding adipose tissue in the stress+vitamin E group. The gland was histologically normal except for medullary vascular dilatation, (hematoxylin-eosin, Scale Bar = 50 μ m).

cells beneath the capsule contained with dark-stained nuclei (Fig. 5a). In the sections of the stress group, the capsule diameter decreased, and the medulla size increased. Dense fibrosis was observed in the cortico-medullary region (Fig 5b). In the vitamin E group, normal adrenal gland histology was observed. The capsule, cortical zones, and medulla were structurally similar to those in the control group (Fig 5c). In the stress+vitamin E group, decreased interstitial fibrosis and vascular dilatation were observed. The histological structure of the adrenal cortex and medulla was similar to that in the control group (Fig 5d).

Discussion

In this study, the effects of vitamin E on the adrenal gland were investigated in the immobilization stress model. Mice were subjected to immobilization stress six hours a day for one week. Our results revealed stress-induced structural changes such as cortical atrophy, medullary hypertrophy, dilated capillaries, fibrosis, and hemorrhage in the adrenal gland confirming the findings obtained in previous studies (Ulrich-Lai et al. 2006, Adžić et al. 2009, Petrovic-Kosanovic et al. 2012). Moreover, we have demonstrated that vitamin E has a protective effect on these stress-induced changes.

Stress is a process that plays an active role in the pathogenesis of various diseases in rodents by deteriorating the physical, biochemical, and psychological parameters (de Pablos et al. 2014). It has been shown that stress has the potential to increase symptoms of anxiety and depression (Chen et al. 2014). Experimental studies have demonstrated that vitamin E has antidepressant-like effects (De Marchis et al. 2006, Lobato et al. 2010). Sahin et al. (2019) studied 10-day immobilization stress in female rats and recorded the anxiety and depression related behaviors. Their results showed the stress group had lower swimming duration in the swimming forced test compared to that in control group ($p=0.004$). In a chronic immobilization stress study, stress was applied for 4 h a day for 15 days to male rats. In the elevated plus maze test, the stress group had the highest anxiety index compared to the control group (Aykaç and Sehirli 2018). In this study, immobilization stress also caused severe anxiety-like behavior and depression as compared with unstressed animals. The stress group spent significantly more time in the closed arms of the elevated plus maze (Fig. 1) and the depression level of the mice in the stress group increased significantly in the forced swimming test, while the depression level in the vitamin E group was decreased (Fig. 2).

The exposure to stress may elevate the production

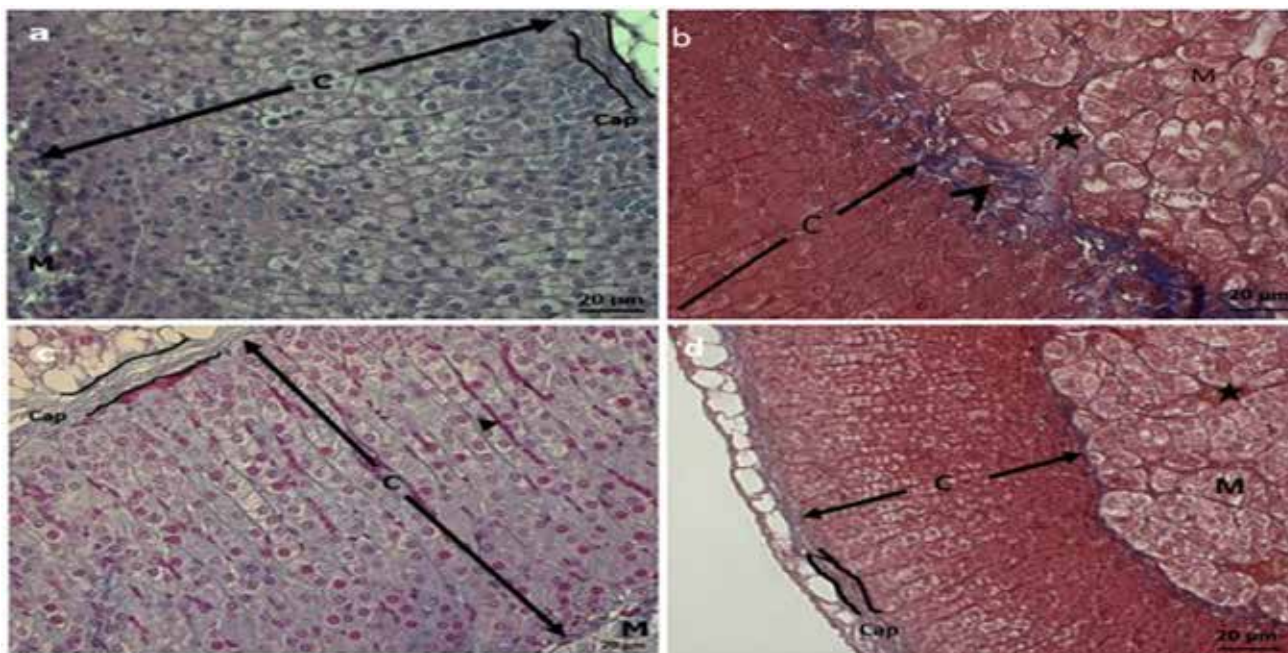


Fig. 5. **a)** Azan-stained control group sections with cortex (C) and medulla (M), zona glomerulosa beneath the capsule with dark stained nuclei and mitotic figures (arrowhead). **b)** Increased fibrosis (arrowhead) in the corticomedullary border and hypertrophic medulla with vascular dilatation and hemorrhage (asterisk) in the stress group. **c)** Adrenal section from the vitamin E group. The normal histological appearance of the capsule (Cap), cortex with cortical sinusoid (arrowhead) and medulla. **d)** Normal histological view of an adrenal section with decreased interstitial fibrosis (arrowhead) in the corticomedullary border and vascular dilatation (asterisk) in the medulla in the stress+vitamin E group, (Azan; scale bar = 20 µm).

of free radicals and impair the antioxidant defense system, leading to oxidative damage and imbalance between oxidant and antioxidant factors (Bagchi et al. 1999, Ganesan et al. 2011). Yuksel et al. (2020) exposed rats to immobilization stress and measured their MDA level (a biomarker of lipid peroxidation). MDA value in the stress group (24.50 nmol/mgp) was higher than that in the control group (12.20 nmol/mgp). Liu et al. (1996) investigated MDA level in cerebral tissues of rats exposed to immobilization stress. The authors revealed that MDA level was higher than MDA value in different parts of the brain in the control rats. We measured MDA levels, which was the highest in the stress group. MDA levels in the vitamin E treated groups were significantly lower than those in stress group (Fig 3). These results confirmed that vitamin E has antioxidant effects that can protect the adrenal gland tissue from stress-induced oxidative stress.

The exposure to immobilization stress also causes histopathological changes in the stomach, intestine, testis, and adrenal gland in male rats (Gabry et al. 2002, El-Desouki et al. 2011, El-Desouki et al. 2012). It has been found that rate of cytogenesis in each zone of the adrenal cortex is different. Cell proliferation and mitosis predominantly occur especially in the zona glomerulosa and possibly the zona fasciculata, while the zona reticularis is mostly home to newly formed cells (Stachowiak et al. 1990, Miyamoto et al. 2000,

Wright et al. 2004). Immobilization stress may cause some hormonal changes in adrenal glands leading to both decreased cortex and capsule thickness. Also, cell death rate may be higher than the mitotic activity in cortical zones and this may lead to reduced cortex thickness. Histochemical observations in the present work showed that the control and vitamin E groups indicated similar histological appearances (Fig 4a, c). Cortical atrophy was observed in the stress and stress+vitamin E groups. This was because of the balance between mitosis and cell death. In our study, the balance was in favor of cell death. However, atrophy in the stress+vitamin E group was lower than in the stress group suggesting that vitamin E induces cortical cells to drive mitosis (Stachowiak et al. 1990). Vascular dilatation, congestion, and hemorrhage were also found in this group. Generally, the histology in the stress+vitamin E group was similar to that in the control group (Fig 4b,d).

El-Refaiy (2010) and Jyoti et al. (2003) have found that the exposure to stress increases fibroblast and collagen fiber synthesis leading to the thickening of the testis basement membrane. Furthermore, increased fibrosis in the colon mucosa of rats exposed to stress due to collagen synthesis has also been documented (El-Deriyen and Mousa 2006). El-Desouki et al. (2011) have revealed immobilized stress ultra-structurally causes elevated levels of collagen fibers

in the rat adrenal cortex. In the AZAN-stained sections, the control group and the vitamin E group showed no fibrosis (Fig 5a, c). Interstitial fibrosis through the adrenal cortex was observed in the stress group, but dense fibrosis was found in the corticomedullary region. Excessive vascular dilatation, congestion, and hemorrhage were also observed in the stress group. In the stress+vitamin E group, these symptoms were mostly recovered, but signs of fibrosis were still evident (Fig 5b, d).

Conclusion

Immobilization stress causes the oxidative, behavioral and histopathological changes in mice, however vitamin E showed adrenoprotective effect against these alterations. Further molecular techniques are required to enlighten the mechanism of Vitamin E on adrenal gland.

Limitation

A hormone levels (e.g. catecholamines, ACTH) could be measured to observe stress effects. Further molecular techniques (immunohistochemistry, western blot, tunnel assay) could be more helpful to elucidate histological adrenal changes and related gene expression.

References

- Adžić M, Đorđević A, Đorđević J, Nićiforović A, Radojčić MB (2009) Effect of different types of stress on adrenal gland parameters and adrenal hormones in the blood serum of male Wistar rats. *Arch of Biol Sci* 61: 187-194.
- Altayeb Z, Salem M (2017) Light and electron microscopic study on the effect of immobilization stress on adrenal cortex of adult rats and possible ameliorative role of vitamin E. *Journal of Medical Histology* 1: 44-56.
- Axelrod J, Reisine TD (1984) Stress hormones: their interaction and regulation. *Science* 224: 452-459.
- Aykaç A, Sehirlı AO (2018) The effects of citalopram and low-dose risperidone on memory and anxiety in rats subjected to chronic immobilization stress. *Psychiatry and Clinical Psychopharmacology* 29: 244-251.
- Bagchi D, Carryl OR, Tran MX, Bagchi M, Garg A, Milnes MM, Williams CB, Balmoori J, Bagchi DJ, Mitra S, Stohs SJ (1999) Acute and chronic stress-induced oxidative gastrointestinal mucosal injury in rats and protection by bismuth subsalicylate. *Mol Cell Biochem* 196: 109-116.
- Burgin R, Weizman R, Gavish M (1996) Repeated swim stress and peripheral-type benzodiazepine receptors. *Neuropsychobiology* 33: 28-31.
- Burton GW, Ingold KU (1981) Autoxidation of biological molecules. 1. Antioxidant activity of vitamin E and related chain-breaking phenolic antioxidants in vitro. *Journal of the American Chemical Society* 103: 6472-6477.
- Burton GW, Joyce A, Ingold KU (1982) First proof that vitamin E is major lipid-soluble, chain-breaking antioxidant in human blood plasma. *Lancet* 2: 327.
- Burton GW, Traber MG (1990) Vitamin E: antioxidant activity, biokinetics, and bioavailability. *Annu Rev Nutr* 10: 357-382.
- Chen L-j, Shen B-q, Liu D-d, Li S-t (2014) The Effects of Early-Life Predator Stress on Anxiety- and Depression-Like Behaviors of Adult Rats. *Neural Plasticity* 2014: 163908.
- Chrousos GP, Gold PW (1992) The concepts of stress and stress system disorders. Overview of physical and behavioral homeostasis. *JAMA* 267: 1244-1252.
- De Marchis GM, Bürgi S, Kientsch U, Honegger UE (2006) Vitamin E reduces antidepressant-related beta-adrenoceptor down-regulation in cultured cells. Comparable effects on St. John's wort and tricyclic antidepressant treatment. *Planta Med* 72: 1436-1437.
- de Pablos RM, Sarmiento M, Espinosa-Oliva AM (2014) Creating a rat model of chronic variate stress. *Bio-protocol* 4: e1315-e1315.
- Djordjević J, Cvijić G, Davidović V (2003) Different activation of ACTH and corticosterone release in response to various stressors in rats. *Physiol Res* 52: 67-72.
- El-Derieny E, Mousa A (2006) Histological study on the effect of stress on the colonic mucosa of adult male albino rat and possible role of mast cells. *Egypt J Histol* 29: 315-326.
- El-Desouki N, El-Refaiy A, Abdel-Azeem H, El-Baely M (2011) Histological and ultrastructural studies of the effect of immobilization stress on the adrenal cortex of albino rat and the ameliorative role of diazepam. *J Egypt Ger Soc Zool* 62: 25-45.
- El-Desouki NI, El-Refaiy AI, Afifi D, Abdel-Kader AA (2012) Histological, histochemical, and immunohistochemical studies of the cardiac muscle of the albino rat under immobilization stress and the curative role of diazepam. *The Egyptian Journal of Experimental Biology (Zoology)* 8: 273-285.
- El-Refaiy A (2010) Histological and histochemical studies on the testes of albino rat under immobilization stress and the possible curative role of diazepam. *J Egypt Ger Soc Zool* 60: 1-22.
- Gabry KE, Chrousos GP, Rice KC, Mostafa RM, Sternberg E, Negro AB, Webster EL, McCann SM, Gold PW (2002) Marked suppression of gastric ulcerogenesis and intestinal responses to stress by a novel class of drugs. *Mol Psychiatry* 7: 474-483, 433.
- Ganesan B, Anandan R, Lakshmanan PT (2011) Studies on the protective effects of betaine against oxidative damage during experimentally induced restraint stress in Wistar albino rats. *Cell Stress Chaperones* 16: 641-652.
- Jyoti R, Pandey S, Srivastava R (2003) Effect of immobilization stress on Spermatogenesis of Albino Rats. *J Anat Soc India* 52: 55-57.
- Liu J, Wang X, Shigenaga MK, Yeo HC, Mori A, Ames BN (1996) Immobilization stress causes oxidative damage to lipid, protein, and DNA in the brain of rats. *FASEB J* 10: 1532-1538.
- Lobato KR, Cardoso CC, Binfaré RW, Budni J, Wagner CL,

- Brocardo PS, de Souza LF, Brocardo C, Flesch S, Freitas AE, Dafré AL, Rodrigues AL (2010) alpha-Tocopherol administration produces an antidepressant-like effect in predictive animal models of depression. *Behav Brain Res* 209: 249-259.
- Mitchell AD, Benevenga NJ (1978) The role of transamination in methionine oxidation in the rat. *J Nutr* 108: 67-78.
- Miyamoto H, Mitani F, Mukai K, Suematsu M, Ishimura Y (2000) Daily regeneration of rat adrenocortical cells: circadian and zonal variations in cytogenesis. *Endocr Res* 26: 899-904.
- Niki E, Saito T, Kawakami A, Kamiya Y (1984) Inhibition of oxidation of methyl linoleate in solution by vitamin E and vitamin C. *J Biol Chem* 259: 4177-4182.
- Niki E, Traber MG (2012) A history of vitamin E. *Ann Nutr Metab* 61: 207-212.
- Pellow S, Chopin P, File SE, Briley M (1985) Validation of open/closed arm entries in an elevated plus-maze as a measure of anxiety in the rat. *J Neurosci Methods* 14: 149-167.
- Petrovic-Kosanovic D, Velickovic K, Koko V, Jasnica N, Cvijic G, Milošević MC (2012) Effect of acute heat stress on rat adrenal cortex — a morphological and ultrastructural study. *Central European Journal of Biology* 7: 611-619.
- Qin M, Xia Z, Huang T, Smith CB (2011) Effects of chronic immobilization stress on anxiety-like behavior and basolateral amygdala morphology in *Fmr1* knockout mice. *Neuroscience* 194: 282-290.
- Qureshi AA, Sami SA, Salser WA, Khan FA (2001) Synergistic effect of tocotrienol-rich fraction (TRF(25)) of rice bran and lovastatin on lipid parameters in hypercholesterolemic humans. *J Nutr Biochem* 12: 318-329.
- Sahin Z, Koc A, Koca RO, Ozkurkculer A, Cakan P, Gormus Z, Kutlu S (2019) Comparison of effects of three distinct stress models on anxiety and depression-related behaviors in female rats. *Sakarya Tıp Dergisi* 9: 131-140.
- Sanchez A, Toledo-Pinto EA, Menezes ML, Pereira OC (2003) Changes in norepinephrine and epinephrine concentrations in adrenal gland of the rats submitted to acute immobilization stress. *Pharmacol Res* 48: 607-613.
- Sen CK, Khanna S, Roy S (2006) Tocotrienols: Vitamin E beyond tocopherols. *Life Sci* 78: 2088-2098.
- Stachowiak A, Nussdorfer GG, Malendowicz LK (1990) Proliferation and distribution of adrenocortical cells in the gland of ACTH- or dexamethasone-treated rats. *Histol Histopathol* 5: 25-29.
- Sunwoo SH, Lee JS, Bae S, Shin YJ, Kim CS, Joo SY, Choi HS, Suh M, Kim SW, Choi YJ, Kim T (2019) Chronic and acute stress monitoring by electrophysiological signals from adrenal gland. *PNAS* 116: 1146-1151.
- Tappel AL (1980) Vitamin E and selenium protection from in vivo lipid peroxidation. *Ann N Y Acad Sci* 355: 18-31.
- Ulrich-Lai YM, Figueiredo HF, Ostrander MM, Choi DC, Engeland WC, Herman JP (2006) Chronic stress induces adrenal hyperplasia and hypertrophy in a subregion-specific manner. *Am J Physiol Endocrinol Metab* 291: E965-973.
- van Acker SA, Koymans LM, Bast A (1993) Molecular pharmacology of vitamin E: structural aspects of antioxidant activity. *Free Radic Biol Med* 15: 311-328.
- Wang X, Quinn PJ (1999) Vitamin E and its function in membranes. *Prog Lipid Res* 38: 309-336.
- Wright KM, Linhoff MW, Potts PR, Deshmukh M (2004) Decreased apoptosome activity with neuronal differentiation sets the threshold for strict IAP regulation of apoptosis. *J Cell Biol* 167: 303-313.
- Yüksel H, Batu B, Oto G, Bingöl Ö (2020) Fluoxetine and *Gundelia tournefortii* L. Plant Extract in Rats Exposed to Chronic Immobilization Stress; Determination of Effect on Anxiety, Motor Activity, Kidney and Liver Tissues. *Erciyes Üniversitesi Veteriner Fakültesi Dergisi* 17: 138-148.