



Cezary Kępkas,
PhD, DSc, MD

is an Associate Professor at the Institute of Cardiology in Warsaw, with which he has been linked since the outset of his career. He is a specialist in internal medicine and cardiology, and an interventional cardiologist. For more than a decade, he has combined his work in the Hemodynamics Lab with the performance and interpretation of cardiac computed tomography.
ckepka@ikard.pl

IMAGES WORTH A THOUSAND WORDS

Computed tomography is opening up new possibilities for the diagnosis of coronary artery disease. If used routinely as a future screening method, it can detect the disease at a very early stage.

Cezary Kępkas

Institute of Cardiology in Warsaw

Computed tomography (CT), which has been used in medicine since the 1970s, remained practically non-existent as an imaging modality in coronary artery disease for the first several decades. Most older cardiologists consider invasive coronary angiography (ICA) to be the reference method in diagnostics (this method uses X-rays to examine blood flow to the heart, and involves the insertion of a thin tube, called cardiac catheter, into an artery in the wrist or groin).

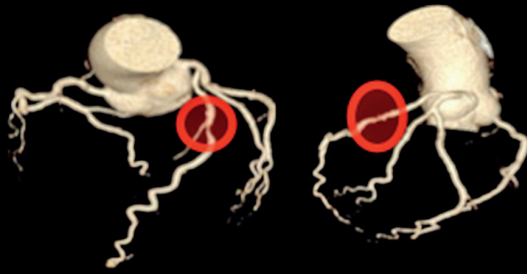
Over a decade ago, however, new advances in technology made it possible to visualize the coronary arteries using high-tech CT scanners. In the past several years, new generations of scanners have made it possible to examine more and more patients who previously could not benefit from this method. Medicine requires proven methods, so it is clear that the use of CT for imaging of the coronary arteries needed to take some time to develop properly, but this stage has already arrived. Today, claims that invasive coronary angiography is the reference method for evaluation of the coronary arteries are no longer well-founded – on the contrary, the indications for the use of this

method have become significantly limited. Instead, non-invasive computed tomography angiography (CTA) has now become the most common first-line modality for the evaluation of the coronary arteries. In addition, CTA offers us certain added value in the form of the qualitative and quantitative assessment of atherosclerosis, the evaluation of the blood flow to the myocardium, and the assessment of impaired blood flow in the coronary arteries based on advanced mathematical simulations.

We are changing history

For many years, the terms “gold standard” and “reference method” in the evaluation of the coronary arteries (or diagnosing coronary artery disease) were used exclusively to refer to invasive coronary angiography (ICA). The dominance of this method was so great that some cardiologist regarded it as definitive. Consequently, they were greatly surprised by the European Society of Cardiology’s (ESC) 2019 guidelines for the management of chronic coronary syndromes, where CTA was for the first time recommended as a first-line modality in patients with suspected coronary artery disease (the highest class of recommendations – IA). These guidelines ushered in a new era in cardiac imaging. CTA started to be used not only to diagnose acute aortic syndromes and pulmonary embolisms, but also to identify atherosclerotic lesions. The aforementioned guidelines were followed by other publi-

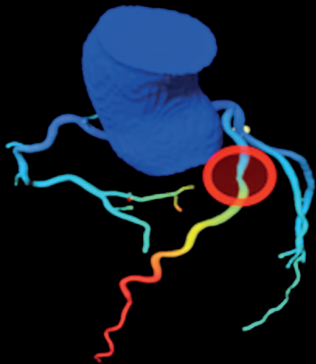
Routine CT scan



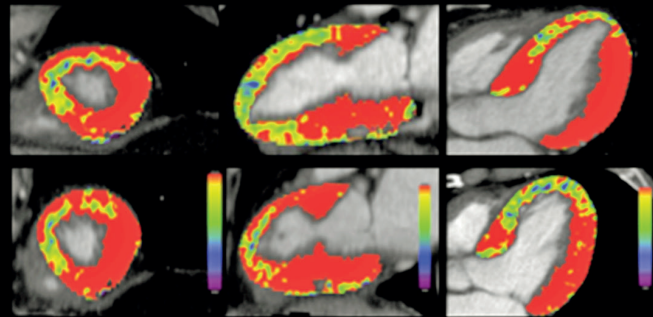
CT scan showing borderline stenosis in the left anterior descending artery (circles).

Below, we can see the evaluation of virtual coronary flow reserve (CT-FFR) with impaired flow in the peripheral segment of the vessel (red) and evaluation of perfusion under maximal flow conditions with visible impairments in anterior wall blood supply (colors other than red)

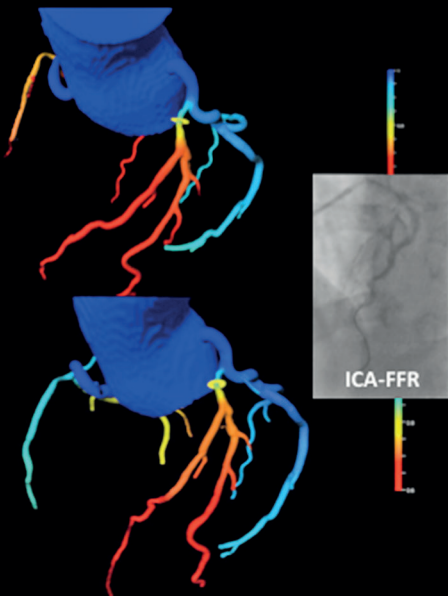
CT-FFR evaluation



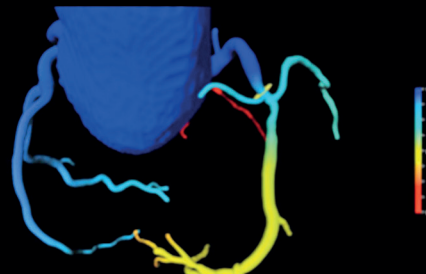
Perfusion assessment



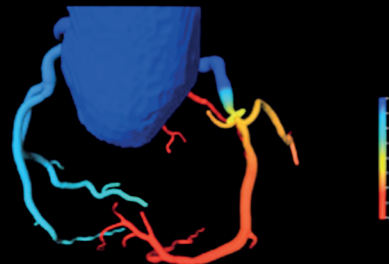
CT-FFR (LAD <math><0.8</math> – ischemia)



CT-FFR (RCA >math>>0.8</math> – no ischemia)



CT-FFR (RCA <math><0.8</math> – ischemia)



Assessment of virtual coronary flow reserve using routine CT based on advanced mathematical modeling (CT-FFR). On the left, we can see the most common site of stenosis in clinical practice (the initial segment of the left anterior descending artery, LAD); next to it, there is a corresponding image from a similar invasive measurement. On the right, we can see calculations for the right coronary artery (RCA). The top image shows a lesion causing no flow impairments (suited for conservative treatment); the bottom image, by contrast, shows a lesion causing impaired flow (a functionally significant lesion) in a large area of the myocardium

cations, including the extremely important recommendations of the American College of Cardiology (ACC) and the American Heart Association (AHA) for the evaluation and diagnosis of chest pain. Compared with previous guidelines, these recommendations expanded the indications for the use of CTA in diagnostic testing to an even greater extent. The mod-

ification of the diagnostic paradigm was followed by a change in the definition of coronary artery disease. In previous editions, a diagnosis of coronary artery disease required at least 50% stenosis in at least one epicardial artery. Currently, just confirming the presence of atherosclerotic plaque is enough to diagnose the disease. One can assume that one of the reasons

ACADEMIA FOCUS ON Medicine

for the change in definition was the widespread use of CT as a diagnostic method.

Here, it is worth stressing one of the key differences between invasive coronary angiography (ICA) and computed tomography angiography (CTA). The invasive method only shows us the lumen of blood vessels filled with contrast agent, without any information about possible pathology in the wall of the blood vessel. If we use the non-invasive CTA, on the other hand, we can evaluate not only the lumen of the vessel, but also the structure of its wall. This difference is crucial for optimal patient management – only CTA allows us to clearly rule out atherosclerosis and safely opt out of unnecessary treatment. At the other extreme are stable patients at the highest risk of developing acute coronary syndrome. It has been known for years that a type of plaque called vulnerable atherosclerotic plaque is a substrate for acute coronary syndrome. Such plaque typically does not narrow the lumen of the vessel to a significant extent and therefore may not cause significant symptoms. Invasive coronary angiography is completely useless in the diagnosis of lesions with this morphology, whereas CTA is the only method that allows them to be imaged.

Modern-day cardiology makes it possible to effectively treat patients with acute coronary syndrome. However, the fact remains that several percent of such patients die, and a significant share develop subsequent complications. For years, we did far worse in identifying patients at risk of developing acute inflammatory conditions. This qualitative shift in the key imaging modality – away from invasive coronary angiography towards non-invasive CTA – appears to offer a better chance for the precise identification of those at risk and will make it possible to take early preventive measures. In addition, advanced studies are ongoing in the field of diagnosing atherosclerosis

in non-contrast imaging. In addition, the possibility of identifying potentially dangerous atherosclerotic lesions using CT imaging alone opens up the road for the future use of CT in screening for coronary artery disease – through it unfortunately still remains unavailable today.

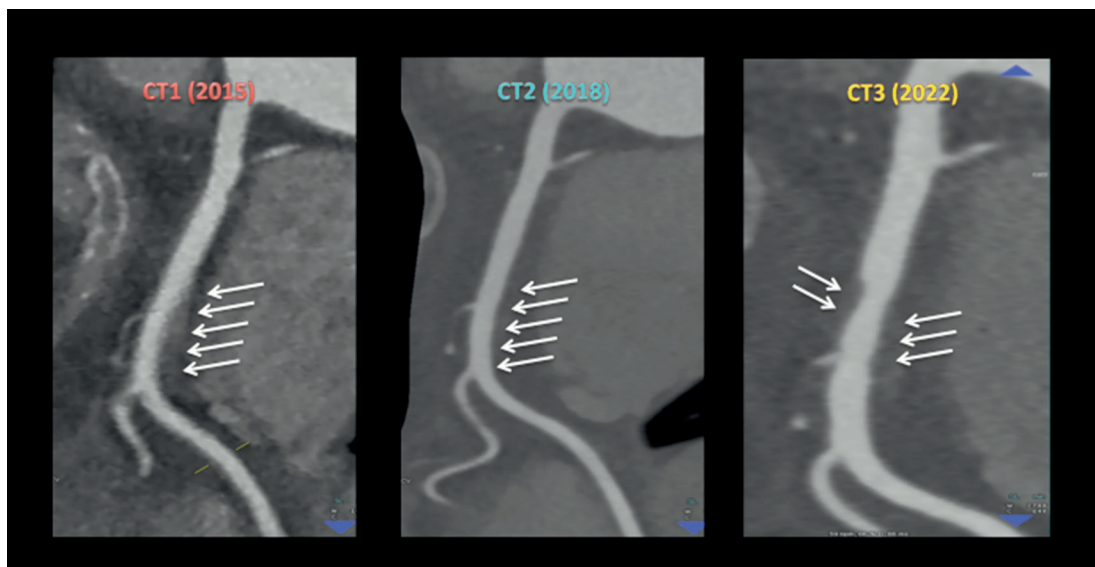
New possibilities

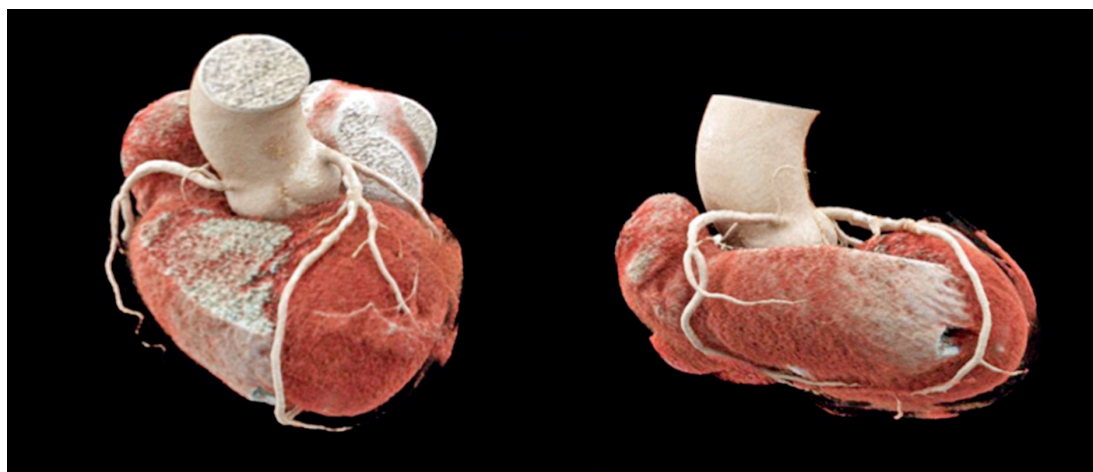
The latest CT scanners are being installed first at major clinical and research centers. In just several years, access to this technology has given researchers completely new and unusual applications for cardiac CT. Here, it is worth mentioning, for example, the assessment of perfusion, or what is called virtual fractional flow reserve (vFFR). Both applications, which go beyond the traditional evaluation of the patient's anatomy, appear to have the potential to be used on a broader scale in patients diagnosed for clinical purposes.

Just a few years ago, assessment of perfusion using CT techniques appeared impossible. But improved speed of CT data collection, along with increased detector coverage, has made it possible for the first time to assess the volume of blood flowing through specific parts of the myocardium over time. The usefulness of this method in identifying ischemic areas quickly proved comparable to that of other “traditional” methods, including isotope studies.

One extremely interesting CT-based functionality involves assessing flow impairments in stenotic coronary arteries using advanced mathematical modeling (vFFR, CT-FFR). This technique is based on the analysis of data obtained from typical CT imaging of the coronary arteries, such as segments of the vessels and the left ventricle and the delineation of the vessel axis and lumen. AI algorithms can be used to obtain a flow model with the distribution of pressures in each

CT scans showing differences in the quality of imaging (using scanners of newer generations) in the same patient, using the right coronary artery as an example (CT1 – an older generation scanner; limited possibility of reliably assessing the degree of atherosclerosis; CT2, CT3 – scanners with better parameters; the images are clearly of better quality, making it possible to reliably rule out the presence of atherosclerotic lesions in the CT2 scan and identify new lesions in the CT3 scan)





Routine CT examination showing three-dimensional reconstructions (volume rendering technique, VRT). The quality of data obtained using modern equipment allows us to evaluate not only the coronary arteries, but also all other structures in the heart with high precision

of the large coronary arteries. The model is visualized conveniently in the form of a color-coded image. All this takes place without the presence of the patient and without the need to acquire additional images.

The dark side

CT imaging of the coronary arteries is no easy task. To be able to assess atherosclerotic plaque and the blood flow to the myocardium and to simulate the significance of stenoses, we must obtain reproducible high-quality images. For high diagnostic accuracy, several conditions must be met. The most important of these are having sufficiently advanced scanner and an experienced team of technicians and doctors. These two factors determine the actual limitations of this technique. If we use a 64-row CT scanner (the least advanced of the acceptable devices), we will in most cases not be able to examine patients with atrial fibrillation and other arrhythmias, or those with a rapid resting heart rate. An attempt to perform the examination in such patients will result in the visualization of numerous artifacts that significantly reduce the value of the imaging, and it will be impossible to assess the quality of atherosclerosis. These limitations largely do not apply to more advanced devices, which are better suited for such imaging. The main advantages of advanced scanners include clearly better quality of imaging and the ability to examine also “more difficult” cases. Likewise, we must not underestimate the role of the team performing the exam. Numerous publications confirm that experience in performing such examinations evidently translates into better quality of the data obtained.

In the early days of the use of CT to assess the condition of the coronary arteries, the method was criticized for exposing patients to a relatively high dose of ionizing radiation and a large volume of contrast agent. In recent years, these limitations appear to be a lot less important. In experienced laboratories, a cor-

onary artery CT scan exposes the patient to a radiation dose comparable to that of coronary angiography (or often lower) and requires the administration of only 40–50 mL of contrast medium. Allegations leveled by skeptics on the issue of poor diagnostic accuracy are chiefly related to the quality of examinations at facilities that are not adequately prepared to perform such scans.

Is now the time?

And so, in recent years cardiologists have gained a modern, high-tech method for the comprehensive evaluation of atherosclerosis in the coronary arteries: using computed tomography. Compared with the traditional method – invasive coronary angiography – the undoubted advantage of CTA is its non-invasiveness, which translates into greater safety and comfort for patients, as well as improved logistics and reduced costs of diagnostic tests. Since cardiovascular disease is the most common cause of death in Poland, the widespread use of CTA may soon allow the development of new diagnostic pathways for patients with chest pain and suspected coronary artery disease.

Continued technological progress together with the development of advanced IT tools may soon allow imaging of atherosclerotic lesions (to confirm or rule out their presence) even in non-contrast examinations. Then, we will be only one step away from using CT as a screening method for coronary artery disease.

Additional benefits offered by CT, such as the reliable assessment of impaired blood flow to the myocardium and simulations of flow impairments, offer hope that in the near future CT of the coronary arteries will become not only the first-line diagnostic method, but also the only imaging modality used in the comprehensive diagnosis of coronary artery disease. We should also bear in mind that CT is the only non-invasive method we have that allows us to rule out atherosclerosis. ■

Further reading:

Bucciarelli-Ducci C., Ajmone-Marsan N., Di Carli M., Nicol E., The year in cardiovascular medicine 2021: imaging, *European Heart Journal* 2022, DOI: 10.1093/eurheartj/ehac033.

Gulati M., Levy P.D., Mukherjee D. et al., 2021 AHA/ACC/ASE/CHEST/SAEM/SCCT/SCMR Guideline for the Evaluation and Diagnosis of Chest Pain: A Report of the American College of Cardiology/ American Heart Association Joint Committee on Clinical Practice Guidelines, *Journal of the American College of Cardiology* 2021, DOI: 10.1016/j.jacc.2021.07.053.

Knuuti J., Wijns W., Saraste A. et al., 2019 ESC Guidelines for the diagnosis and management of chronic coronary syndromes, *European Heart Journal* 2020, DOI: 10.1093/eurheartj/ehz425.