

DOI 10.24425/pjvs.2024.151741

Original article

Ameliorative effects of ganoderma lucidum (Reishi) on testicular tissue of rats exposed to bisphenol A

T.C. Acisu¹, S.A. Akarsu², M. Sönmez¹, A. Yüce³, S. Çeribaşı⁴,
S. Dayan Cinkara¹, Ş. Özer Kaya¹, G. Türk¹, S. Gür¹

¹Department of Reproduction and Artificial Insemination, Faculty of Veterinary Medicine, Fırat University, 23119, Elazığ, Turkey

²Department of Reproduction and Artificial Insemination, Faculty of Veterinary Medicine, Atatürk University, 25240, Erzurum, Turkey

³Department of Physiology, Faculty of Veterinary Medicine, Fırat University, 23119, Elazığ, Turkey

⁴Department of Pathology, Faculty of Veterinary Medicine, Fırat University, 23119, Elazığ, Turkey

Correspondence to: T.C. Acisu, e-mail: tcacisu@firat.edu.tr

Abstract

Bisphenol A (BPA), an endocrine disrupting chemical, is an environmental toxicant widely used in the production of polycarbonate plastics, epoxy resins and paints. *Ganoderma lucidum* (GDL) is a plant with biological activities widely used in Chinese medicine. The present study aims to determine the effects of GDL against testicular dysfunction in rats exposed to BPA. For this purpose, a total of 24 Sprague Dawley rats, 6 rats in each group, were used in the study. Rats were administered 25 mg/kg/bw BPA and 300 mg/kg/bw GDL by oral gavage for 8 weeks. After the treatments, the rats were sacrificed, and testicular tissues were removed. One of the testes was used for biochemical analyses and the other for histopathologic examinations. The caudal part of the epididymis was trimmed, and semen was obtained. As a result, BPA increased MDA level in blood and testicular tissue, while it decreased CAT, GPx activity and GSH level. GDL treatment provided protection from the impaired oxidant balance ($p<0.001$). Furthermore, BPA caused decreased epididymal sperm motility and density, vesicular seminalis weight and blood testosterone levels, increased testicular and epididymal tissue weight ($p<0.001$). Histopathological examination revealed that BPA caused narrowing in testicular tubules and apoptosis, decreased germinal cell thickness and androgen receptor number. It was determined that GDL administration preserved testicular histology. As a result, it was determined that BPA caused toxicity in the testicular tissue of rats, whereas GDL administration was ameliorative.

Keywords: bisphenol A, ganoderma lucidum, rat, sperm, toxicity



Introduction

Bisphenol A (BPA) is an environmental toxicant (Liu et al. 2021) used in the production of polycarbonate plastics (Caglayan et al. 2022). BPA, which has a long persistent life, can migrate into water and food under high temperature, acidity and alkaline conditions, adversely affecting the survival of living organisms (Vandenberg et al. 2009). BPA exposure causes dysfunction and effect various internal organs and systems including the nervous system, gastrointestinal tract, urinary system, and endocrine system (Rochester 2013, Olukole et al. 2019, Valokola et al. 2019, Caglayan et al. 2022, Dökmeci et al. 2022). The reproductive system is the primary target for harmful effects caused by BPA (Behmanesh et al. 2018). BPA is also reported to have genotoxic effects (Naik and Vijayalaxmi 2009). In addition BPA used in polycarbonate production has weak estrogenic activity in vitro and in vivo (Snyder et al. 2000). In a study examining the effect of BPA on early sexual development, a decrease in anogenital range and increased nipple retention in male animals were reported (Christiansen et al. 2014). BPA is an endocrine disruptor that mimics the action of estrogen through estrogen receptor α (ESR1) agonism and disrupts the biosynthesis of androgens and blocks the androgen receptor (AR) as an antagonist (Li et al. 2020). In tissues, BPA primarily increases reactive oxygen species (ROS) in cells and induces cellular oxidative stress (Ho et al. 1998). It has been reported that BPA causes changed in testicular histology in male rats, decreased sperm motility and increased rate of dead, abnormal and apoptotic spermatozoa (Akarca-Dizakar et al. 2020).

Ganoderma lucidum (GDL) is a mushroom widely used in Chinese medicine containing biologically active compounds (Barros et al. 2007, Yuan et al. 2020) including polysaccharides, phenols, proteins, polysaccharide-protein complexes, lipid components and terpenoids (Thu et al. 2020). GDL is reported to be neuroprotective (Qin et al. 2019), antioxidant (Jiang et al. 2021), antidiabetic (Chen et al. 2020), anti-inflammatory effect (Oluwafemi Adetuyi et al. 2020). GDL is also reported to have a protective effect in disorders associated with the male genital tract (Doğan and İpek 2020). In another study, it was reported that GDL protects testicular histology, improves sperm quality, strengthens antioxidant status and prevents apoptosis (Ghajari et al. 2021). However, there is no study investigating the specific effects of GDL on BPA-induced oxidative stress, apoptosis and histopathological changes in rat testis. This study aims to evaluate the antioxidant and anti-apoptotic effects of GDL against BPA-induced testicular dysfunction as well as testosterone level and sperm production and quality.

Materials and Methods

Chemicals, animals, experimental protocol and ethics

Ganoderma lucidum was purchased from the local market in Turkey. Bisphenol A (Cas No: 80-05-7) and other chemicals used in the study were purchased from Sigma Aldrich Chem. Co. Approval for the study was obtained from the Local Ethics Committee for Animal Experiments of Fırat University (Protocol no: 2019/22-228). A total of 24 Sprague Dawley rats obtained from Fırat University Experimental Animals Unit were used in the study. The rats were housed under standard conditions during the study. Rats were given commercial pellet feed and drinking water ad libitum during the study. Bisphenol A contamination was minimized as much as possible for all animals by using glass feed and water containers. All administrations were conducted for 8 weeks. In planning the study for 8 weeks, it was taken into consideration that spermatogenesis in rats lasts 53 days and spermatozoa will be transported along the epididymal duct for a few days (Ke and Tso 1982). The experimental groups were designed as follows; The control group was administered 0.2 mL olive oil by oral gavage. BPA group was administered in 0.2 mL olive oil at a dose of 25 mg/kg/bw by oral gavage (Akarca-Dizakar et al. 2020). GDL group received 300 mg/kg/bw GDL in 0.2 mL olive oil by oral gavage (Hu et al. 2022). BPA+GDL group was administered 25 mg/kg/bw in 0.2 mL olive oil followed by GDL at a dose of 300 mg/kg/bw in 0.2 mL olive oil by oral gavage.

All animals were sacrificed after weighing with a precision scale by decapitation after the end of the experimental procedures. Testicular tissues were rapidly separated from the surrounding tissue, weighed and one testicular tissue was placed in Bouin's solution for histological analysis. The other testicular tissue was placed in deep freezer for biochemical analysis. Blood samples from rats were centrifuged at 3500 rpm for 10 minutes and were stored at -20°C until analysis.

Body weight and testicular weight measurement

The body weights of the rats were measured at the beginning and at the end of the study using a precision scale. Percent body weight change calculated using the formula below.

Percent body weight change = $\frac{\text{Final Weight} - \text{Initial Weight}}{\text{Initial Weight}} \times 100$

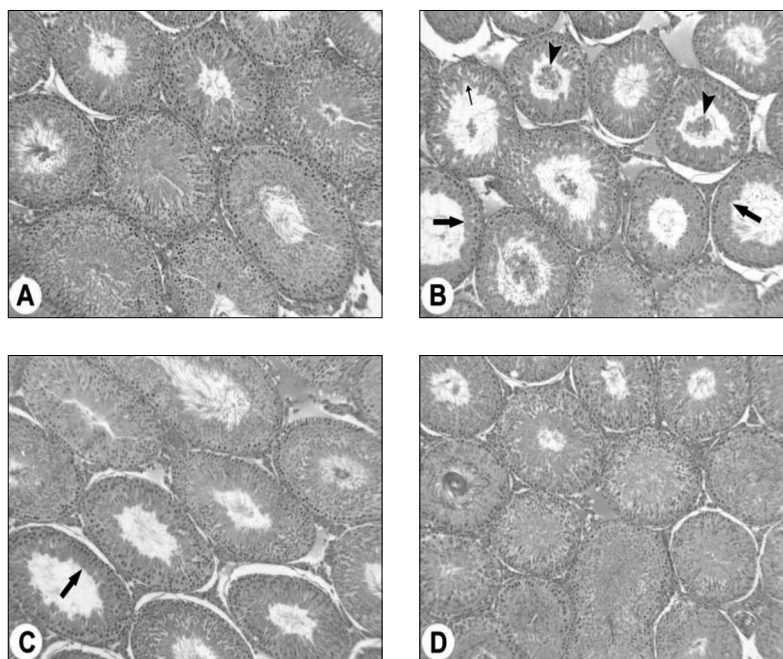


Fig. 1. A – normal appearance of tubulus seminiferus contorti (TSC) in the rat control group, B – degeneration and desquamation in germinal epithelium (arrow heads) and decrease in germinal cell thickness (thick arrows) and disorganization in germinal epithelium (small arrow) in bisphenol A group (BPA), C – decrease in germinal cell thickness (thick arrow) in bisphenol A + ganoderma lucidum (GDL) group, D – normal appearance of TSC in ganoderma lucidum group, Hematoxylin Eosin (HE), x100.

Lipid peroxidation and antioxidant status measurement

Malondialdehyde (MDA) level was used as an index of lipid peroxidation. Serum and testicular tissue lipid peroxidation levels were measured according to the concentration of thiobarbituric acid reactive species (TBARS). Serum and testicular tissue GSH levels, GPx and CAT activities were determined according to the method used in the study of Türk et al. (2008).

Serum testosterone levels analysis

Testosterone levels in serum samples was determined using commercial testosterone kits (Elecsys Testosterone II, Roche, Germany) by ELISA method.

Reproductive parameter analysis

Semen analysis was determined by the methods used by Türk et al. (2007). Sperm motility was determined by placing a slide on a heating plate placed under a light microscope. Total motility value was subjectively scored from 3 different microscope fields and the mean was calculated as percentage. To determine the percentage of dead spermatozoa and abnormal spermatozoa, 10 μ L of sperm samples were placed on a slide, stained with eosin-nigrosin (1.67% eosin, 10% nigrosin and 0.1 M sodium citrate) and examined under a microscope. A total of 200 spermatozoa were exami-

ned on each slide and the results were calculated as percentages. Reproductive organ weights were measured using a precision scale.

Histopathological method

Testicular tissues from sacrificed rats were fixed in Bouin's solution for 48 hours, kept in 80% ethyl alcohol overnight and paraffin blocks were prepared after routine procedures. The 5 micron thick sections taken from the paraffin blocks were stained with Hematoxylin Eosin method (Luna, 1968) and examined under light microscope and the lesions were recorded. Spermatogenesis in Tubulus Seminiferus Contorti (TSC)'s was evaluated by Johnsen testicular scoring method (Fig. 1). In addition, TSC diameters and germinal cell thicknesses were measured by ocular micrometer and statistical comparison was made between the groups.

Immunohistochemical method

Avidin-Biotin-Peroxidase method was used for immunohistochemical analysis (Jahnukainen et al. 2004). The 4 micron thick sections taken from paraffin blocks were deparaffinized with xylene and then dehydrated by passing through graded alcohol series. The sections were incubated in 0.01 M sodium citrate for 20 minutes to expose antigenic receptors, washed with PBS and incubated in 3% hydrogen peroxide pre-

Table 1. Blood and testicular tissue oxidative stress parameters of the rat experimental groups.

	B-MDA (nmol/mL)	T-MDA (nmol/mL)	B-CAT (kU/I)	T-CAT (kU/I)	B-GSH (nmol/mL)	T-GSH (nmol/mL)	B-GPx (IU/I)	T-GPx (IU/I)
Control	2.88±0.43 ^a	0.52±0.12 ^a	179.07±64.23 ^b	26.43±4.88 ^b	0.23±0.17 ^{ab}	0.27±0.04 ^b	3.83±0.33 ^b	13.18±0.75
BPA	4.71±0.57 ^b	4.13±0.47 ^b	99.47±10.28 ^a	19.82±1.62 ^a	0.21±0.18 ^a	0.20±0.01 ^a	3.05±0.30 ^a	12.11±0.53
GDL	2.72±0.23 ^a	2.92±0.30 ^a	192.03±60.46 ^b	27.73±4.65 ^b	0.27±0.04 ^b	0.27±0.01 ^b	3.97±0.33 ^b	14.00±0.76
BPA+GDL	3.18±0.23 ^a	2.99±0.40 ^a	202.21±34.25 ^b	27.32±2.68 ^b	0.23±0.16 ^{ab}	0.26±0.05 ^b	4.01±0.61 ^b	13.36±2.72

Different letters in the same row are statistically significant ($p < 0.001$).

Abbreviations: T: Testis, B: Blood, MDA: Malondialdehyde, GSH: Glutathione, CAT: Catalase, GPx: Glutathione peroxidase

pared with methyl alcohol for 10 minutes to inhibit endogenous peroxidase activity. Nonspecific bindings were blocked in 1% normal goat serum for 1 hour. The sections were then incubated with Bcl-2, Bax and AR primary antibodies diluted with PBS at 1/200, 1/200, 1/100 ratios respectively at 4°C for overnight. Biotinylated secondary antibody was added to the sections washed again in PBS and kept for 10 minutes. The tissues were then washed with PBS and treated with Streptavidin peroxidase for 10 minutes. AEC (3-amino-9-ethylcarbazole) was used as color eliciting substrate. After this solution was applied on the sections, the reaction was stopped as soon as the color change started to develop, and in the last stage, the sections were stained with Mayer Hematoxylin for 2 minutes, washed in tap water, covered with Immun-mount and examined under light microscope at appropriate magnification. Bax and Bcl-2 immunostaining were evaluated semi quantitatively. A total of 25 TSCs in 5 different fields at random 10x magnification were taken into consideration and scoring was performed by giving 0 points for negative staining, 1 point for 0-25% positive cells, 2 points for 26-50% positive cells, 3 points for 51-75% positive cells and 4 points for more than 76% positive cells.

Statistical analyses

All data obtained were presented as mean \pm standard deviation using SPSS (Version 26.0) statistical program. Data showing normal values were analyzed by one-way analysis of variance (ANOVA) and for pairwise comparisons Tukey test was used for analyses. Nonparametric data were analyzed using Kruskal-Wallis test and Mann-Whitney-U test for pairwise comparisons. $p < 0.05$ was considered statistically significant.

Results

Oxidative stress parameters results

Blood and testicular tissue oxidative stress parameter results are presented in Table 1. MDA levels in both blood and testicular tissue were significantly increased by BPA administration. GDL administration significantly decreased both testicular and serum MDA levels ($p < 0.001$). CAT activity in blood and testicular tissue was significantly decreased with BPA administration. GDL administration significantly increased both testicular and serum CAT activity ($p < 0.001$). Blood GSH level and GPx activity were significantly decreased in the BPA group, while there was a statistically significant difference between the other experimental groups ($p < 0.001$). GDL administration significantly increased GSH level in testicular tissue ($p < 0.001$). GDL administration significantly increased serum GPx activity ($p < 0.001$). However, no statistically significant difference was observed between the groups in terms of GSH level and GPx activity in testicular tissue.

Histopathological findings

Histopathological lesions were detected in the BPA alone and BPA + GDL treatment groups, whereas the testes were normal in the control and GDL groups. Microscopically, atrophy characterized by a decrease in TSC germinal cell thickness and diameter, degeneration, disorganization and desquamation of the germinal epithelium, and arrest in spermatogenesis were the main lesions in BPA alone and BPA + GDL groups, although the severity and extent varied (Fig. 1). The mean TSC diameter and germinal cell thickness was found to be decreased in the BPA alone treated group compared to BPA+GDL, control and GDL groups. TSC diameter and germinal cell thickness averages were significantly increased in the BPA+GDL group compared to the BPA alone group, but significantly decreased compared to the control and GDL alone groups ($p < 0.001$). Histologically, there was a significant statistical difference in Johnsen testicular

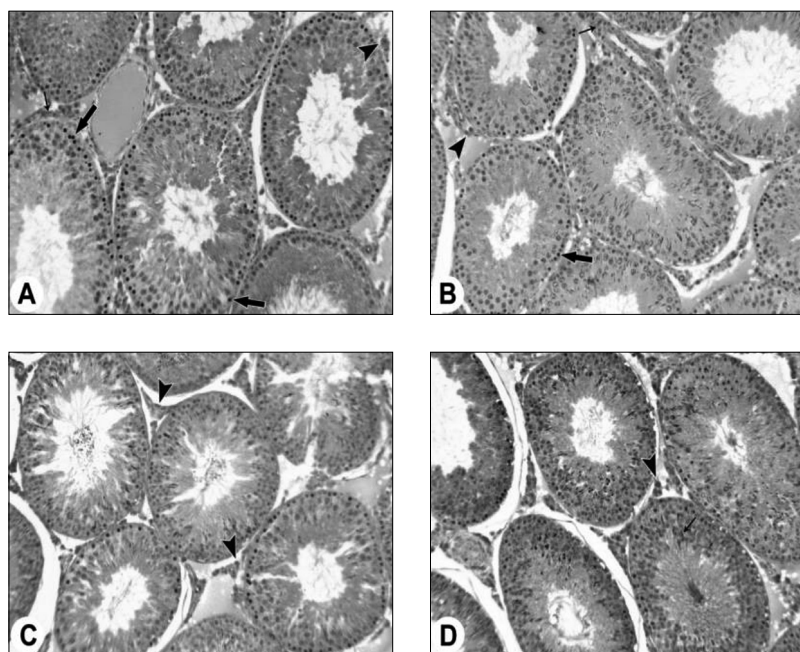


Fig. 2. A – androgen receptor (AR)-positivity in spermatogonia (thick arrows), Leydig cells (arrowheads) and myoepithelial cells (thin arrow) in the control group, B – AR - positivity in Leydig cells (arrowhead) and vascular muscle cells (thin arrow) with few spermatogonia (thick arrow) in the bisphenol A group, C – AR-positivity mostly in spermatogonia and interstitial cells (arrowheads) in bisphenol A + ganoderma lucidum group, D – intense nuclear and cytoplasmic AR-positivity in spermatogonium, Leydig cells (arrowhead) and spermatids in ganoderma lucidum group, Mayer Hematoxylin (MH), x200.

scoring between the control and GDL groups and between the BPA-treated groups ($p < 0.001$). However, no statistical difference was observed between BPA and BPA + GDL groups in terms of Johnsen testicular score.

Immunohistochemical findings

AR positivity in TSCs was generally distributed in the nucleus, less in the cytoplasmic and sometimes in the cell membrane. As cell positivity, AR staining was more intense in germinal epithelium, more intense in primary spermatogonium and less intense in spermatids. AR staining was also detected in vascular endothelial and muscle cells and Leydig cells in the interstitial area and in myoepithelial cells around the TSC. When the groups were evaluated in terms of the number of AR positive germinal epithelium, the highest positivity was found in the control and GDL groups and the lowest positivity was found in the BPA group (Fig. 2). In the BPA + GDL group, AR positivity was lower than in the control and GDL groups, and AR positivity was detected in more cells than in the BPA alone group ($p < 0.001$).

Bax positivity was observed both in nuclei and cytoplasmically in TSCs. Bax immunostaining was detected in all cells of the germinal epithelium, while the most intense staining was observed in spermatocytes and spermatids. In addition, significant Bax positivity was observed in Leydig cells in the interstitial area. When the groups were analyzed in terms of the

intensity and distribution of immunostaining for Bax antibodies, it was observed that apoptosis was most intense in the BPA group and least in the control and GDL groups (Fig. 3). Bax positivity in the BPA + GDL group was similar in intensity compared to the other groups.

Bcl-2 positivity, like Bax positivity, was found mostly in the nucleus and to a lesser extent in the cytoplasm. In TSC, Bcl-2 positivity, which is an antiapoptotic protein, was generally determined in spermatogonium and to a lesser extent in spermatids in germinal epithelium. Lower and moderate Bcl-2 positivity was found in Leydig and myoepithelial cells. No statistically significant difference was observed between the groups in terms of Bcl-2 positivity (Fig. 4).

Histopathological evaluation, TSC's diameters, germinal cell thickness and Johnsen testicular scoring values by ocular micrometer were showed in Fig 5.

Percentage of body weight change and relative reproductive organ weights results

Relative reproductive organ weights and testosterone levels results are shown in Table 2. There was no statistically significant difference between the groups in terms of percentage body weight change. When testis and epididymis weighed, it was determined that the highest value was observed in the control and BPA groups and the lowest value was observed in the GDL

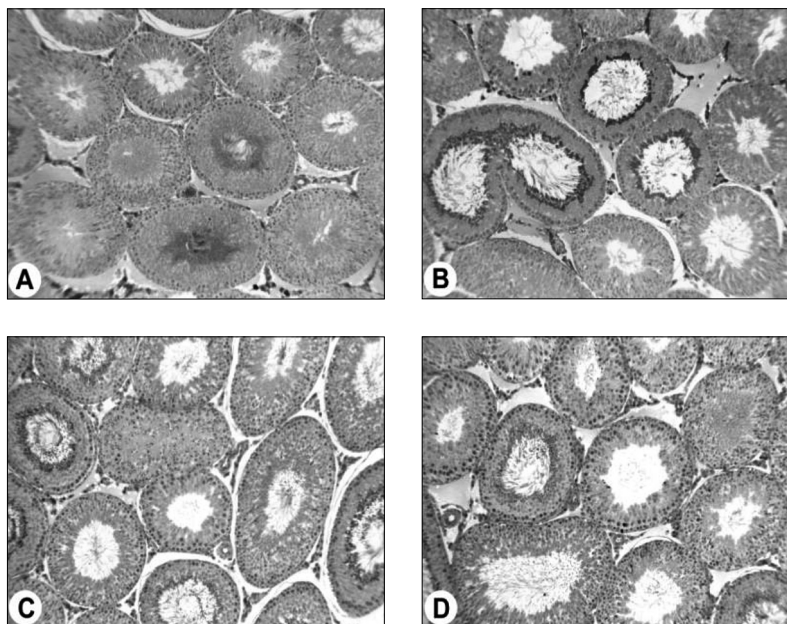


Fig. 3. A – Weak Bax positivity in TSC germinal epithelium and interstitial cells in control group, B – Significant Bax positivity in spermatocytes and interstitial cells together with germinal cells in TSCs in bisphenol A group, C – Moderate Bax positivity in interstitial cells together with germinal epithelium in bisphenol A + ganoderma lucidum group, D – Weak Bax immunostaining in TSC in ganoderma lucidum group, MH, x100.

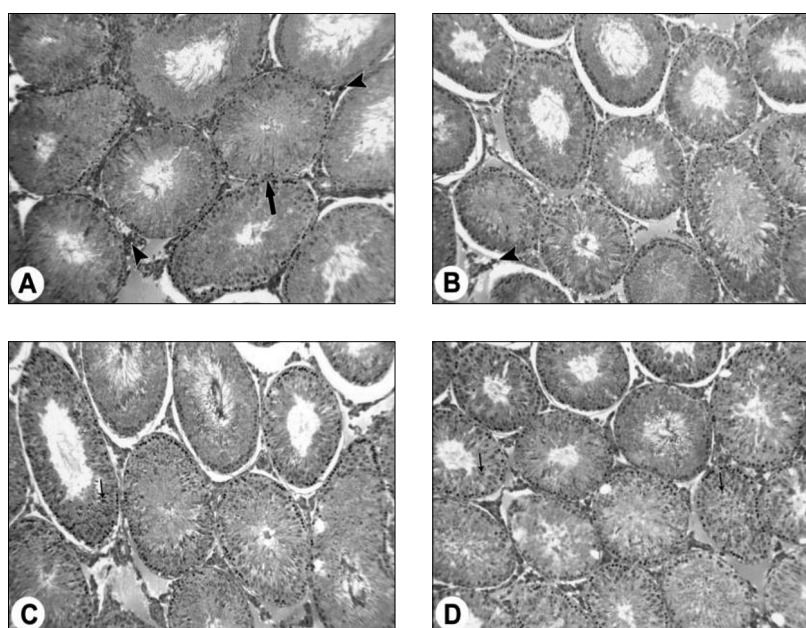


Fig. 4. A – Bcl-2 positivity in spermatogonium and spermatids in TSC germinal epithelium, myoepithelium (thick arrow) and Leydig cells (arrowhead) in control group, B – Weak Bcl-2 immunostaining in spermatogonium and Leydig cells (arrowhead) in TSC in bisphenol A group, C – Bcl-2 positivity in spermatogonium and spermatids (small arrow) in germinal epithelium and interstitial cells in bisphenol A + ganoderma lucidum group, D – Significant Bcl-2 positivity in spermatogonium and spermatids (small arrows) in ganoderma lucidum group, MH, x100.

groups ($p < 0.001$). Vesicula seminalis gland weight was decreased in the BPA group compared to the other experimental groups ($p < 0.001$). While testosterone levels were significantly decreased with BPA administration, they were increased in the treatment groups ($p < 0.001$).

Spermatological analysis results

Semen analysis results are shown in Table 2. It was determined that total motility and epididymal sperm density values decreased significantly in BPA group, whereas GDL administration increased total motility ($p < 0.001$). There was no statistically significant difference between the groups in abnormal sperm ratio.

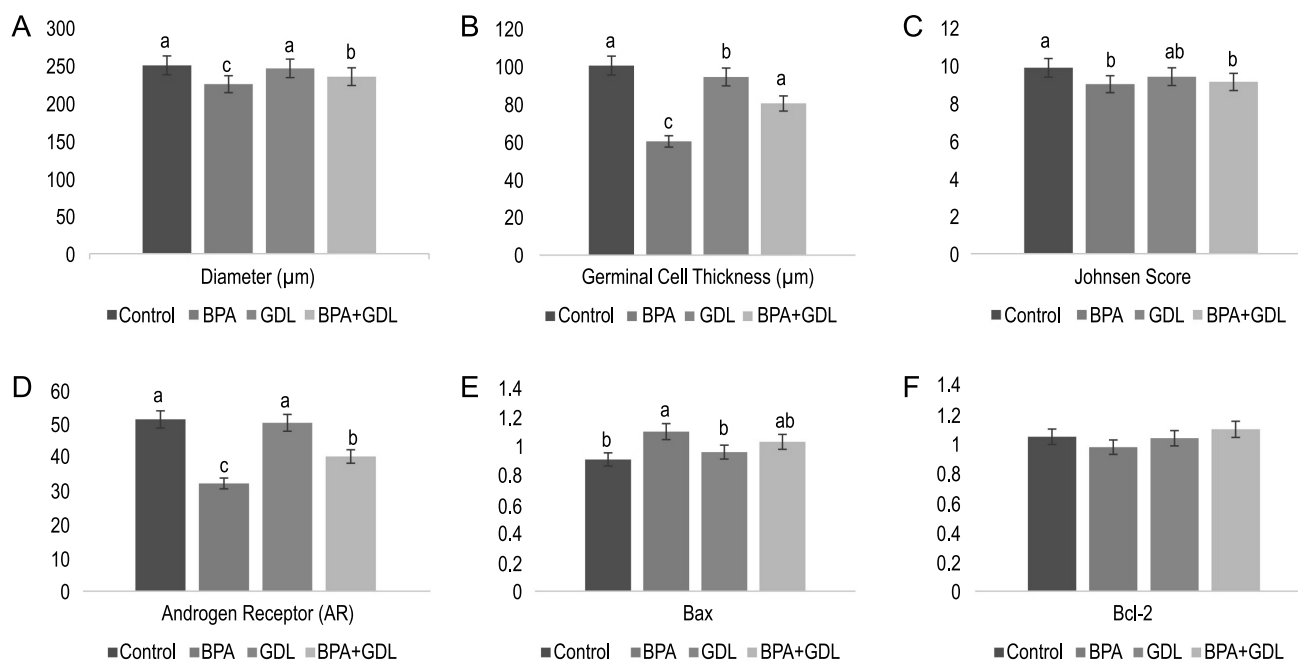


Fig. 5. TSC diameter, germinal cell thickness, Johnsen testicular score, androgen receptor, Bax and Bcl-2 values of experimental groups.

Table 2. Relative weights of male reproductive organs and testosterone levels for rat experimental groups.

	PBWC (g)	RTW (g)	LTW (g)	REW (g)	LEW (g)	VSW (g)	PW (g)	Testosterone (ng/dl)	Motility (%)	Density (x10 ⁶)	Abnormal spermatozoa rate (%)
Control	42.01±6.73	1.59±0.12 ^b	1.56±0.11 ^b	0.81±0.06 ^b	0.79±0.06 ^b	1.37±0.14 ^{ab}	0.49±0.08	237±38.74 ^b	71.11±8.14 ^a	103.66±19.57 ^{ab}	7.5±1.87
BPA	43.54±4.55	1.54±0.70 ^{ab}	1.51±0.80 ^{ab}	0.73±0.04 ^b	0.70±0.09 ^{ab}	1.14±0.07 ^a	0.44±0.05	110.66±58.66 ^a	62.21±10.46 ^a	88±19.01 ^a	7.66±1.75
GDL	40.36±5.64	1.37±0.13 ^a	1.36±0.14 ^a	0.59±0.06 ^a	0.59±0.05 ^a	1.38±0.24 ^{ab}	0.36±0.01	283.83±28.33 ^b	83.88±5.74 ^b	129.67±26.51 ^b	6.5±3.01
BPA+GDL	43.05±4.29	1.43±0.80 ^{ab}	1.40±0.10 ^{ab}	0.61±0.08 ^a	0.61±0.08 ^a	1.42±0.14 ^b	0.37±0.09	271.50±32.33 ^b	85.55±5.02 ^b	110.17±31.34 ^{ab}	7.5±1.04

Different letters in the same row are statistically significant ($p < 0.001$).

Abbreviations: PBWC: Percent of body weight change. RTW: Right testis weight. LTW: Left testis weight. REW: Right epididymis weight. VSW: Vesicula seminalis weight. PW: Prostate weight.

Discussion

BPA is a substance commonly used in the production of polycarbonate plastics to which living organisms are frequently exposed (Abraham and Chakraborty 2020). Various studies have been conducted against this toxicity caused by BPA (Iida et al. 2003, Caglayan et al. 2022). The aim of this study was to determine the histopathological, biochemical and spermatological effects of GDL against BPA-induced testicular dysfunction.

Overproduction of oxidant molecules and inadequacy in the antioxidant defence system disrupts the oxidative balance (Tuncer et al. 2023). MDA, which is an indicator of LPO, and GSH, CAT and GPx, which are antioxidant defense system elements, provide cellular antioxidant balance (Akarsu et al. 2023). Studies have reported that BPA causes an increase in MDA

level and a decrease in GSH level (Othman et al. 2016, Elashal et al. 2024). In the present study, a significant increase in MDA levels were observed in both blood and testicular tissues in the BPA group compared to the other groups ($p < 0.001$). There was a significant decrease in MDA level in the BPA+GDL group compared to the BPA group ($p < 0.001$). CAT activity and GSH levels were also significantly decreased in the BPA group in blood and testicular tissue ($p < 0.001$). Blood GPx activity was significantly decreased in the BPA group ($p < 0.001$), while no statistically significant difference was observed in testicular tissue. GSH level, CAT activity and GPx activity were increased in BPA+GDL group. It has been reported in studies that GDL is a free radical scavenger (Zhong et al. 2015).

Peroxidation of unsaturated fatty acids in the sperm plasma membrane causes changes in sperm morphology (Akarca-Dizakar et al. 2020). The pathway

induced by members of the Bcl-2 protein family, including Bax and Bcl-2, is a marker of apoptosis (Kucukler et al. 2020). Imbalance in the Bax/Bcl-2 ratio causes an increase in cytochrome c levels in the cytoplasm, activating caspase enzymes and triggering apoptosis (Tartik et al. 2016). Oxidative stress causes various cellular and DNA damages and damages mitochondrial DNA, which lacks histone wrapping and repair mechanisms. Mitochondrial damage leads to increased oxidative stress and decreased ATP levels, which in turn leads to activation of the cell death pathway (Li et al. 2022). It has been reported in previous studies that BPA may cause apoptosis in the testes (Wang et al. 2010). In our study, it was observed that apoptosis was triggered by the increase in Bax ratio and decrease in Bcl-2 ratio in the BPA group, whereas apoptosis was at normal levels in the GDL group. This situation is thought to trigger apoptosis after oxidative damage produced by BPA and inhibit apoptosis thanks to the antioxidant properties of GDL.

AR plays a role in sexual differentiation and male reproductive function (You and Sar 1998). The most potent androgen in the body is testosterone (Behairy et al. 2020). The most important metabolic pathway of testosterone is binding to the AR of target tissues. Another way is that testosterone can be aromatized to estradiol (E2) under estrogenic effects (El Osta et al. 2016). BPA shows antagonist effect by binding to ARs. Together with binding to ARs, it disrupts the hypothalamic-pituitary-testicular axis and modulates the activity of testicular steroidogenesis (Barbagallo et al. 2020). In the present study, testicular tissue AR levels and blood testosterone levels decreased significantly in the BPA group. This was interpreted as a result of the estrogenic effect of BPA. However, both AR and testosterone levels were normal in GDL groups. GDL prevented the toxic effects of BPA by protecting the blood-testis barrier and accordingly, it was interpreted as a decrease in estrogenic effects.

Sperm motility is one of the main indicators of fertilization capacity (Akarsu et al. 2023). Sperm maturation in the epididymis, where spermatozoa gain fertilizing capacity and motility, is important (Sullivan and Mieusset 2016) and it is reported that this period lasts approximately 53 days in rats (Ke and Tso 1982). In a previous study, it is stated that BPA decreases sperm quality (Akarca-Dizakar et al. 2020). In our study, 8 weeks of BPA and GDL administration was selected in terms of the completion of spermatogenesis and the fact that BPA administration caused a decrease in sperm motility and epididymal sperm density is an indication that spermatogenesis is affected and sperm motility in the epididymal passage is negatively affected. In another study, it was reported that sperm quality

increased in rats thanks to GDL administration (Ozmen et al. 2021). In our findings, the improvement of BPA-induced low epididymal sperm quality by GDL administration confirms this.

In conclusion, BPA-induced testicular damage was determined by biochemical, histopathological and spermatological analyses. As a result of oxidative stress, an increase in apoptosis, spermatogenesis and steroidogenesis were impaired. GDL administration was found to be protective against these changes caused by BPA at cellular levels. This study determined that GDL has a protective role and therapeutic effect against BPA-induced testicular damage.

References

- Abraham A, Chakraborty P (2020) A review on sources and health impacts of bisphenol A. *Rev Environ Health* 35: 201-210.
- Akarca Dizakar SÖ, Erdoğan D, Peker T, Coşkun Akçay N, Türkoğlu İ, Eşmekaya MA, Ömeroğlu S (2020) Effects of co-administered melatonin, fructose and bisphenol A (BPA) on rat epididymis and sperm characteristics. *Biotech Histochem* 95: 18-26.
- Akarsu SA, Acısu TC, Güngör İH, Çakır Cihangiroğlu A, Koca RH, Türk G, Sönmez M, Gür S, Fırat F, Esmir Duruel HE (2023) The effect of luteolin on spermatological parameters, apoptosis, oxidative stress rate in freezing rabbit semen. *Pol J Vet Sci* 26: 91-98.
- Akarsu SA, Gür C, İleritürk M, Akaras N, Küçükler S, Kandemir FM (2023) Effect of syringic acid on oxidative stress, autophagy, apoptosis, inflammation pathways against testicular damage induced by lead acetate. *J Trace Elem Med Biol* 80: 127315.
- Barros L, Baptista P, Estevinho LM, Ferreira IC (2007) Effect of fruiting body maturity stage on chemical composition and antimicrobial activity of *Lactarius* sp. mushrooms. *J Agric Food Chem* 55: 8766-8771.
- Behairy A, El-Sharkawy NI, Saber TM, Soliman MM, Metwally MM, Abd El-Rahman GI, Abd-Elhakim YM, El Deib MM (2020) The modulatory role of vitamin C in boldenone undecylenate induced testicular oxidative damage and androgen receptor dysregulation in adult male rats. *Antioxidants* 9: 1053.
- Behmanesh MA, Najafzadehvarzi H, Poormoosavi SM (2018) Protective effect of aloe vera extract against bisphenol A induced testicular toxicity in wistar rats. *Cell J* 20: 278-283.
- Çaglayan C, Kandemir FM, Ayna A, Gür C, Küçükler S, Darendelioğlu E (2022) Neuroprotective effects of 18beta-glycyrrhetic acid against bisphenol A-induced neurotoxicity in rats: involvement of neuronal apoptosis, endoplasmic reticulum stress and JAK1/STAT1 signaling pathway. *Metab Brain Dis* 37: 1931-1940.
- Chen M, Xiao D, Liu W, Song Y, Zou B, Li L, Li P, Cai Y, Liu D, Liao Q, Xie Z (2020) Intake of *Ganoderma lucidum* polysaccharides reverses the disturbed gut microbiota and metabolism in type 2 diabetic rats. *Int J Biol Macromol* 155: 890-902.
- Christiansen S, Axelstad M, Boberg J, Vinggaard AM, Pedersen GA, Hass U (2014) Low-dose effects of bisphenol A on early sexual development in male and female rats. *Reproduction* 147: 477-487.

- Doğan G, İpek H (2020) The protective effect of *Ganoderma lucidum* on testicular torsion/detorsion-induced ischemia-reperfusion (I/R) injury. *Acta Cir Bras* 35: e202000103
- Dökmeci AH, Karaboğa İ, Güzel S, Erboğa ZF, Yılmaz A (2022) Toxicological assessment of low-dose bisphenol A, lead and endosulfan combination: Chronic toxicity study in male rats., *Environ Sci Pollut Res* 29: 10558-10574.
- El Osta R, Almont T, Diligent C, Hubert N, Eschwège P, Hubert J (2016) Anabolic steroids abuse and male infertility. *Basic Clin Androl* 26: 2.
- Elashal MH, Abd El-Wahed AA, Mohamed MA, Hamad R, Abd Eldaim MA, Khalifa SA, Aldahmash B, El-Seedi HR, El-Aarag B (2024) Apilarnil ameliorates Bisphenol A-induced testicular toxicity in adult male rats via improving antioxidant potency and PCNA expression. *Reprod Toxicol* 125: 108570.
- Ghajari G, Nabiuni M, Amini E (2021) The association between testicular toxicity induced by Li₂Co₃ and protective effect of *Ganoderma lucidum*: Alteration of Bax and c-Kit genes expression. *Tissue Cell* 72: 101552.
- Ho YS, Magnenat JL, Gargano M, Cao J (1998) The nature of antioxidant defense mechanisms: a lesson from transgenic studies. *Environ Health Pers* 106(Suppl 5): 1219-1228.
- Hu Y, Wang SX, Wu FY, Wu KJ, Shi RP, Qin LH, Lu CF, Wang SQ, Wang FF, Zhou S (2022) Effects and mechanism of *Ganoderma lucidum* polysaccharides in the treatment of diabetic nephropathy in streptozotocin-induced diabetic rats. *BioMed Res Int* 2022: 4314415.
- Iida H, Maehara K, Doiguchi M, Mōri T, Yamada F (2003) Bisphenol A-induced apoptosis of cultured rat Sertoli cells. *Reprod Toxicol* 17: 457-464.
- Jahnukainen K, Chrysis D, Hou M, Parvinen M, Eksborg S, Söder O (2004) Increased apoptosis occurring during the first wave of spermatogenesis is stage-specific and primarily affects midpachytene spermatocytes in the rat testis. *Biol Reprod* 70: 290-296.
- Jiang G, Lei A, Chen Y, Yu Q, Xie J, Yang Y, Yuan T, Su D (2021) The protective effects of the *Ganoderma atrum* polysaccharide against acrylamide-induced inflammation and oxidative damage in rats. *Food Funct* 12: 397-407.
- Ke YB, Tso WW (1982) Variations of gossypol susceptibility in rat spermatozoa during spermatogenesis. *Int J Fertil* 27: 42-46.
- Kucukler S, Caglayan C, Darendelioglu E, Kandemir FM (2020) Morin attenuates acrylamide-induced testicular toxicity in rats by regulating the NF-KB, Bax/Bcl-2 and PI3K/Akt/mTOR signaling pathways. *Life Sci* 261: 118301.
- Li X, Wen Z, Wang Y, Mo J, Zhong Y, Ge RS (2020) Bisphenols and Leydig cell development and function. *Front Endocrinol* 11: 447.
- Li Y, Liang W, Han Y, Zhao W, Wang S, Qin C (2022) Triterpenoids and polysaccharides from *Ganoderma lucidum* improve the histomorphology and function of testes in middle-aged male mice by alleviating oxidative stress and cellular apoptosis. *Nutrients* 14: 4733.
- Liu X, Wang Z, Liu F (2021) Chronic exposure of BPA impairs male germ cell proliferation and induces lower sperm quality in male mice. *Chemosphere* 262: 127880.
- Luna LG (1968) Manual of histologic staining methods of the Armed Forces Institute of Pathology 1-258.
- Naik P, Vijayalaxmi KK (2009) Cytogenetic evaluation for genotoxicity of bisphenol-A in bone marrow cells of Swiss albino mice. *Mut Res* 676: 106-112.
- Olukole SG, Lanipekun DO, Ola-Davies EO, Oke BO (2019) Melatonin attenuates bisphenol A-induced toxicity of the adrenal gland of Wistar rats. *Environ Sci Pollut Res* 26: 5971-5982.
- Oluwafemi Adetuyi B, Olamide Okeowo T, Adefunke Adetuyi O, Abraham Adebisi O, Ogunlana OO, Janet Oretade O, Marraiki N, Beshbishy AM, Welson NN, Batiha GE (2020) *Ganoderma lucidum* from red mushroom attenuates formaldehyde-induced liver damage in experimental male rat model. *Biology* 9: 313.
- Othman AI, Edrees GM, El-Missiry MA, Ali DA, Aboel-Nour M, Dabdoub BR (2016) Melatonin controlled apoptosis and protected the testes and sperm quality against bisphenol A-induced oxidative toxicity. *Toxicol Ind Heal* 32: 1537-1549.
- Ozmen MF, Seker U, Yavas M, Cirit U, Akdag MZ (2021) Effects of *ganoderma lucidum* and melatonin on sperm in rats exposed to electromagnetic field. *Int J Radiat Res* 19: 121-126.
- Qin LH, Wang C, Qin LW, Liang YF, Wang GH (2019) Spore powder of *Ganoderma lucidum* for Alzheimer's disease: A protocol for systematic review. *Medicin* 98: e14382.
- Rochester JR (2013) Bisphenol A and human health: a review of the literature. *Reprod Toxicol* 42: 132-155.
- Snyder RW, Maness SC, Gaido KW, Welsch F, Sumner SC, Fennell TR (2000) Metabolism and disposition of bisphenol A in female rats. *Toxicol Appl Pharmacol* 168: 225-234.
- Sullivan R, Mieusset R (2016) The human epididymis: its function in sperm maturation. *Hum Reprod Update* 22: 574-587.
- Tartik M, Darendelioglu E, Aykutoglu G, Baydas G (2016) Turkish propolis suppresses MCF-7 cell death induced by homocysteine. *Biomed Pharmacother* 82: 704-712.
- Thu Z M, Myo KK, Aung HT, Clericuzio M, Armijos C, Vidari G (2020) Bioactive phytochemical constituents of wild edible mushrooms from Southeast Asia. *Molecules* 25: 1972.
- Tuncer SÇ, Akarsu SA, Küçükler S, Gür C, Kandemir, FM (2023) Effects of sinapic acid on lead acetate-induced oxidative stress, apoptosis and inflammation in testicular tissue. *Environ Toxicol* 38: 2656-2667.
- Türk G, Ateşşahin A, Sönmez M, Çeribaşı AO, Yüce A (2008) Improvement of cisplatin-induced injuries to sperm quality, the oxidant-antioxidant system, and the histologic structure of the rat testis by ellagic acid. *Fertil Steril* 89 (Supply 5): 1474-1481.
- Türk G, Ateşşahin A, Sönmez M, Yüce A, Çeribaşı AO (2007) Lycopene protects against cyclosporine A-induced testicular toxicity in rats. *Theriogenology* 67: 778-785.
- Valokola MG, Karimi G, Razavi BM, Kianfar M, Jafarian AH, Jaafari MR, Imenshahidi M (2019) The protective activity of nanomicelle curcumin in bisphenol A-induced cardiotoxicity following subacute exposure in rats. *Environ Toxicol* 34: 319-329.
- Vandenberg LN, Maffini MV, Sonnenschein C, Rubin BS, Soto AM (2009) Bisphenol-A and the great divide: a review of controversies in the field of endocrine disruption. *Endoc Rev* 30: 75-95.
- Wang Q, Zhao XF, Ji YL, Wang H, Liu P, Zhang C, Zhang Y, Xu DX (2010) Mitochondrial signaling pathway is also involved in bisphenol A induced germ cell apoptosis in testes. *Toxicol Lett* 199: 129-135.
- Zhong D, Wang H, Liu M, Li X, Huang M, Zhou H, Lin S, Lin Z, Yang B (2015) *Ganoderma lucidum* polysaccharide peptide prevents renal ischemia reperfusion injury via counteracting oxidative stress. *Sci Rep* 5: 16910.