

## Imiquimod as an effective treatment method of advanced basal cell carcinoma affecting 100-year-old man — case report with literature review

PATRYCJA PASIEKA<sup>1</sup>, ELŻBIETA WÓJTOWICZ<sup>2,3</sup>, WOJCIECH WYSOCKI<sup>4,5,6</sup>,  
ANNA WOJAS-PELC<sup>1</sup>, ANDRZEJ K. JAWOREK<sup>1</sup>

<sup>1</sup> Department of Dermatology and Allergology, University Hospital, Krakow, Poland

<sup>2</sup> Skin Cancer and Melanoma Treatment Center, 5th Military Clinical Hospital in Krakow, Krakow, Poland

<sup>3</sup> Polish Dermatoscopy Group

<sup>4</sup> Department of Oncological Surgery, 5th Military Clinical Hospital in Krakow, Krakow, Poland

<sup>5</sup> Chair of Surgery, Faculty of Medicine and Health Sciences, Andrzej Frycz Modrzewski Krakow University, Krakow, Poland

<sup>6</sup> Maria Skłodowska-Curie Memorial National Research Institute of Oncology, Warsaw, Poland

**Corresponding author:** Andrzej Kazimierz Jaworek, M.D., Ph.D.  
Department of Dermatology, Jagiellonian University Medical College  
ul. Botaniczna 3, 31-501 Kraków, Poland  
Phone: +48 694 486 112; E-mail: andrzej.jaworek@uj.edu.pl

**Abstract:** Introduction: Basal cell carcinoma (BCC) is the most common skin cancer with increasing prevalence in the last years. The most important risk factor for development of BCC is exposure to UV radiation. Surgical excision remains the first line treatment, but there are some non-surgical methods of treatment.

The aim of this study is to present a case of 100-year-old patient with advanced BCC in temporal area who refused surgical treatment. The noninvasive treatment with imiquimod was successful.

Case presentation: The 100-year-old male patient was admitted to the dermatological outpatient clinic with an ulceration within the forehead, which had been increasing in size for 3 years. Physical examination revealed shallow irregular ulceration with erythematous pearly-shaped borders in the right temporal area measuring ca. 1.5 cm × 2 cm. Dermatoscopic examination of the lesion showed arborising vessels on the semitransparent background, white structureless area and numerous erosions, leading to an initial diagnosis of BCC. Patient refused any surgical interventions within the lesion including skin biopsy. Consequently, treatment with 5% imiquimod was initiated with cream application for 8 weeks, once daily 5 times a week. 8 months after termination of treatment there were no clinical and dermoscopic signs of recurrence of BCC. The patient remains under dermatological follow-up.

Conclusions: Imiquimod seemed to be effective and well-tolerated in treatment of advanced BCC in elderly patients and should be considered in case of contraindications to surgery. Patients with history of skin cancer require long-term observation for local recurrence.



**Keywords:** basal cell carcinoma, BCC, imiquimod.

**Submitted:** 17-Jun-2024; **Accepted in the final form:** 30-Aug-2024; **Published:** 26-Dec-2024.

## Introduction

Basal cell carcinoma (BCC) is the most common skin cancer and the most common malignant cancer among Caucasian people. It has to be emphasized that the incidence of BCC has been increasing over the years [1]. The Polish Cancer Registry (PCR) reported that more than 16% of cases of non-melanoma skin cancer (NMSC) in Poland in 2021 was diagnosed in patients older than 85 years old [2]. People aged 85 years or more represented 8% of Polish population in 2022 [3].

The risk factors of development of BCC include excessive exposure to ultraviolet (UV) radiation, especially among people characterized by phenotype I or II in the Fitzpatrick scale, genetic factors, autoimmune diseases, immunosuppression, ionizing radiation, polycyclic aromatic hydrocarbons, arsenic [1, 4]. Due to local malignancy the tumor is capable of infiltrating the surrounding tissue which results in destruction of structures, such as bones and cartilage, or ulceration. Surgical treatment of advanced BCCs (particular of those localized on face) might be challenging due to the need to achieve a satisfactory aesthetic results while simultaneously maintaining the complete removal [5]. Although the risk of metastases in case of BCC is determined as low (0.0028–0.5% of BCC cases), the 5-year recurrence rate after excision is estimated to be as high as roughly 2–10% of cases [4, 6, 7]. Surgical excision of the lesion with safety margins of healthy tissues remains a “gold standard” in treatment of BCC, although non-surgical treatment is also considered a viable option [4].

The aim of the article is to report a case of 100-year-old male patient with advanced BCC in temporal area who refused any surgical procedures within the lesion. Taking patient’s decision into consideration, the noninvasive treatment with imiquimod was initiated with successful effect.

## Case presentation

The 100-year-old male patient, a retired farmer, was admitted to the dermatological outpatient clinic with an ulceration within the forehead, which had been increasing in size for 3 years. Family history of NMSC and melanoma was negative. Patient history was marked with unspecified coagulation disorder, inguinal hernia, hypercholesterolemia, benign prostatic hyperplasia, recurrent vertigo. His medications included acenocoumarol, omeprazole, vinpocetine, betahistine, finasteride, trimetazidine, atorvastatin, sulodexide. The patient denied allergies and history of drug side effects.

Physical examination revealed shallow irregular ulceration with erythematous pearly-shaped borders in the right temporal area measuring ca. 1.5 cm × 2 cm (Fig. 1A). Dermatoscopic examination of the lesion showed arborising vessels on the semitransparent background, white structureless area and numerous erosions (Fig. 1B). No other suspicious lesions was found. An initial diagnosis of BCC. Skin biopsy and histopathological examination was recommended to confirm diagnosis of BCC. Patient was fully informed about the suspicion of NMSC and planned surgical treatment. He refused (twice at one month interval) any surgical interventions within the lesion including skin biopsy and signed refusal of treatment form. Then non-surgical treatment methods were discussed

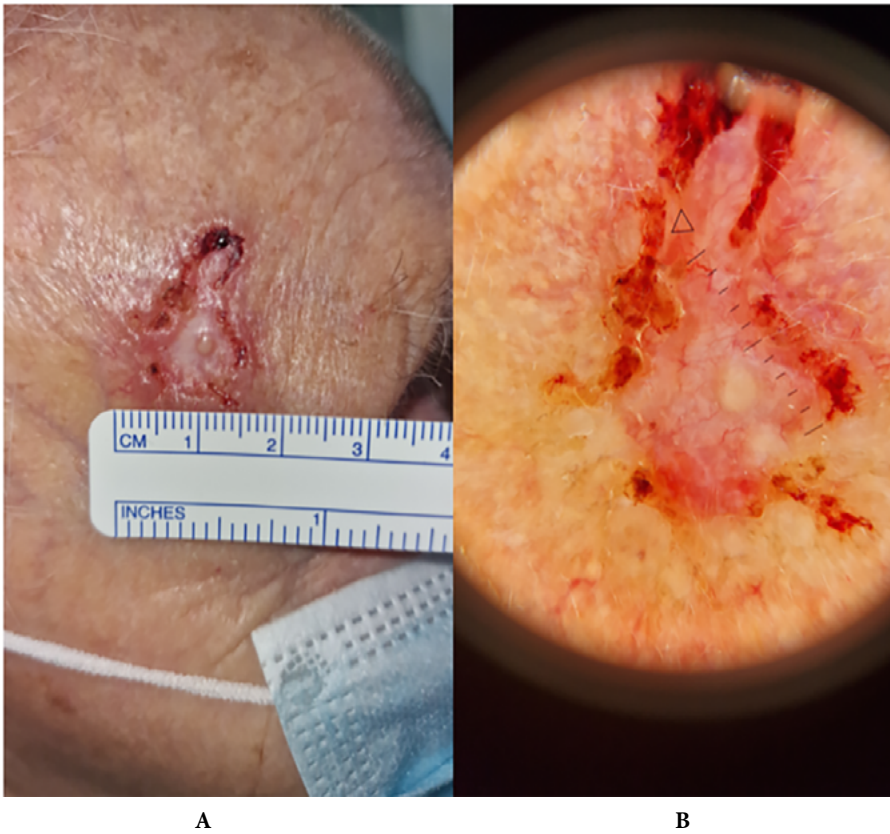


Fig. 1. BCC in the right temporal area. Clinical and dermoscopic presentation.

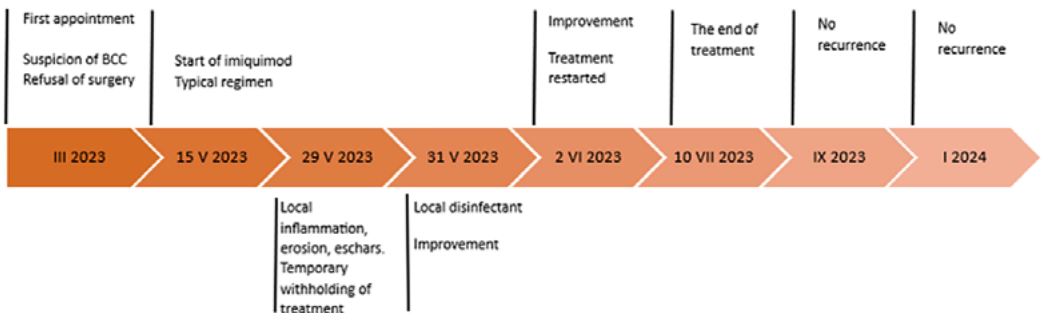
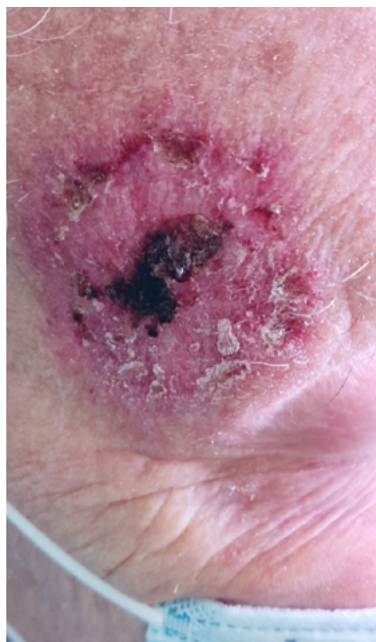
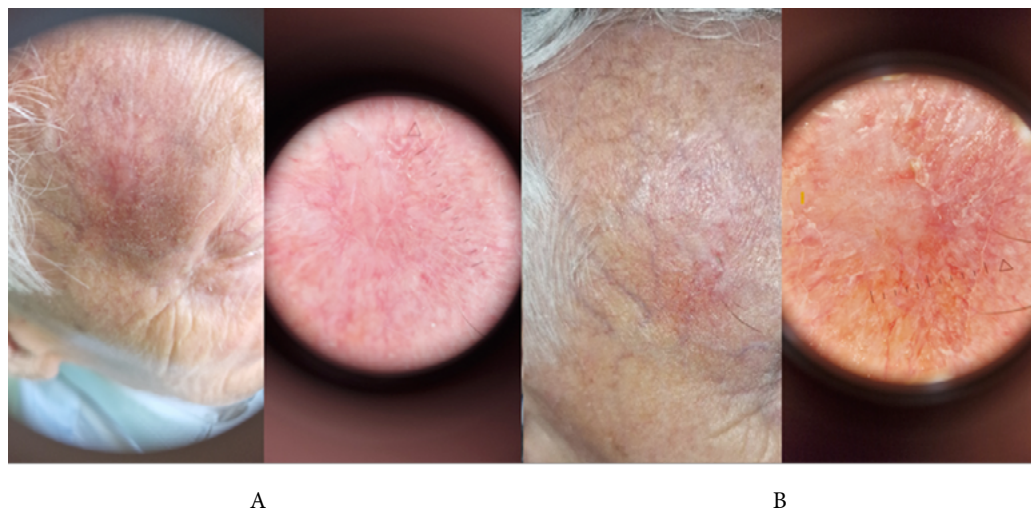


Fig. 2. Course of treatment of BCC with imiquimod.



**Fig. 3.** Clinical presentation of the lesion in second week of treatment.



**Fig. 4.** Clinical outcome after the end of therapy — after 16 weeks (A) and after 8 months (B), respectively.

with the patient. Treatment with 5% imiquimod was initiated. Cream was applied for 8 weeks, 5 times a week, once daily in the evening for 8 hours (Fig. 2). In the second week of treatment acute inflammatory redness with exudate and eschars were observed within the lesion (Fig. 3). The treatment was temporarily suspended and restarted after local improvement. In the regular control after 16 weeks and 8 months after termination of treatment there were no clinical and dermoscopic signs of recurrence of BCC (Fig. 4 A, B). The patient remains in dermatological follow-up.

## Discussion

BCC as a skin cancer is characterized by local malignancy and very low risk of metastases. However, due to the local tissue destruction and tendency to cancer recurrence the therapy of BCC is often challenging and associated with high risk of complications [1].

Wehner *et al.* estimated increase of area of BCC at a level of 2.5 mm<sup>2</sup> per month [8]. According to literature local advancement of BCC was usually a result of postponed admission to the doctor due to low skin cancer awareness or previous treatment failure [5, 6, 9, 10]. BCC large in size (>2 cm) in comparison with the smaller ones (<2 cm) is characterized by higher risk of recurrence (8.9% vs. 0.8%  $p < 0.001$ ) and formation of metastases (6.5% vs. 0%,  $p < 0.001$ ) [11].

There are some treatment methods of BCC that could be surgical or non-surgical. Table 1 contains brief summary of those methods [4, 6, 12].

Due to the fact that frequency of BCC increases with age, there are many articles regarding difficulties with management of BCC in the older population. Those difficulties might be associated with advanced age and involve comorbidities, polypharmacy, bad general condition, cachexia, low compliance [13–16].

Authors would like to underline that age should not be the only criterion during planning the management of BCC but has to be taken into consideration along with patients' quality of life, life expectancy, functional and socioeconomic status, comorbidities and patient preferences [14, 16–18]. Martin *et al.* reported that patients age did not significantly influence their preferences, although older patients were more concerned about duration of wound healing when compared to younger patients [19]. According to another study, the refusal of surgery seemed to be more prevalent among older patients, which leads to need for consideration alternative treatment methods [14].

Imiquimod, characterized by chemical structure of imidazoquinoline, has been used in dermatology since 1997. It was first approved by the Food and Drug Administration (FDA) for the treatment of genital warts. In 2004, its indications were extended to include actinic keratoses (AK) and superficial BCC [20]. As a modulator of the immune response, imiquimod exhibits pleiotropic effects on both innate and acquired immunity mechanisms. The mechanism of action of imiquimod involves activation of the immune response through binding to Toll-like receptors 7 (TLR-7), which are expressed on numerous cells of the immune system. The TLR7-imiquimod complex activates the signaling cascade and consequently the production of the NF- $\kappa$ B protein complex, which plays a key role in regulation of the immune response. Imiquimod triggers maturation and migration of dendritic cells, activation of antigen-presenting cells (APC), increased production of pro-inflammatory cytokines, such as IFN-gamma, IL-12 and TNF-alpha, and activation of T-lymphocyte-dependent responses. One of the effects of imiquimod at the cellular level is increased expression of CD95 receptors (called "death receptors") on the tumor cells. The complex of the receptor with the CD95 ligand (CD95-CD95L) results in activation of the tumor

**Table 1.** Treatment methods of BCC [4, 6, 12].

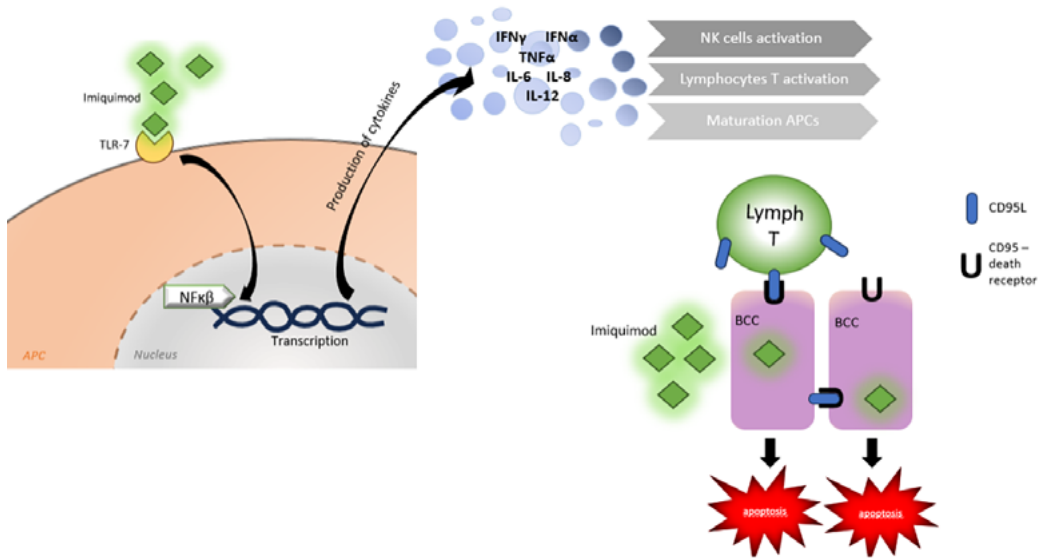
Treatment method	Description
Surgical excision	A “gold standard” of treatment. Excision of the lesion with safety margins of 4 mm followed by histopathological examination with assessment of margins with regard to radicalness. In high risk BCC excision should be performed with 10 mm margins) Mohs micrographic surgery — excision with intra-operative analysis of margins with regard to radicalness
Curettage and electrodesiccation, cryotherapy	Destructive therapies In case of small, low risk superficial and nodular BCC
Laser	Not recommended, insufficient evidence
Radiotherapy	Alternative method when surgery is contraindicated or refused or as a supplemental therapy after non-radical excision of BCC
Imiquimod 5%	Modifier of immunological response In case of sBCC Regimen: once a day in the evening for 8 hours, 5 times per week for 6 weeks
5-fluorouracil	Cytotoxic agent In case of sBCC Regimen: twice a day for 3–6 weeks
Photodynamic therapy (PDT)	In case of sBCC or low risk nBCC after a prior curreting Application of photosensitizer on the lesion for 3 hours prior to illumination with visible light. It results in production of reactive oxygen species that trigger apoptosis of tumor cells Two sessions in 1 week interval
Vismodegib	Hedgehog pathway inhibitor Regimen: 150 mg daily orally In case of locally advanced BCC and metastatic BCC, when other treatment methods are failed or contraindicated, in patients with Gorlin-Goltz syndrome
Cemiplimab	Recombinant IgG4 human monoclonal anti-PD-1 antibody that binds to the PD-1 receptor and unable its connection with PD-L1 and PD-L2, which lead to enhance-ment of anti-tumor response of lymphocyte T As a second line treatment in patients with locally advanced BCC and metastatic BCC, who progress or have contraindications to Hedgehog inhibitors Regimen: 350 mg i.v. every 3 weeks

Legend:

\*sBCC — superficial BCC, nBCC — nodular BCC

cell apoptosis pathway (Fig. 5). Imiquimod reduces the expression of anti-apoptotic proteins and induces caspase activation contributing to cell death. In addition, this drug enhances the production of anti-angiogenic factors [20, 21].

Table 2 presents summary of cases of patients aged 85 years old or more with BCC treated with imiquimod [22–29]. Imiquimod is considered a safe medication. The most common reported side effects include inflammation, erythema, erosion, ulceration, pain sensation restricted to the application area [30].



**Fig. 5.** Mechanisms of action of imiquimod. On the left side: through TLR-7 receptors; on the right side: induction of apoptosis by increasing the expression of CD95 receptors (so-called “death receptors”) on the cancer cell. More detailed information in the body of the text.

\*BCC — basal cell carcinoma cell; CD95L — CD95 ligand, CD95 — receptor for CD95L.

Williams and colleagues compared effectiveness of 5% imiquimod and surgical excision [31]. 501 patients with superficial or nodular BCCs were recruited to the trial (384 patients completed follow up). The participants were instructed to apply 5% imiquimod cream on the superficial BCC (sBCC) and nodular BCC (nBCC) once daily for 6 and 12 weeks, respectively. Results of 5-year follow up confirmed higher effectiveness of surgical procedure (97.7%; 173/177) when compared to imiquimod but it should be highlighted that treatment with imiquimod was successful in 82% of patients (170/206) [31]. Systematic review published in 2020 reported effectiveness of treatment with imiquimod in nBCC cases at the level of 70%, while recurrence rate was 1.8% in 13-months follow up [32]. Researchers stated that despite lower effectiveness of imiquimod in comparison to surgery this method should be considered when surgery could not be performed (due to surgery refusal or other contraindications) [18]. Roseboom *et al.* discussed effectiveness of non-surgical methods of treatment sBCC including imiquimod, 5-fluorouracyl (5-FU) and photodynamic therapy (PDT). Six hundred participants were enrolled to the trial and the observation period was ca 3 years. Results suggested superiority of imiquimod over 5-FU and PDT, while benefits from 5-FU and PDT seemed to be equal [33].

According to literature, predictors of sBCC response to imiquimod include depth of infiltration and presence of erosions/ulceration [34, 35]. In cases of sBCC with depth of infiltration less than 0.4 mm no recurrence was observed in any case during an average 34-month follow-up [34]. It is worth noting that the literature data on predictive factors of treatment response are not consistent, so this topic requires further studies on large groups of patients [36].

Table 2. Case reports of patients aged &gt;85 years old with BCC treated with imiquimod.

Year	Author	Age/ gender	Location	Type of BCC	Treatment regimen	Outcome	Contraindications to surgery
2022	Cantissani <i>et al.</i> [22]	90/n/d	chest	s	Once a day, 5 times per week for 8 weeks	No recurrence after 6 months	Age, size of tumor, comorbidities
		96/F	corpus	s	Once a day, 5 times per week for 8 weeks	No recurrence after 6 months	Age, size of tumor, comorbidities
2020	Sun <i>et al.</i> [23]	85/M	chest	n/d	Once a day for 6 months	Ineffective treatment. After 6 months residual BCC was observed	Age, comorbidities
2019	Pasadyń <i>et al.</i> [24]	88/M	chest and forehead	s	Once a day	Treatment was discontinued due to side effects: myalgias, problem with breathing, wheezing, cough, chills, and generalized weakness	No data
2016	Costales-Alvarez <i>et al.</i> [25]	95/F	left eye	n/d	Once a day, 5 times per week for 6 weeks	No recurrence after 3 months and 6 months	Bedridden, low compliance, Alzheimer's disease
2007	Leppala <i>et al.</i> [26]	87/M	nose	n	Once a day, 5 times per week for 6 weeks	No recurrence after 6, 12, 26 weeks	Difficult location
		85/M	eyelid	n	Once a day, 5 times per week for 6 weeks	No recurrence after 6, 12, 26 weeks	Difficult location
2007	Harting <i>et al.</i> [27]	88/F	scalp	n	Once a day for 3 months	Ineffective treatment. After 4 months of treatment skin biopsy revealed presence of neoplastic cells	No data. Lesion was excised due to non-surgical treatment failure
2006	Ohson <i>et al.</i> [28]	85/M	left temporal area	n	Once a day, 5 times per week for 12 weeks	Ineffective treatment. After 6 weeks of treatment skin biopsy revealed presence of neoplastic cells	Medical and physical problems, severe disability, vegetative state, perioperative difficulties
		92/F	nose	n	Once a day, 5 times per week for 12 weeks	Ineffective treatment. After 6 weeks of treatment skin biopsy revealed presence of neoplastic cells	Medical and physical problems, severe disability, vegetative state, perioperative difficulties
2002	Cowen <i>et al.</i> [29]	85/M	left ear	n	3 times per week for 12 weeks	No recurrence after 6 weeks	No data
		87/F	back	s	3 times per week for 12 weeks	No recurrence after 10 months	No data

Legend: \*s — superficial BCC, n — nodular BCC, n/d — no data



Number of papers highlight the beneficial effect of combining different therapies of BCC, such as the use of imiquimod as neoadjuvant therapy before surgical excision, imiquimod with photodynamic therapy or immunocryotherapy involving the use of cryotherapy simultaneously with imiquimod treatment [37–41].

Recent literature data indicate the well-documented efficacy of BCC treatment with imiquimod. Currently, the use of imiquimod in treatment of BCC other than superficial type is considered off-label.

## Conclusions

The presented case indicates the effectiveness and good clinical outcome of the imiquimod in the treatment of advanced BCC in an elderly patient, consistently with the literature data. It is crucial to conduct long-term observation for local recurrence of the cancer after treatment. Taking care of the elderly patients requires an individualized approach from the physician. The choice of therapy should be based on international and national management guidelines and reliable literature data and take into account the patient's preferences and their general condition.

## Conflict of interest

None declared.

## References

1. Cameron M.C., Lee E., Hibler B.P., et al.: Basal cell carcinoma: Epidemiology; pathophysiology; clinical and histological subtypes; and disease associations. *J Am Acad Dermatol.* 2019 Feb; 80 (2): 303–317. doi: 10.1016/j.jaad.2018.03.060. Epub 2018 May 18. Erratum in: *J Am Acad Dermatol.* 2021 Aug; 85 (2): 535. PMID: 29782900.
2. Krajowy Rejestr Nowotworów. <https://onkologia.org/pl/>.
3. <https://stat.gov.pl/obszary-tematyczne/ludnosc/ludnosc/sytuacja-demograficzna-polski-do-roku-2022,40,3.html>.
4. Lesiak A., Czuwara J., Kamińska-Winciorek G., et al.: Basal cell carcinoma. Diagnostic and therapeutic recommendations of the Polish Dermatological Society. *Dermatol Rev/Przegl Dermatol.* 2019; 106: 107–126. doi: <https://doi.org/10.5114/dr.2019.85572>.
5. Chlebicka I., Rygał A., Stefaniak A.A., Szepietowski J.C.: Basal cell carcinoma — Primary closure of moderate defect of mid forehead. *Dermatologic Therapy.* 2020; 33: e13322. <https://doi.org/10.1111/dth.13322>.
6. Mohan S.V., Chang A.L.S.: Advanced Basal Cell Carcinoma: Epidemiology and Therapeutic Innovations. *Curr Derm Rep.* 2014; 3: 40–45. <https://doi.org/10.1007/s13671-014-0069-y>.
7. Hasan A., Rabie A., Elhussiny M., et al.: Recurrent cutaneous basal cell carcinoma after surgical excision: A retrospective clinicopathological study. *Ann Med Surg (Lond).* 2022 May 26; 78: 103877. doi: 10.1016/j.amsu.2022.103877. PMID: 35734696; PMCID: PMC9207056.
8. Wehner M.R., Dalma N., Landefeld C., Pare-Anastasiadou A., Koutelidas I., Chren M.M., et al.: Natural history of lesions suspicious for basal cell carcinoma in older adults in Ikaria, Greece. *Br J Dermatol.* 2018 Sep; 179 (3): 767–768. doi: 10.1111/bjd.16730. Epub 2018 Jul 12. PMID: 29741766; PMCID: PMC6141323.
9. Gualdi G., Monari P., Calzavara-Pinton P.: When basal cell carcinomas became giant: an Italian multicenter study. *Int J Dermatol.* 2020 Mar; 59 (3): 377–382. doi: 10.1111/ijd.14728. Epub 2019 Nov 27. PMID: 31774173.

10. Karki S., Parajuli A., Bhattarai B., et al.: Neglected Fungating Giant basalcell carcinoma: A case report and literature review. *Clin Case Rep.* 2024; 12: e8765. doi: 10.1002/ccr3.8765.
11. Morgan F.C., Ruiz E.S., Karia P.S., Besaw R.J., Neel V.A., Schmults C.D.: Factors predictive of recurrence, metastasis, and death from primary basal cell carcinoma 2 cm or larger in diameter. *J Am Acad Dermatol.* 2020 Sep; 83 (3): 832–838. doi: 10.1016/j.jaad.2019.09.075. Epub 2019 Oct 7. PMID: 31600531.
12. Peris K., Fargnoli M.C., Kaufmann R., et al.: European consensus-based interdisciplinary guideline for diagnosis and treatment of basal cell carcinoma-update 2023. *Eur J Cancer.* 2023 Oct; 192: 113254. doi: 10.1016/j.ejca.2023.113254. Epub 2023 Jul 28. PMID: 37604067.
13. Kaçar S.D., Özüğuz P., Erkan F., Karaca Ş.: Treatment of various types of basal cell carcinoma with topical 5% imiquimod in the elderly who refused surgical intervention: a case series. *J Dermatolog Treat.* 2015 Apr; 26 (2): 165–167. doi: 10.3109/09546634.2014.915003. Epub 2014 May 7. PMID: 24731081.
14. Ceovic R., Petkovic M., Mocos Z.B., Kostovic K.: Nonsurgical treatment of non-melanoma skin cancer in the mature patient. *Clin Dermatol.* 2017; 36 (2): 177–187. doi: 10.1016/j.clindermatol.2017.10.009.
15. Lee E.H., Brewer J.D., MacFarlane D.F.: Optimizing Informed Decision Making for Basal Cell Carcinoma in Patients 85 Years or Older. *JAMA Dermatol.* 2015 Aug; 151 (8): 817–818. doi: 10.1001/jamadermatol.2015.1454. PMID: 26018032.
16. Linos E., Berger T., Chren M.M.: Point: Care of potential low-risk basal cell carcinomas (BCCs) at the end of life: The key role of the dermatologist. *J Am Acad Dermatol.* 2015 Jul; 73 (1): 158–161. doi: 10.1016/j.jaad.2015.02.005. PMID: 26089051; PMCID: PMC5886009.
17. Aoki K.C., Glick B.P., Bartos S.: Complex Management of Basal Cell Carcinoma in a Frail Patient. *Cureus.* 2024 Feb 3; 16 (2): e53518. doi: 10.7759/cureus.53518. PMID: 38440025; PMCID: PMC10911882.
18. Linos E., Parvataneni R., Stuart S.E., Boscardin W.J., Landefeld C.S., Chren M.M.: Treatment of nonfatal conditions at the end of life: nonmelanoma skin cancer. *JAMA Intern Med.* 2013 Jun 10; 173 (11): 1006–1012. doi: 10.1001/jamainternmed.2013.639. PMID: 23699934; PMCID: PMC3726204.
19. Martin I., Schaarschmidt M.L., Glocker A., Herr R., Schmieder A., Goerdts S., Peitsch W.K.: Patient Preferences for Treatment of Basal Cell Carcinoma: Importance of Cure and Cosmetic Outcome. *Acta Derm Venereol.* 2016 Mar; 96 (3): 355–360. doi: 10.2340/00015555-2273. PMID: 26537095.
20. Garcia-Mouronte E., Berna-Rico E., de Nicolas-Ruanes B., Azcarraga-Llobet C., Alonso-Martinez de Salinas L., Bea-Ardebol S.: Imiquimod as Local Immunotherapy in the Management of Premalignant Cutaneous Conditions and Skin Cancer. *Int J Mol Sci.* 2023 Jun 29; 24 (13): 10835. doi: 10.3390/ijms241310835. PMID: 37446011; PMCID: PMC10341632.
21. Chang S.H., Lin P.Y., Wu T.K., et al.: Imiquimod-induced ROS production causes lysosomal membrane permeabilization and activates caspase-8-mediated apoptosis in skin cancer cells. *J Dermatol Sci.* 2022 Sep; 107 (3): 142–150. doi: 10.1016/j.jdermsci.2022.08.006. Epub 2022 Aug 28. PMID: 36075780.
22. Cantisani C., Rossi R., Nisticò S.P., et al.: Management of patients with giant basal cell carcinoma during SARS COV2 outbreak in Italy. *Transl Biophotonics.* 2022 Aug; 4 (3): e202200009. doi: 10.1002/tbio.202200009. Epub 2022 Jul 26. PMID: 35942364; PMCID: PMC9350373.
23. Sun Y., Su Y.C., Ke C.K., Cheng S.T.: Successful treatment of topical imiquimod-resistant basal cell carcinoma by electronic X-ray brachytherapy. *Dermatol Ther.* 2020 Jul; 33 (4): e13609. doi: 10.1111/dth.13609. Epub 2020 Jun 17. PMID: 32418264.
24. Pasadyn S.R., Cain R.: Topical Imiquimod Induces Severe Weakness and Myalgias After Three Applications: A Case Report. *J Clin Aesthet Dermatol.* 2019 Jun; 12 (6): 58–59. Epub 2019 Jun 1. PMID: 31360290; PMCID: PMC6624009.
25. Costales-Álvarez C., Álvarez-Coronado M., Rozas-Reyes P., González-Rodríguez C.M., Fernández-Vega L.: Topical imiquimod 5% as an alternative therapy in periocular basal cell carcinoma in two patients with surgical contraindication. *Arch Soc Esp Oftalmol.* 2017 Feb; 92 (2): 93–96. English, Spanish. doi: 10.1016/j.oftal.2016.07.002. Epub 2016 Sep 3. PMID: 27601079.

26. Leppälä J, Kaarniranta K, Uusitalo H, Kontkanen M.: Imiquimod in the treatment of eyelid basal cell carcinoma. *Acta Ophthalmol Scand*. 2007 Aug; 85 (5): 566–568. doi: 10.1111/j.1600-0420.2007.00896.x. Epub 2007 Mar 22. PMID: 17376190.
27. Harting M., Vujevich J, Goldberg L.H.: Residual basal cell carcinoma after treatment with imiquimod: a caution on assuming complete cure. *Dermatol Surg*. 2007 Dec; 33 (12): 1516–1519. doi: 10.1111/j.1524-4725.2007.33328.x. PMID: 18076623.
28. Ohson K., DesGroseilliers J.P., Weatherhead S., Weatherhead L.: Imiquimod 5% cream use for the treatment of basal cell carcinomas in elderly patients, in long-term care facilities, not amenable to surgical or radiation therapy. *J Cutan Med Surg*. 2006 Jul–Aug; 10 (4): 201–203. doi: 10.2310/7750.2006.00033. PMID: 17234120.
29. Cowen E., Mercurio M.G., Gaspari A.A.: An open case series of patients with basal cell carcinoma treated with topical 5% imiquimod cream. *J Am Acad Dermatol*. 2002 Oct; 47 (4 Suppl): S240–248. doi: 10.1067/mjd.2002.126583. PMID: 12271286.
30. Zhang X, Xie Y, Wang L.: Rare Cutaneous Side Effects of Imiquimod: A Review on Its Mechanisms, Diagnosis, and Management. *Dermatol Ther (Heidelb)*. 2023 Sep; 13 (9): 1909–1934. doi: 10.1007/s13555-023-00978-0. Epub 2023 Aug 1. PMID: 37528289; PMCID: PMC10442311.
31. Williams H.C., Bath-Hextall F, Ozolins M., Armstrong S.J., Colver G.B., Perkins W., Miller P.S.J.; *Surgery Versus Imiquimod for Nodular and Superficial Basal Cell Carcinoma (SINS) Study Group*: Surgery Versus 5% Imiquimod for Nodular and Superficial Basal Cell Carcinoma: 5-Year Results of the SINS Randomized Controlled Trial. *J Invest Dermatol*. 2017 Mar; 137 (3): 614–619. doi: 10.1016/j.jid.2016.10.019. Epub 2016 Dec 5. PMID: 27932240.
32. Huang C.M., Kirchhof M.G.: Topical Imiquimod as a Treatment Option for Nodular Basal Cell Carcinoma: A Systematic Review. *Journal of Cutaneous Medicine and Surgery*. 2020; 24 (5): 495–503. doi: 10.1177/1203475420931770.
33. Roozeboom M.H., Arits A.H.M.M., Mosterd K., et al.: Three year follow-up results of photodynamic therapy versus imiquimod versus fluorouracil for treatment of superficial basal cell carcinoma: a single blind, non-inferiority, randomized controlled trial. *J Invest Dermatol*. 2016; 136 (8): 1568–1574. doi: 10.1016/j.jid.2016.03.043.
34. McKay K.M., Sambrano B.L., Fox P.S., Bassett R.L., Chon S, Prieto V.G.: Thickness of superficial basal cell carcinoma (sBCC) predicts imiquimod efficacy: a proposal for a thickness-based definition of sBCC. *Br J Dermatol*. 2013 Sep; 169 (3): 549–554. doi: 10.1111/bjd.12402. PMID: 23627639.
35. Urech M., Kyrgidis A., Argenziano G., et al.: Dermoscopic Ulceration is a Predictor of Basal Cell Carcinoma Response to Imiquimod: A Retrospective Study. *Acta Derm Venereol*. 2017 Jan 4; 97 (1): 117–119. doi: 10.2340/00015555-2464. PMID: 27230691.
36. Verkouteren B.J.A., Oostewechel L.C.F., Nelemans P.J., et al.: Prognostic factors for treatment failure of imiquimod treatment in basal cell carcinoma — an observational study. *J Eur Acad Dermatol Venereol*. 2022 Jun; 36 (6): e475–e477. doi: 10.1111/jdv.17962. Epub 2022 Feb 8. PMID: 35073428.
37. Kamath P, Darwin E., Arora H., Nouri K.: A Review on Imiquimod Therapy and Discussion on Optimal Management of Basal Cell Carcinomas. *Clin Drug Investig*. 2018 Oct; 38 (10): 883–899. doi: 10.1007/s40261-018-0681-x. PMID: 30128748.
38. van der Geer S, Martens J, van Roij J, Brand E, Ostertag J.U., Verhaegh M.E., et al.: Imiquimod 5% cream as pretreatment of Mohs micrographic surgery for nodular basal cell carcinoma in the face: a prospective randomized controlled study. *Br J Dermatol*. 2012; 167 (1): 110–115. doi: 10.1111/j.1365-2133.2012.10924.x. PMID: 22385074.
39. Requena C., Messegue F, Llombart B., Serra-Guillén C., Guillén C.: Facial extensive recurrent basal cell carcinoma: successful treatment with photodynamic therapy and imiquimod 5% cream. *Int J Dermatol*. 2012 Apr; 51 (4): 451–454. doi: 10.1111/j.1365-4632.2011.05293.x. PMID: 22435437.

40. *Gaitanis G., Bassukas I.D.*: Immunocryosurgery for non-superficial basal cell carcinoma: a pro-spective, open-label phase III study for tumours  $\leq 2$  cm in diameter. *Acta Derm Venereol.* 2014 Jan; 94 (1): 38–44. doi: 10.2340/00015555-1609. PMID: 23722308.
41. *Sutedja E.K., Elgianda G.S., Sutedja E., Ruchiatan K.*: Superficial Basal Cell Carcinoma on the Back Region Treated with a Combination of Cryotherapy and 5% Imiquimod Cream: A Case Report. *Int Med Case Rep J.* 2023 Jun 26; 16: 391–396. doi: 10.2147/IMCRJ.S409840. PMID: 37398930; PMCID: PMC10312345.