

DOI 10.2478/v10181-011-0102-z

Short communication

A clinical evaluation of glass-fibre posts and restorative materials used for the reconstruction of fractured canines after one-step root canal treatment in cats

**M. Bladowski^{1,3}, S. Lew², A. Kotowicz-Gears³, J. Wojtkiewicz¹,
E. Mikulska-Skupień²**

¹ Department of Human Physiology, Faculty of Medical Sciences, University of Warmia and Mazury, Warszawska 30, 10-082 Olsztyn, Poland

² Department of Internal Diseases, Faculty of Veterinary Medicine, University of Warmia and Mazury, Oczapowskiego 14, 10-719 Olsztyn, Poland

³ Dental Research Center, Szarych Szeregów 5, 10-072 Olsztyn, Poland

Abstract

This article describes a procedure for a one-step root canal treatment and the subsequent restoration of fractured canine teeth in cats. Standard glass fibre posts were used in the reconstruction of the teeth which were then divided into two groups and restored anatomically using two different composite materials. The procedures were successfully performed on six cats. The subject teeth were four upper and two lower canines.

Key words: cat, tooth fracture, root canal treatment, canine restoration, glass fibre posts

Introduction

Tooth reconstruction using glass fibre posts is a relative novelty compared to traditional restorations using cast metal posts together with porcelain crowns, and, according to our own clinical experience, are a better alternative to brass posts accompanied by composite restorations. In cats, teeth which often need dental help are the canines, which are subject to fractures due to their anatomy and function (Bellows 2004, Tutt 2006). Fracture of hard tissue is often ac-

companied by pulp exposure which necessitate root canal treatment (RCT). In the case of the six cats treated in our clinic in all cases pulp exposure was present. As it is necessary to carry out dental procedures in small animals under general anesthesia, it is advisable for operators of veterinary dentistry to perform both RCT and restoration in one session to avoid putting the animal through general anesthesia several times (Bladowski et al. 2011). A properly performed RCT and restoration is a perfect alternative to tooth extraction.

Materials and Methods

Over a period of two years six cats were treated for tooth fractures: one caused by biting hard objects such as bones, a second through games and four cases with unknown causes. All cats had only one fractured canine and all the teeth had pulp exposures (Fig. 1). The cats were of different races and sexes and aged between 1½ and 5 years of age. It was decided that each procedure would take place in one session, in which the RCT and the permanent obturation of the canal as well as the restoration would be performed. The restoration would be based on glass fibre posts. As for the final stage of the procedures, the cats were divided into two groups of three. For one group a light-cured flow composite material was chosen to be used for both setting the post in the canal and for the actual restoration of the tooth. For the other group a dual cured composite cement was used for both procedures. After the treatment all cats were observed for 6 to 24 months to establish if there were any differences in performance between the two different restoration materials.

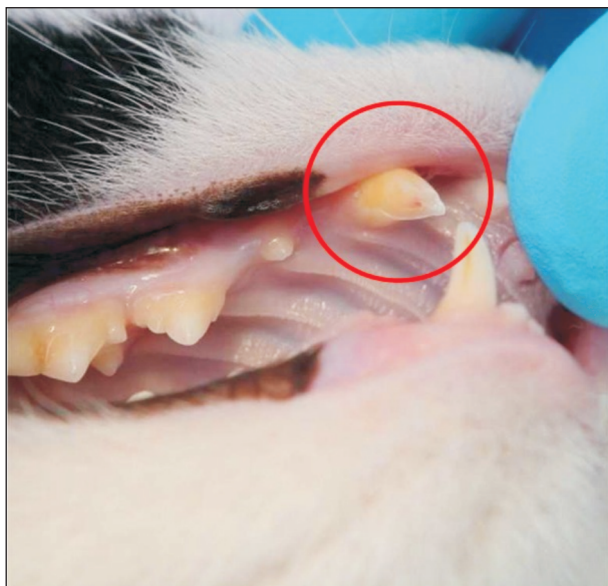

Fig. 1. Example of fractured upper right canine with pulp exposure.

Clinical Procedures

All the cats were examined and subsequently treated within 8 hours up to 6 days after the fracture. The dental procedures were performed under general anesthesia. RCT was performed following all the rules

applicable to teeth with infected pulp in small animals (Holmstrom et al. 2004, Tutt 2006, Bladowski et al. 2011). As for the root filling, the method of side condensation of cold Gutta-Percha points was used (Fig. 2) as our own clinical experience and the research of Stein et al. has shown this to be the quickest method. Endomethasone N was used as a sealant. Glass fibre posts (Glassix; Nordin). Only the smallest size of post (No. 1) is usable in cats. The canals were prepared with drills dedicated to the glass fibre posts (Fig. 3). Bonds were then applied to the prepared canals as well as onto the posts, and a small amount of fixing material was then applied to the canal. Two kinds of materials were used for fixing the posts: in three cases a flow composite (Revolution; Kerr) and in the remaining three cases dual curing composite cement (Oliflow Core; Olident). Finally, the posts were placed in the canals (Fig. 4) and all the work was light-cured. To reinforce the strength of the restoration the crowns of the fractured teeth were rebuilt using the same materials as were used to fix the posts in the root canals. The teeth were restored to their actual sizes and shapes, only slightly excluded from the occlusion (Fig. 5). The esthetics of the teeth were very satisfactory which is important especially in show cats, and would be difficult to achieve with the use of brass points, as shown in other small animals (Bladowski et al. 2011), or even with porcelain crowns. After each procedure the owner was informed that they should come for check-ups every 6 months, or more often should any disturbing symptoms occur (Tutt 2006).

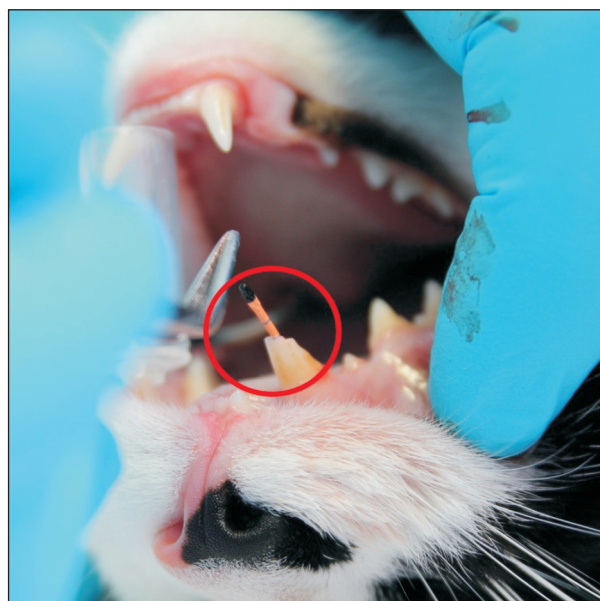


Fig. 2. Initial stage of side condensation of cold Gutta-Percha points.

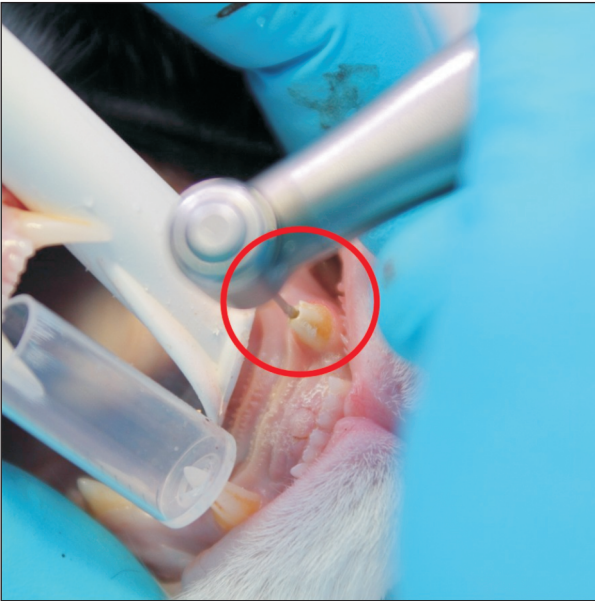


Fig. 3. Drilling of canal before setting glass fibre post.

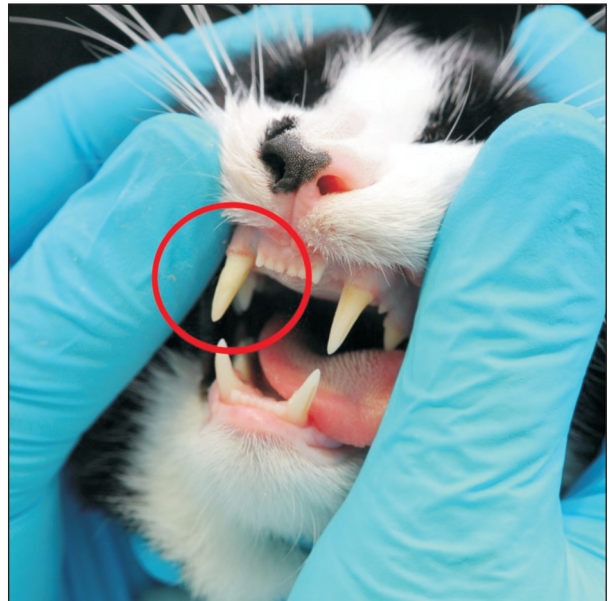

Fig. 5. Tooth restoration with use of composite cement (perfect esthetics).

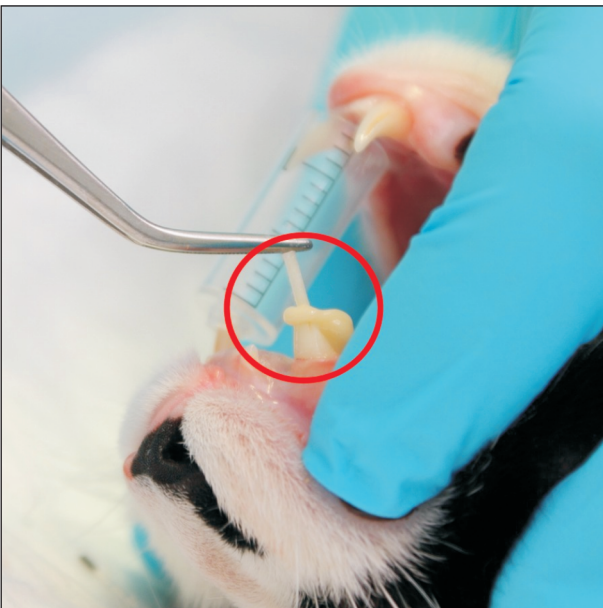

Fig. 4. Post placed in root canal.

Results and Discussion

A standard composite material could not be used for fixing the glass fibre post in the canal as it is too thick, hence the use of the flow composite. However, in two cases out of three where the flow composite had been used, cracking of the composite material was observed even though the teeth had been slightly excluded from the occlusion (Fig. 6). A similar phenomenon can be observed in human teeth (Giovani

et al. 2009). No such damage has yet been observed in the teeth where dual curing cement was used. Therefore it is advisable to use dual curing composite cement as a restorative material. Extractions, especially of canines, should be avoided in modern veterinary practice as they cause functional handicap which can be easily avoided thanks to up-to-date dental techniques. Such techniques give ultimate satisfaction both to the operators and to the animal owners.

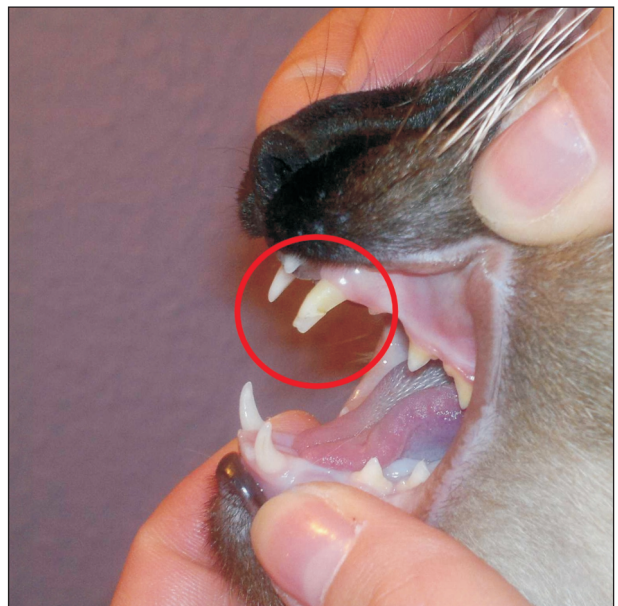


Fig. 6. Cracked flow composite restoration after three months (visible slight translucency).

References

- Bellows J (2004) Small animal dental equipment, materials and techniques. A primer. 1st. ed., Blackwell Publishing, Oxford, pp 188-191, 201-207.
- Tutt C (2006) Small animal dentistry. A manual of techniques. Blackwell Publishing, Oxford, pp 214-219.
- Bladowski M, Kotowicz-Gears A, Wojtkiewicz J (2011) Restoration of fractured canines in ferrets after one-step root canal treatment. *Pol J Vet Sci* 14: 137-139.
- Holmstrom S, Frost P, Eisner E (2004) Veterinary dental techniques: For the small animal practitioner. 3rd ed., Philadelphia, Saunders, pp 117-128.
- Stein K E, Marettta S M, Siegel A, Vitoux J (2004) Comparison of hand-instrumented, heated gutta-percha and engine-driven, cold gutta-percha endodontic techniques. *J Vet Dent* 21: 136-145.
- Giovani A R, Vansan L, de Sousa Neto M, Paulino SM (2009) In vitro fracture resistance of glass-fiber and cast metal posts with different lengths. *J Prosthet Dent* 101: 183-188.