

DOI 10.2478/pjvs-2014-0083

Review

Endometriosis – significance for horse reproduction, pathogenesis, diagnosis, and proposed therapeutic methods

J. Buczkowska¹, R. Kozdrowski¹, M. Nowak², A. Raś³, J. Mrowiec¹

¹ Department of Reproduction and Clinic for Farm Animals, Faculty of Veterinary Medicine, University of Life and Environmental Science, Plac Grunwaldzki 49, 50-366 Wrocław, Poland

² Department of Pathology, Faculty of Veterinary Medicine, University of Life and Environmental Science, C.K. Norwida 31, 50-375 Wrocław, Poland

³ Department of Animal Reproduction, Faculty of Veterinary Medicine, University of Warmia and Mazury, Oczapowskiego 14, 10-719 Olsztyn, Poland

Abstract

Equine endometriosis is a multifactorial disease considered to be a one of the most important causes of equine infertility, especially in older mares. This article reviews the current knowledge of equine endometriosis: pathogenesis, diagnosis, and optional treatment. Also describes the histomorphological and immunohistochemical characterization of endometriosis as well as potential etiological factors which may influence disease progression. Unfortunately, the etiology and pathogenesis of endometriosis still remains unclear, and consequently no effective treatment has been proposed so far. Therefore future studies are needed for explanation of this disease.

Key words: mare, endometrium, biopsy, endometriosis

Introduction

According to the scheme proposed by Troedsson (1999), endometritis in mares is divided into: 1) sexually transmitted diseases, 2) chronic infectious endometritis, 3) persistent breeding-induced endometritis and 4) chronic degenerative endometritis (endometriosis). This paper will be devoted to the last of the above-mentioned diseases, to which more attention has been drawn recently, shedding new light on its pathogenesis. Proposed therapeutic methods will be also discussed in this paper.

There are two terms: endometriosis and endometriosis used in the medical literature, which are defined differently and should not be confused. Endometriosis means extra-uterine implantation of endometrial tissue and refers to women (Snider et al. 2011), whereas the term endometriosis was introduced by Kenney in 1992 and means changes in the mare's uterus previously referred to as chronic degenerative endometritis (Allen 1993). At present, endometriosis is defined as active or inactive periglandular and/or stromal endometrial fibrosis including glandular alterations within fibrotic foci (Hoffmann et al. 2009b). This pro-

Table 1. Types of endometriosis and histopathological view of endometrium (Lehmann et al. 2011).

Types of endometriosis		Histopathological changes in the endometrium
Nondestructive	active	glands with several disordered fibrotic stromal cells showing a metabolically active differentiation with medium to large, ovoid hypochromatous nuclei and a pale cytoplasm
	inactive	glandular nest with periglandular stromal cells showing a metabolically inactive differentiation, characterized by spindle shaped, hyperchromatous nuclei and an elongated cytoplasm
	mixed	glands with periglandular stromal cells showing both 50% metabolically active and 50% inactive differentiation
Destructive	active	glands surrounded by metabolically active stromal cells, in addition to the disordered appearance of different layers, the fibrotic stromal cells are invasive and they penetrate the lumen of the gland; different degenerated epithelial cells are visible
	inactive	glands with metabolically inactive fibrotic stromal cells which lie parallelly arranged to the axis of the adjacent gland, multifocal destruction of single epithelial cells and congestion of the uterine secretions in the lumina are visible
	mixed	glands surrounded by active and inactive periglandular stromal cells which penetrate the glandular epithelia

cess may affect single glands and/or glandular nests (Kenney 1978). The degree of endometriosis in mares increases with age; however, it is thought that this is not connected with the number of foalings (Ricketts and Alonso 1991, Kenney 1993, Hoffmann et al. 2009b, Aresu et al. 2012). Endometriosis is one of the causes of infertility in mares. Structural changes in the endometrium include the occurrence of progressive focal proliferation of the uterine glands, which are concentrated in the glandular nests encircled by more and more numerous layers of fibrous tissue as the process progresses. Inside the nests, glandular cysts occur, whereas the number of normal endometrial glands decreases. Stromal fibrosis is a dominating disease process, which results in disturbance of lymph circulation, as a result of which lymphatic extension occurs (Katkiewicz et al. 2007).

Based on the morphology of the periglandular stromal cells, the fibrosis can be divided into different types, which can be classified as either destructive or non-destructive, with biopsies displaying more than 75% of the fibrotic foci of one of these groups being termed "active" or "inactive" fibrosis respectively. Biopsy with approximately equal ratios of active and inactive periglandular stromal cells are termed "mixed" endometriosis (Table 1) (Lehmann et al. 2011). In all of the above-mentioned types, single uterine glands and/or glandular nests may be affected by the process (Hoffmann et al. 2009b). Additionally, we can determine the degree of endometriosis describing it from mild to severe (Kenney and Doig 1986, Hoffmann et al. 2009b). In severe endometriosis a significantly higher incidence of glandular nest development was observed. Furthermore, a significant association of inactive endometriosis and cystic dilatation of the

affected glands could be seen. However, within active non-destructive endometriosis, an asynchronous cycle, in particular irregular differentiation of the affected glandular epithelia, was most pronounced (Hoffmann et al. 2009b).

Pathogenesis

Atypical morphological and functional differentiation of periglandular endometrial stromal cells are the first sign of endometriosis. The first stage of fibrosis is characterised by large, polygonal periglandular stromal cells which synthesize collagen fibres, whereas in advanced fibrosis metabolic active or inactive stromal cells, without signs of collagen synthesis, as well as myofibroblasts, predominate (Walter et al. 2001, Hoffmann et al. 2009a,b). Periglandular fibrosis in endometrial tissue is not characterized by an increased incidence of collagen fibres, but by periglandularly arranged fibroblasts in one or more layers, which produce the extracellular matrix proteins collagen IV, laminin, and fibronectin. In addition, these fibroblasts express h-smooth muscle actin, tropomyosin and occasionally desmin, which confirms their differentiation into myofibroblasts. It remains to be elucidated whether the above-mentioned differentiation has further consequences on the uterine gland epithelium or the stromal cells, as has been shown for various pathological processes (Walter et al. 2001).

During the fibrosis process, the stromal cells of the basal lamina are capable of collecting collagen under the influence of different stimulating factors. The collection of collagen occurs most often around the glands or in connection with the basement membrane

of the luminal epithelium (Kenney and Doig 1986). Fibrosis occurs most often without the presence of inflammatory cells (Kenney 1978). The first evidence of impending deposition of collagen is the loss of randomization of stromal cells (and their nuclei) in the stratum compactum and stratum spongiosum, particularly visible around the glands. The advancement of fibrosis may be evaluated by the degree (the number of periglandular layers) and frequency (the number of fibrotic foci per linear field) (Kenney and Doig 1986). From one to three layers of periglandular fibrosis is considered to be a slight reaction, from four to ten – a moderate reaction, and more than ten layers indicate a severe degree of fibrosis (Kenney 1978).

Potential etiological factors which may affect development of the disease are morphological and immunohistochemical changes of the endometrium, which occur in endometriosis (Table 1) (Hoffmann et al. 2009b, Lehmann et al. 2011). In the unaffected endometrium, cyclical and seasonal endocrine changes result in cycle-synchronous morphological alterations to epithelial and stromal cells. With regard to the morphology of the periglandular stromal cells within the fibrotic foci of the endometriosis an active and inactive differentiation can be distinguished (Hoffmann et al. 2009b, Lehmann et al. 2011). However, in contrast to the unaltered stromal cells, neither seasonal nor cyclic endocrine changes seem to have a significant influence on the activity of the fibrotic stromal cells (Hoffmann et al. 2009b). Hoffmann et al. (2009b) showed that, in the biopsy material collected during the breeding/non-breeding season or on defined days during the oestrous cycle, both seasonal and cycle-associated endocrinological changes do not determine the activity of stromal cells.

In explaining the connection between endometritis and endometriosis, both the impact of the endometritis on further development of degenerative changes in the endometrium and the process of activation of inactive fibrotic foci were taken into account, and predispositions for the occurrence of endometritis in a mare with endometriosis were examined (Lee et al. 2001, Atamas 2002, Keller et al. 2006, Hoffmann et al. 2009b). A higher frequency of endometritis in a mare with a destructive type of endometriosis was described (Hoffmann et al. 2009b), which indicates an important role of uterine glands in the physiological clearance of the endometrium, and disturbance of this function may cause endometritis (Hoffmann et al. 2009b). It was also shown that mares with a higher biopsy grade more frequently retain fluid in the uterus after insemination (Woodward et al. 2012). It is suggested that temporary activation of fibrotic stromal cells, which could be observed as a result of experimentally induced bacterial endometritis, is presumably caused by

profibrotic growth factors and cytokines released from inflammatory cells (Lee et al. 2001, Atamas 2002, Hoffmann et al. 2009b). However, it was shown that inflammation is poorly correlated with grade of endometriosis, and bacterial infection does not increase intensification of this disease (Keller et al. 2006, Aresu et al. 2012). Additionally, in mares experimentally infected with *Streptococcus equi* subsp. *Zooepidemicus*, the degree of endometriosis did not change during the 2-year period of the observation (Hoffmann et al. 2009b). Recently it was shown that intrauterine enrofloxacin infusion in mares induced severe acute uterine mucosal necrosis, inflammation, and a significant increase in endometrial fibrosis (Rodriguez et al. 2012).

Among other changes in the mare endometrium, a negative correlation between mild endometriosis and changes in vessels of severe angiosclerosis type was also observed, yet such a correlation between endometriosis and inflammation of the perivascular sheath and surrounding tissue (perivasculitis) was not noted (Hoffmann et al. 2009b). It was observed that a large percentage of both barren and foaling mares show angiosclerosis; however, this does not have an impact on the degree of endometriosis (Lehmann et al. 2011).

An immunohistochemical study showed that stromal maldifferentiation which could be seen in all fibrotic foci is independent of the degree of endometriosis, and that the cells show a lower expression of steroid hormone receptors compared to unchanged stromal cells (Hoffmann et al. 2009b). Moreover, metabolically inactive stromal cells exhibited a decreased proliferation activity as compared to the unaltered endometrium, whereas no differences could be observed within active fibrotic foci (Hoffmann et al. 2009b). A considerable reduction of estrogen and progesterone receptor expression of fibrotic stromal cells as compared to the normal stroma is one of the hallmarks of endometriosis (Hoffmann et al. 2009b). This reduction indicates advanced changes in the stromal cells within a fibrotic focus, which lead to the loss of specialization in the cell structure and function. As a result, fibrotic stromal cells are unable to react to cyclic endocrine changes and become independent of hormonal control mechanisms in the uterus (Hoffmann et al. 2009b).

Maldifferentiation of the epithelial cells of the uterine glands within fibrotic foci was also characterized by a distinct variability in glandular steroid hormone receptor expression. In active endometriosis, an increase in expression of estrogen and progesterone receptors dominates, as compared to the unchanged glands, whereas glandular epithelia in inactive endometriosis show a decrease in expression of the

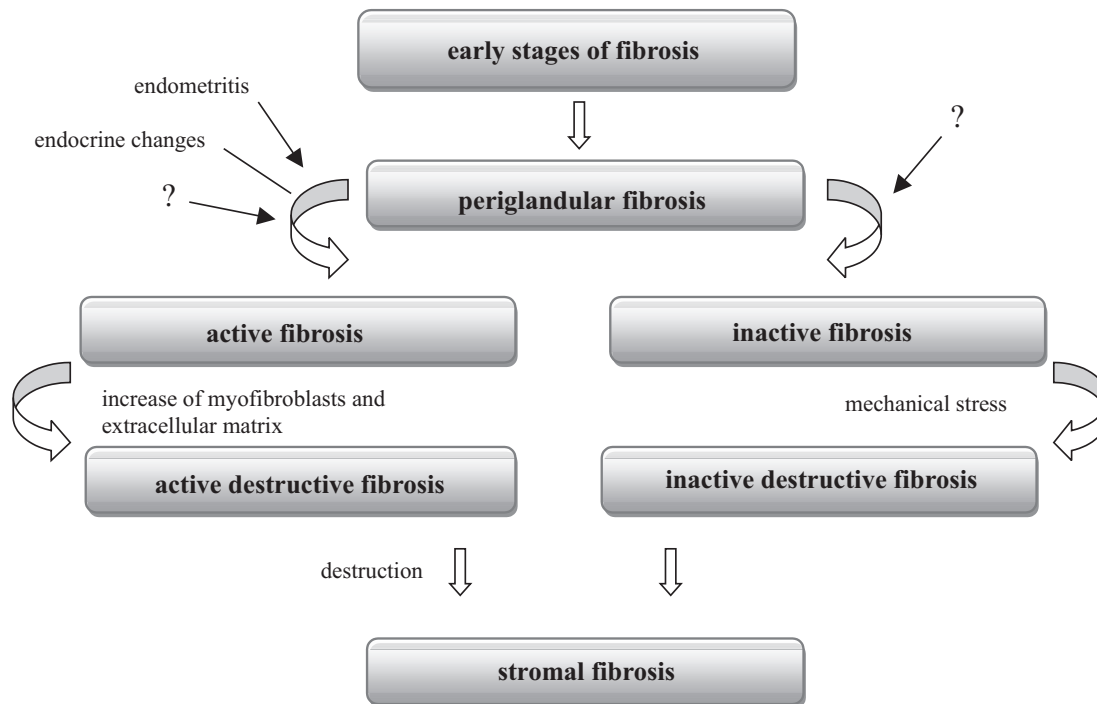


Fig. 1. Schematic picture of the possible pathogenesis of endometriosis (adopted from Hoffmann et al., 2009b).

above-mentioned receptors (Hoffmann et al. 2009b). Moreover, the concentrations of steroid receptors in the destructive type of endometriosis are also lower. A mild increase in expression of estrogen and progesterone epithelial receptors was observed in active non-destructive fibrotic foci, whereas in the other types of endometriosis, a decrease in expression of the above-mentioned receptors was visible. This phenomenon can be explained by paracrine mechanisms because the effect of the impact of steroid hormones on the glandular epithelium is physiologically mediated by the adjacent stromal cells (Cooke et al. 1997, Kurita et al. 1998, Pierro et al. 2001). These cells are maldifferentiated in endometriosis and presumably release other paracrine signals. Therefore, the asynchronous cycle differentiation of the affected glands is, initially, most likely the consequence of maldifferentiation of the stroma, and the decreased expression of steroid hormone receptors is likely to be caused by distinct degeneration of the epithelial cells. Another possible explanation of the asynchronous cycle differentiation of glandular epithelia within fibrotic foci is the severe damage of the basal lamina connected with altered expression of laminin. All of the stromal cells of fibrotic foci, in particular in active destructive fibrosis, show intracellular laminin expression (Hoffmann et al. 2009b). Only an intact basal lamina is able to ensure complex paracrine interaction between the epithelia and the underlying stroma (Lin and Bissel 1993, Arnold et al. 2001), which inhibits

direct stromal-epithelial contacts as well as an interaction between epithelial cell surface integrins and the fibrotic extracellular matrix. Furthermore, large discontinuities of the glandular basal lamina were determined predominantly in destructive endometriosis. Fibrosis activity visibly affects the expression of estrogen receptors; however, it does not have an influence on the concentration of intermediate filaments in the glandular epithelium, although in the destructive type of endometriosis the expression of filaments increases considerably compared to the non-destructive type (Hoffmann et al. 2009b).

The immunohistochemical study of stromal cells indicates that distinct variability in all types of endometriosis regards coexpression of vimentin and desmin intermediate filaments as well as h-actin in myofilaments. The stromal cells in destructive endometriosis, in particular in active destructive endometriosis, tended to express more h-actin. In addition, in the latter type of endometriosis, expression of laminins in the stromal cells is greater (Hoffmann et al. 2009b).

The immunohistochemical study of extracellular matrix in fibrotic foci indicated the presence of more expression of proteoglycans and fibronectin in the destructive type of endometriosis, in particular in severe active endometriosis, compared to other types (Hoffmann et al. 2009b). Therefore, the observed accumulation of proteoglycans and fibronectin is probably due to an increased number of secretively active myofibroblasts (Hoffmann et al. 2009b).

Summing up, partial thinning of a fragment of the basal lamina initiates changeability and activity of the glandular epithelium (Fig. 1). A few etiological factors may cause this process e.g. a periglandular localised endometritis, a local deficiency of oxygen caused by severe angiosclerosis, wound healing processes following mechanical damage, and disorders regarding physiological regeneration of the basal lamina. However, only the intact basal lamina is able to suppress activation of epithelial cells and synthesis of profibrotic growth factors (Streuli et al. 1993). Endometritis which occurs simultaneously with endometriosis causes activation of the metabolism of fibrotic stromal cells. In contrast with the above, cyclical and seasonal endocrine changes seem to have no affect on the disease process. Further studies are necessary to determine the factors which are able to maintain active fibrosis. The progressive nature of the disease is likely to be attributed to an increase in the number of myofibroblasts leading to the damage of uterine glands in the final stage of fibrosis. On the other hand, the ability of these cells to release enzymes which regulate matrix homeostasis may contribute to progressive damage of the basal lamina and may lead to the collection of extracellular matrix, which in turn causes maintenance of the fibrosis process (Ramos et al. 2001). For the development of metabolically inactive fibrosis, etiological factors are particularly interesting, although they have not yet been determined. The contractibility of myofibroblasts and their arrangement parallel to the adjacent glands improves the ability of the fibrotic tissue to contract. Mechanical stress may explain cystic expansion of the glands and focal damage of the epithelium, which occurs more often in this type of endometriosis. It is assumed that activation of inactive fibrosis may occur at any time during endometritis and, probably, via other, still unknown, factors (Hoffmann et al. 2009b).

Diagnosis

Most degenerative changes typical for endometriosis can be diagnosed only through the histological evaluation of an endometrial biopsy (Kenney 1978, Kenney and Doig 1986, Ricketts and Alonso 1991, Ricketts and Barrelet 1997, Katkiewicz et al. 2007, Zajac et al. 2008, Schlafer 2009, Snider et al. 2011, Aresu et al. 2012). Endometrial biopsy has been a standard procedure for evaluation of the health of the mare's uterus for more than 40 years. It is a safe, practical and very useful method (Kenney 1978, Ricketts and Barrelet 1997). Nevertheless, it should be noted that some researchers draw the conclusion that collection of an endometrial specimen from one uterine portion does not necessarily reflect the state of its remain-

ing areas, as significant differences were observed regarding both the size of a fibrosis area and the grade of endometriosis in a biopsy collected from the same mare yet from different portions of its uterus. In more than half of the mares variation in the endometrial grade in biopsies collected from different uterine portions was revealed (Fiala et al. 2010). Keller et al. (2006) also observed that a single biopsy does not represent the whole endometrium in the diagnostics of degenerative changes. However, according to the other researchers, a single biopsy reflects very well the condition of the whole uterus if the biopsy material has proper size and shape, and it is prepared and evaluated in the appropriate way (Kenney 1978, Kenney and Doig 1986).

The purpose of performing the biopsy is to detect changes in the endometrium and to determine the fertility potential of the mare. The biopsy should be taken from barren mares, "repeat breeder" mares, from mares showing anoestrus during the breeding season, and from mares with a pathologic content of the uterus (Kenney and Doig 1986, Schlafer 2007, Snider et al. 2011). Another group consists of mares with a history of early embryonic or foetal death, mares with poor perineal conformation before surgical correction, and recipient mares in the embryotransfer programme. Pregnancy is the only known contraindication for the performance of the biopsy (Kenney and Doig 1986, Schlafer 2007, Snider et al. 2011).

In the image of the uterine wall, seven components can be distinguished: the uterine lumen, endometrial epithelial interface, superficial stroma (stratum compactum), the glands and the glandular epithelium, the stroma – the mid and deep endometrium (stratum spongiosum), vessels (arteries, veins and lymphatics), myometrium and larger vessels. An assessment of these components helps the pathophysiology of the uterine wall to be determined. Apart from microscopic examination of the biopsy material, immunohistochemical examination can be also performed (Schlafer 2007).

Evaluation of the degree of endometrial fibrosis is essential as, in contrast to the inflammatory changes, fibrosis is of a permanent nature and, if it is intense, it becomes the main factor that reduces the reproductive performance of the mare (Kenney and Doig 1986). Depending on the degree of intensification of structural changes in the endometrium, Kenney and Doig (1986) divided endometriosis into four categories (Table 2). Inflammation, fibrosis, lymphatic system and atrophic changes may coexist, and the more changes occur and the more advanced they are, the higher the category is. For example, an occurrence of inflammatory changes or fibrosis signifies category IIA; however, if they occur simultaneously, it will signify category IIB. If the inflammatory condition is eliminated, the endometrium may return to category IIA. Moreover, if inflammatory

Table 2. Standard classification system for histologic changes in the endometrium (Kenney and Doig 1986).

Category	Structural changes in the endometrium	Percentage of altered glands
I	Healthy mares; no pathologic changes or any existing changes (such as inflammation or fibrosis) are slight and sparsely scattered	–
IIA	A small degree of stromal fibrosis around the individual gland branches; a lack of glandular nests in 4 adjacent fields; slight to moderate inflammatory changes, lymphatic lacunae occurs; partial endometrial atrophy	10-35%
IIB	Fibrotic changes are more severe and extensive than in IIA; an average of 2-4 fibrotic nests of glands, usually with 2-4 layers in 4 adjacent fields; inflammatory and lymphatic changes are widespread, diffuse and moderately severe	35-60%
III	Widespread, diffuse, severe inflammatory changes; widespread fibrosis of gland branches of 5 or more fibrotic nests; severe lymphatic lacunae	> 60%

Table 3. Expected foaling rates of mares according to categorization of endometrium (Kenney and Doig 1986).

Category	Degree of endometrial change	Expected foaling rate
I	Absent	80-90%
IIA	Mild	50-80%
IIB	Moderate	10-50%
III	Severe	10%

changes, fibrosis, and lymphatic changes coexist, the endometrium belongs to category III. The more changes occur in the endometrium, the worse the prognosis of pregnancy and maintenance of pregnancy is (Table 3) (Kenney and Doig 1986).

The lymphatic lacunae observed in the biopsy are derived from dilated lymphatic vessels and can occur in the lamina propria or core of the endometrium folds singly or in clusters and they can be focal or diffuse. When single lacunae are joined and expand, they become endometrial cysts, which achieve a size of even up to a few centimetres in diameter (Kenney 1978, Kenney and Doig 1986). Large uterine cysts may disturb embryo mobility, and consequently the process of maternal recognition of pregnancy (Kenney 1978).

Cyst-like expanded glands are often noticed within the fibrotic nests. This phenomenon can be also observed during the seasonal atrophy; however, in that case, there is a thick secretion inside. Cystic distention without fibrosis and without inspissation also occurs during the physiological breeding season. When the above-mentioned changes are intensified to a great extent, they seem to have a negative impact on reproduction (Kenney 1978, Kenney and Doig 1986).

In about 30% of cases of fibrosis, acute and/or chronic inflammation is observed (Ricketts and Barrelet 1997). Then, in the biopsy, inflammatory cells (mainly lymphocytes and neutrophils, and a lower number of eosinophils and mastocytes which are

concentrated around the glandular nests and vessels, and dispersed within the stroma) are observed (Kenney 1978, Zajac et al. 2008, Aresu et al. 2012).

Impact of endometriosis on fertility

Fertility impairment is the main problem connected with endometriosis, and therefore Lehmann et al. (2011) decided to use histopathological and immunocytochemical examination of the endometrium in order to determine reproductive abilities in fertile and barren mares. They showed abnormal secretion of the endometrial glands during endometriosis. In the barren mares, there was lower expression of proteins: uteroglobin and uterocalin were detected in the fibrosis areas, especially in those mares which suffered from moderate destructive endometriosis. Uterocalins take part in the supply of proteins to the embryo (Crossett et al. 1998) and deficiency of this protein can contribute to early embryonic death (Lehmann et al. 2011), whereas deficiency of uteroglobins may lead to inhibition of the embryo protection against a maternal immune response which results in pregnancy loss (Zhang et al. 2000). In the destructive type of endometriosis, both quantity expression and quality expression of endometrial proteins are decreased (Hoffmann 2009a). In research into the fertility of mares suffering from endometriosis, Lehmann et al. (2011) showed that mild

non-destructive endometriosis dominates in fertile mares, whereas most barren mares show a moderate degree of endometriosis. In addition, destructive changes in the fibrotic foci are observed in most barren mares. Thus, barren mares much more often suffer from moderate destructive endometriosis compared to fertile mares. It seems that whether fibrosis is active or inactive does not affect fertility. Recently, Szostek et al. (2012) showed that changes in mRNA transcription of prostaglandin synthases and prostaglandin production which occur in the equine endometrium during the course of fibrosis may lead to early embryonic death.

Treatment

It is difficult to provide satisfactory treatment for endometriosis. It is commonly thought that changes caused by this disease are irreversible (Kenney and Doig 1986). For its treatment, mechanical curettage or chemical agents (kerosene, DMSO, isotonic salt) can be applied (Keller et al. 2006).

On the proceedings of J.P. Hughes international workshop on equine endometritis different therapeutic methods were presented and summarised by Allen (1993). For example, one of the authors analyzed the effect of physical curettage applied to mares with various degrees of endometriosis, leading to hyperaemia and mild acute endometritis, combined with intrauterine administration of antibiotics to prevent infection. After treatment they noticed improvement in endometrial biopsy grade in 44% of mares, in 51% of mares there was no effect, and in 5% of mares it was worse. Additionally, there was no significant effect on the fertility rates. It was also showed that irrigating the uterus with 250-500 ml of kerosene, which causes uterine oedema lasting for 1-2 days and results in expulsion of retained excretions from the uterine glands, is able to improve fertility rates. The best results were obtained when mares were mated during the first oestrus after treatment. Other research, in which kerosene was also used, showed that the application of this therapy brings rather a short-term effect, as half of the mares which were pregnant after treatment with kerosene miscarried later (Allen 1993). On the other hand, Ley et al. (1989) studied the effect of intrauterine administration of 10-30% DMSO in sterile saline solution, compared to the control group i.e. mares treated with sterile saline solution alone. This therapy was carried out during oestrus for five consecutive days. No negative changes were found in the endometrium after any treatment protocols. It was shown that 30% DMSO solution caused a reduction of inflammation and/or a reduction of periglandular fibrosis. However, no significant difference was found in pregnancy rates be-

tween mares treated with 30% DMSO solution and mares treated with saline solution alone, although a growing tendency was observed following DMSO therapy. Furthermore, Griffin and Bennet (2002) observed an improvement of fertility following photoablation of endometrial cysts in barren mares.

Conclusion

Continuous progress and modern laboratory methods enable a more in-depth analysis of changes in the process of endometriosis, and they also make it possible to understand accurate genesis and show the impact of different factors on the development and progression of degenerative changes in the mare's uterus. However, further studies are still needed to explain the etiology of endometriosis process initiation, and the improvement of knowledge concerning etiology and pathogenesis of endometriosis will enable the development of both prevention and more effective treatment of this disease.

Conflict of interests

The authors declare that there is no conflict of interests regarding the publication of this article.

Acknowledgments

This paper was supported by NCN grant, DEC-2011/01/B/NZ5/04173.

References

- Allen WR (1993) Proceedings of the John P. Hughes international workshop on equine endometritis. *Equine Vet J* 25: 184-193.
- Aresu L, Benali S, Giannuzzi D, Mantovani R, Castagnaro M, Falomo ME (2012) The role of inflammation and matrix metalloproteinases in equine endometriosis. *J Vet Sci* 13: 171-177.
- Arnold JT, Kaufman DG, Seppala M, Lessey BA (2001) Endometrial stromal cells regulate epithelial cell growth in vitro: a new co-culture model. *Hum Reprod* 16: 836-845.
- Atamas SP (2002) Complex cytokine regulation of tissue fibrosis. *Life Sci* 72: 631-643.
- Cooke PS, Buchanan DL, Young P, Setiawan T, Brody J, Korach KS, Taylor J, Lubahn DB, Cunha GR (1997) Stromal estrogen receptors mediate mitogenic effects of estradiol on uterine epithelium. *Proc Natl Acad Sci USA* 94: 6535-6540.
- Crossett B, Suire S, Herrler A, Allen WR, Stewart F (1998) Transfer of a uterine lipocalin from the endometrium of the mare to the developing equine conceptus. *Biol Reprod* 59: 483-490.

- Fiala SM, Esmeraldino A, Jobim MIM, Garbade P, Wolf CA, Richter G, Gregory RM, Mattos RC (2010) Endometrial fibrotic changes. Is one biopsy enough to diagnose degenerative changes? *Anim Reprod Sci* 121S: 89-90.
- Griffin RL, Bennett SD (2002) Nd: YAG laser photoablation of endometrial cysts: a review of 55 cases (2000-2001). *P AAEP* 48: 58-60.
- Hoffmann C, Bazer FW, Klug J, Aupperle H, Ellenberger C, Schoon HA (2009a) Immunohistochemical and histochemical identification of proteins and carbohydrates in the equine endometrium. Expression patterns for mares suffering from endometrosis. *Theriogenology* 71: 264-274.
- Hoffmann C, Ellenberger C, Mattos RC, Aupperle H, Dhein S, Steif B, Schoon HA (2009b) The equine endometrosis: new insights into the pathogenesis. *Anim Reprod Sci* 111: 261-278.
- Katkiewicz M, Witkowski M, Zajac S (2007) Endometrial biopsy of mares: visualization of healthy and diseased structure. *Med Weter* 63: 463-466.
- Keller A, Neves AP, Aupperle H, Steiger K, Garbade P, Schoon HA, Klug E, Mattos RC (2006) Repetitive experimental bacterial infections do not affect the degree of uterine degeneration in the mare. *Anim Reprod Sci* 94: 276-279.
- Kenney RM (1978) Cyclic and pathologic changes of the mare endometrium as detected by biopsy, with a note on early embryonic death. *J Am Vet Med Assoc* 172: 241-262.
- Kenney RM, Doig PA (1986) Equine endometrial biopsy. In: Morrow D (ed) *Current therapy in theriogenology*. 2 ed., Saunders, Philadelphia, pp 723-729.
- Kurita T, Young P, Brody JR, Lydon JP, O'Malley BW, Cunha GR (1998) Stromal progesterone receptors mediate the inhibitory effects of progesterone on estrogen-induced uterine epithelial cell desoxyribonucleic acid synthesis. *Endocrinology* 139: 4708-4713.
- Lee CG, Homer RJ, Zhu Z, Lanone S, Wang X, Koteliensky V, Shipley JM, Gotwals P, Noble P, Chen Q, Senior RM, Elias JA (2001) Interleukin-13 induces tissue fibrosis by selectively stimulating and activating transforming growth factor β_1 . *J Exp Med* 194: 809-821.
- Lehmann J, Ellenberger C, Hoffmann C, Bazer FW, Klug J, Allen WR, Sieme H, Schoon HA (2011) Morpho-functional studies regarding the fertility prognosis of mares suffering from equine endometrosis. *Theriogenology* 76: 1326-1336.
- Ley WB, Bowen JM, Sponenberg DP, Lessard PN (1989) Dimethyl sulfoxide intrauterine therapy in the mare: effects upon endometrial histological features and biopsy classification. *Theriogenology* 32: 263-276.
- Lin CQ, Bissell MJ (1993) Multi-faceted regulation of cell differentiation by extracellular matrix. *FASEB J* 7: 737-743.
- Pierro E, Minici F, Alesiani O, Miceli F, Proto C, Screpanti I, Mancuso S, Lanzone A (2001) Stromal-epithelial interactions modulate estrogen responsiveness in normal human endometrium. *Biol Reprod* 64: 831-838.
- Ramos C, Montano M, Garcia-Alvarez J, Ruiz V, Uhal BD, Selman M, Pardo A (2001) Fibroblasts from idiopathic pulmonary fibrosis and normal lungs differ in growth rate, apoptosis, and tissue inhibitor of metalloproteinases expression. *Am J Respir Cell Mol Biol* 24: 591-598.
- Ricketts SW, Alonso S (1991) Assessment of the breeding prognosis of mares using paired endometrial biopsy techniques. *Equine Vet J* 23: 185-188.
- Ricketts SW, Barrelet A (1997) A retrospective review of the histopathological features seen in a series of 4241 endometrial biopsy samples collected from UK Thoroughbred mares over a 25 year period. *Pferdeheilkunde* 13: 525-530.
- Rodriguez JS, Han S, Nielsen S, Pearson LK, Gay JM, Tibary A (2012) Consequences of intrauterine enrofloxacin infusion on mare endometrium. *J Equine Vet Sci* 32: 106-111.
- Schlafer DH (2007) Equine endometrial biopsy: enhancement of clinical value by more extensive histopathology and application of new diagnostic techniques? *Theriogenology* 68: 413-422.
- Snider TA, Sepoy C, Holyoak GR (2011) Equine endometrial biopsy reviewed: observation, interpretation and application of histopathologic data. *Theriogenology* 75: 1567-1581.
- Streuli CH, Schmidhauser C, Kobrin M, Bissell MJ, Derynck R (1993) Extracellular matrix regulates expression of the TGF- β_1 gene. *J Cell Biol* 120: 253-260.
- Szostek AZ, Siemienuch MJ, Lukasik K, Galvao AM, Ferreira-Dias GM, Skarzynski DJ (2012) mRNA transcription of prostaglandin synthases and their products in the equine endometrium in the course of fibrosis. *Theriogenology* 78: 768-776.
- Troedsson MH (1999) Uterine clearance and resistance to persistent endometritis in the mare. *Theriogenology* 52: 461-471.
- Walter I, Handler J, Reifinger M, Aurich C (2001) Association of endometriosis in horses with differentiation of periglandular myofibroblasts and changes of extracellular matrix proteins. *Reproduction* 121: 581-586.
- Woodward EM, Christoffersen M, Campos J, Squires EL, Troedsson MH (2012) Susceptibility to persistent breeding-induced endometritis in the mare: relationship to endometrial biopsy score and age, and variations between seasons. *Theriogenology* 78: 495-501.
- Zajac S, Katkiewicz M, Witkowski M, Boryczko Z, Pawlak M (2008) Endometrosis in mares. *Med Weter* 64: 257-261.
- Zhang Z, Kundu GC, Zheng F, Yuan CJ, Lee E, Westphal H, Ward J, Demayo F, Mukherjee AB (2000) Insight into the physiological function(s) of uteroglobin by gene-knockout and antisense-transgenic approaches. *Ann N Y Acad Sci* 923: 210-233.