

DOI 10.1515/pjvs-2015-0084

Short communication

Expression of Cyclooxygenase-2 in naturally occurring bovine cutaneous fibropapillomas

F. Bocaneti^{1*}, G. Altamura^{2*}, A. Corteggio², C. Solcan¹, E. Velescu¹
G. Borzacchiello²

¹ Department of Public health, Faculty of Veterinary Medicine,
University of Agriculture Sciences and Veterinary Medicine, Ion Ionescu de la Brad, Iasi, Romania

² Department of Veterinary Medicine and Animal Productions,
University of Naples Federico II, Via F. Delpino, 1 80137 Napoli, Italy

Abstract

Bovine cutaneous fibropapillomas are benign skin tumours characterized by epithelial and dermal proliferation and induced by Bovine papillomaviruses (BPVs). Cyclooxygenase (COX) 1 and 2 are enzymes involved in pathological conditions, such as inflammation and epithelial carcinogenesis. Here we investigated biochemically and immunohistochemically COX-2 expression in bovine cutaneous fibropapillomas. Eight of twelve fibropapillomas (67%) showed COX-2 positive immunosignal mostly in the cytoplasm of the basal cell layer, while the normal skin did not stain. Biochemical analysis confirmed the expression of COX-2 in tumour samples. This study shows COX-2 expression in cutaneous fibropapillomas, suggesting a contribution in epithelial tumour development.

Key words: Bovine papillomavirus, COX-2, fibropapillomas

Introduction

Bovine cutaneous fibropapillomas are benign hyperproliferative tumors affecting cattle worldwide, induced by Bovine papillomaviruses (BPVs) (Nasir and Campo 2008). Cyclooxygenases (COXs) are enzymes demonstrated to exist as two distinct isoforms. The COX-1 isoform is expressed constitutively in many cells, whereas COX-2 expression is generally undetectable in most healthy adult epithelial tissues, but can be highly induced by multiple mitogenic and inflammatory stimuli (Dore 2011). Recent studies dem-

onstrated COX-2 expression in a variety of animal tumors (Beam et al. 2003, Borzacchiello et al. 2004, Thamm et al. 2008). Moreover, COX-2 overexpression has been demonstrated in both human and animal papillomavirus induced tumours (Borzacchiello et al. 2003, Balan et al. 2011).

The purpose of this study was to investigate COX-2 expression in spontaneous bovine cutaneous fibropapillomas.

Correspondence to: G. Borzacchiello, e-mail: borzacch@unina.it, tel.: 00 39 081 253 64 67

* These two authors contributed equally to this work

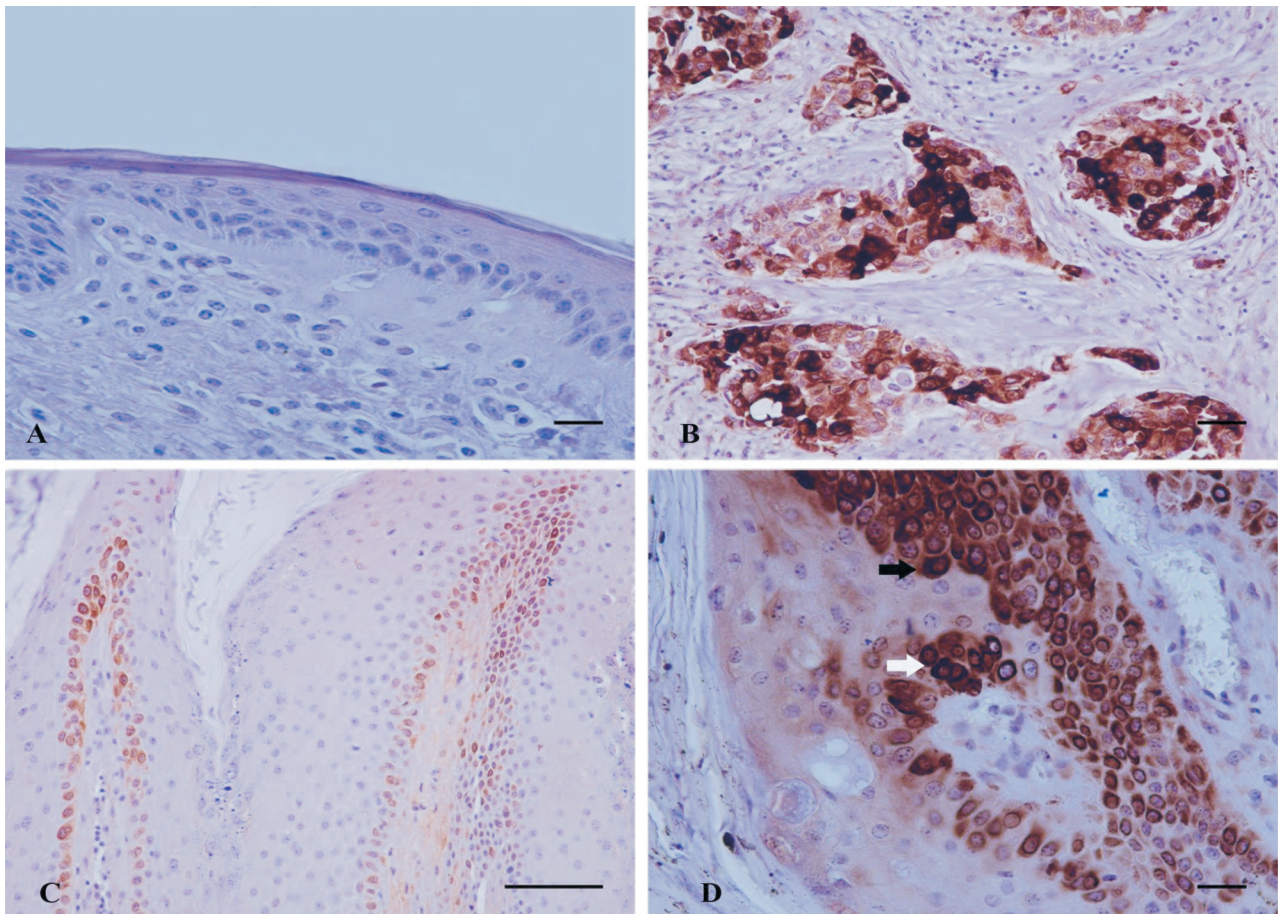


Fig. 1. COX-2 expression in bovine normal skin and cutaneous fibropapillomas. (A) Bovine normal skin. Epithelial cells are negative for COX-2 expression. (B) Human breast cancer. Neoplastic cells show a strong intracytoplasmic immunoreactivity. (C) COX-2 staining is present throughout the basal cell layer of bovine fibropapillomas. (D) Strong cytoplasmic (black arrowhead) and perinuclear (white arrowhead) COX-2 immunosignal. Streptavidin-biotin-peroxidase technique, Mayer's hematoxylin counterstain. Scale bar = 100 µm (C). Scale bar = 50 µm (A, B and D).

Table 1. COX-2 immunohistochemical expression in bovine normal skin and fibropapillomas.

Samples	COX-2	
	intensity	pattern
T1	+++	Cytoplasmic perinuclear
T2	++	Cytoplasmic perinuclear
T3	+++	Cytoplasmic perinuclear
T4	+++	Cytoplasmic perinuclear
T5	+++	Cytoplasmic perinuclear
T6	0	0
T7	0	0
T8	++	Cytoplasmic perinuclear
T9	+++	Cytoplasmic perinuclear
T10	0	0
T11	0	0
T12	++	Cytoplasmic perinuclear
N1	0	0
N2	0	0

Materials and Methods

Thirteen fibropapilloma samples (T1-T13) from cattle with clear clinical signs of cutaneous fibropapillomatosis were collected under local anesthesia from a dairy farm from Moldova, Romania. The animals aged 8 months to 4 years and were all Romanian Black Spotted breed. Also two samples of normal skin (N1-N2) from healthy cows were obtained at a public slaughterhouse. To investigate the specificity of the antibody, protein lysates from six fibropapillomas (T1-T5, T13) and two normal skin (N1-N2) frozen samples were analysed by Sodium dodecyl sulphate polyacrylamide gel electrophoresis (SDS-PAGE) and Western blot. An anti-COX-2 primary antibody (VP-RM02, Vector Laboratories) was used.

Further, the bovine cutaneous fibropapilloma samples (T1-T12) and normal skin samples (N1-N2) were evaluated by immunohistochemistry. Sample T13 was not available for immunohistochemical analysis. Briefly, tissue sections were stained using the same anti-COX-2 primary antibody and the streptavidin-biotin-peroxidase (LSAB kit, Dako Cytomation, Denmark) method. A positive control represented by human breast cancer was run in parallel. The scoring of the immunoreactivity was determined in a "blind" study by two observers (FB and GB). The intensity of intracellular brown labelling in each specimen was scored on a four-tiered scale of 0 to +++ as follows: 0, absent; +, weak; ++, moderate and +++, strong.

Results and Discussion

By Western blot analysis, the antibody recognized a band of the expected molecular mass in three neoplastic tissues but not in the normal skin (data not shown).

By immunohistochemistry, COX-2 immunoreactivity was not detected in normal skin samples (Fig. 1A). Eight of twelve tumour samples (67%) were COX-2 positive. The immunosignal was recorded in the cytoplasm of the basal cells layer (Fig. 1C), with increased intensity in the perinuclear area (Fig. 1D). Staining was heterogeneous throughout tumour sections. Sporadically, few cells in the superficial layer showed moderate cytoplasmic immunoreactivity. The results of COX-2 immunoreactivity are provided in Table 1. COX-2 was expressed also by the fibroblasts beneath the epithelial proliferation in six out of twelve (50%) fibropapilloma samples, showing a moderate cytoplasmic immunosignal. The positive control represented by human breast cancer showed a strong cytoplasmic staining (Fig. 1B).

Our results show that COX-2 is expressed in bovine cutaneous fibropapillomas.

Interestingly, it has been reported that COX-2 is overexpressed in equine, feline and canine epithelial tumours (Borzacchiello et al. 2004, Bardagi et al. 2012), indicating that COX-2 is involved in animal tumour development. Furthermore, COX-2 is overexpressed in spontaneous bovine and equine tumours caused by BPV infection (Borzacchiello et al. 2003, Thamm et al. 2008), suggesting that COX-2 expression is a common finding in BPV-induced tumours. Here, we show a cytoplasmic localization of COX-2 in the basal cell layer. Similar findings were also reported in other studies conducted on epithelial tumors with different etiology in animal species, where COX-2 cytoplasmic expression may be important for its function in tumour development independently of the cause of cancerogenesis (Beam et al. 2003, Borzacchiello et al. 2004, Kleiter et al. 2004). The COX-2 perinuclear pattern frequently observed in some of our tumour samples has been also observed in some human and canine cancers (Ristimaki et al. 2001, Borzacchiello et al. 2004) and may be related to COX-2 subcellular distribution (Morita et al. 1995).

Additionally, COX-2 is overexpressed in Human Papillomavirus (HPV) induced cervical carcinomas, denoting a possible interplay between the PVs and COX-2 expression (Balan et al. 2011). Finally, this study shows for the first time, to the best of the authors' knowledge, that COX-2 is expressed in cutaneous fibropapillomas, suggesting a contribution of this enzyme to epithelial tumour development. However, the precise role of COX-2 expression in the development of bovine cutaneous tumours induced by BPVs needs further investigations.

Acknowledgements

The authors wish to express their gratitude to Dr. Carlo della Ragione (AORN – A. Cardarelli – Napoli) for having provided positive control for immunohistochemistry and to Dr. Valeria Marina Monetti (Department of Pharmacy – University of Naples Federico II) for her technical help. Part of this work was supported from the Project "PROIECTE DE CERCETARE – sesiunea 2013, University of Agriculture Sciences and Veterinary Medicine, Ion Ionescu de la Brad, Iasi".

References

- Balan R, Amalinei C, Giusca SE, Ditescu D, Gheorghita V, Crauciuc E, Caruntu ID (2011) Immunohistochemical

- evaluation of COX-2 expression in HPV-positive cervical squamous intraepithelial lesions. *Rom J Morphol Embryol* 52: 39-43.
- Bardagi M, Fondevila D, Ferrer L (2012) Immunohistochemical detection of COX-2 in feline and canine actinic keratoses and cutaneous squamous cell carcinoma. *J Comp Pathol* 146: 11-17.
- Beam SL, Rassnick KM, Moore AS, McDonough SP (2003) An immunohistochemical study of cyclooxygenase-2 expression in various feline neoplasms. *Vet Pathol* 40: 496-500.
- Borzacchiello G, Ambrosio V, Galati P, Perillo A, Roperto F (2003) Cyclooxygenase-1 and -2 expression in urothelial carcinomas of the urinary bladder in cows. *Vet Pathol* 40: 455-459.
- Borzacchiello G, Paciello O, Papparella S (2004) Expression of cyclooxygenase-1 and -2 in canine nasal carcinomas. *J Comp Pathol* 131: 70-76.
- Dore M (2011) Cyclooxygenase-2 expression in animal cancers. *Vet Pathol* 48: 254-265.
- Kleiter M, Malarkey DE, Ruslander DE, Thrall DE (2004) Expression of cyclooxygenase-2 in canine epithelial nasal tumors. *Vet Radiol Ultrasound* 45: 255-260.
- Morita I, Schindler M, Regier MK, Otto JC, Hori T, DeWitt DL, Smith WL (1995) Different intracellular locations for prostaglandin endoperoxide H synthase-1 and -2. *J Biol Chem* 270: 10902-10908.
- Nasir L, Campo MS (2008) Bovine papillomaviruses: their role in the aetiology of cutaneous tumours of bovids and equids. *Vet Dermatol* 19: 243-254.
- Ristimaki A, Nieminen O, Saukkonen K, Hotakainen K, Nordling S, Haglund C (2001) Expression of cyclooxygenase-2 in human transitional cell carcinoma of the urinary bladder. *Am J Pathol* 158: 849-853.
- Thamm DH, Ehrhart EJ 3rd, Charles JB, Elce YA (2008) Cyclooxygenase-2 expression in equine tumors. *Vet Pathol* 45: 825-828.